VII. *The Monotreme Skull: A Contribution to Mammalian Morphogenesis.*

By D. M. S. WATSON, *M.Sc., Lecturer in Vertebrate Palæontology, University College, University of London.*

Communicated by Prof. J. T. WILSON, *F.R.S.*

(Received June 11,—Read June 17, 1915.)

[PLATES 23–25.]

I. INTRODUCTORY.

From the time, now nearly a century ago, when DE BLAINVILLE, applying the philosophical methods he had developed for the classification of mammals to the knowledge of the structure of Echidna and Ornithorhynchus which had been obtained by LAMARCK, GEOFFROY ST. HILAIRE, and G. CUVIER, suggested that these two animals should perhaps form a group of the same order as the Marsupials and "Monodelphes," many authors have studied their structure and discussed their affinities.

Nearly all the great anatomists of the last century have at one time or another described the skull of a monotreme, either formally or in some text-book or other general work. Owing to the extreme difficulty of obtaining skulls which show sutures, their accounts vary to a very great extent. Finally, in 1901, Prof. VAN BEMMELEN published a lengthy and magnificently illustrated account of the skulls of both monotremes which had every appearance of being a definitive description. Some years ago, when describing the skull of the "Cynodont" Diademodon, I endeavoured to institute a comparison between that animal, which in all ways makes an extremely close approach to mammalian structure, and the monotremes, admittedly the most reptilian of all mammals. To my very great surprise I found it impossible to compare the skull of Ornithorhynchus as interpreted by VAN BEMMELEN with Diademodon. As at that time I had not sufficient material satisfactorily to undertake an independent investigation of the monotreme skull, I compared Diademodon with Dasyurus, a comparison which involves no difficulty.

During comparatively recent years three authors have been so fortunate as to obtain embryo monotremes, on the skull of which they have worked.

In 1894 W. N. PARKER discussed some features in the skull of two pouch-young of Echidna.

In 1901 J. T. WILSON described wax-plate models of the skeleton of the snout of the mammary fœtus of both monotremes, and subsequently, in 1906, gave a very brief description of a plate model of the posterior part of the skull and lower jaw of a small mammary fœtus of Ornithorhynchus.

By far the most important piece of work on the embryonic skull of a monotreme is E. GAUPP'S masterly account of the development of the skull of Echidna and the

[Published, March 10, 1916.

great series of papers, discussing from a general standpoint special regions of the vertebrate skull, in which his model of the Echidna chondrocranium is further figured and discussed.

During a visit to Sydney, in connection with the Australian Meeting of the British Association, Prof. WILSON showed me his sections and models of the skull of fœtal monotremes, and with extreme generosity suggested that I should publish an account of them. Prof. WILSON has done a great deal of work on this material, and his notes and sketches are essentially incorporated in the following account.

II. MATERIAL.

The material consists of:—

Specimen δ of Ornithorhynchus.—(The whole fœtus was described and figured by J. T. WILSON, 'Proc. Linn. Soc. N.S.W.,' series 2, vol. 9, p. 682). This specimen was 80 mm. from tip of snout to tip of tail round the dorsal curve.

The specimen was cut in two by a parasagittal cut, and a complete series of coronal sections of each piece prepared. The right portion including the middle line is represented by a series of thick (50 μ) sections, and the whole has been re-constructed in wax-plate models, the snout by J. T. WILSON (fig. 'Proc. Linn. Soc. N.S.W.,' 1901, pt. 4, p. 717) and the rest of the skull, with the exception of the hyoid apparatus and the extreme occipital region, by Mr. W. T. QUAIFE under Prof. WILSON'S supervision.

This model, magnified 80 diameters, has now collapsed to a considerable extent in consequence of the heat of the Sydney summer, but owing to the existence of numerous photographs, many of which are stereoscopic, this distortion has not interfered with my use of it.

Specimen β, Ornithorhynchus, measured 250 mm. from tip of snout to tip of tail along the dorsal curvature.

The head of this specimen, which is excellently preserved, was divided into two by a cut to the right of the middle line and the left side imbedded in collodion and decalcified by nitric acid. The other side was decalcified and cut in paraffin. The major set of sections is complete, with the exception that immediately in advance of the ala temporalis a short region is only represented by imperfect specimens.

A mammary fœtus of Echidna, considerably smaller than β of Ornithorhynchus but larger than any of Prof. GAUPP'S. This specimen is represented by a nearly perfect series of sections of rather more than one half of the skull.

Subsequently Mr. R. ETHERIDGE, the Director of the Australian Museum, Sydney, was so good as to lend me four skulls of young Echidnas belonging to the Museum which show with perfect clearness the whole structure of the skull and have proved invaluable for comparison. And, finally, I have used two incomplete skulls of large pouch-young of Echidna with a head length of about 40 mm., which had been opened so as to allow of the removal of the brain. These have already been described by Prof. WILSON, so far as concerns the tænia clino-orbitalis.

III. THE YOUNGER FŒTUS OF ORNITHORHYNCHUS (Specimen δ).

The skull of this individual agrees so closely in its general features with the skull of Echidna, Stage 51A, described and figured by GAUPP, as to relieve me of the necessity of any very detailed description.

I shall adopt Prof. GAUPP'S nomenclature throughout this paper, sometimes in a translated form.

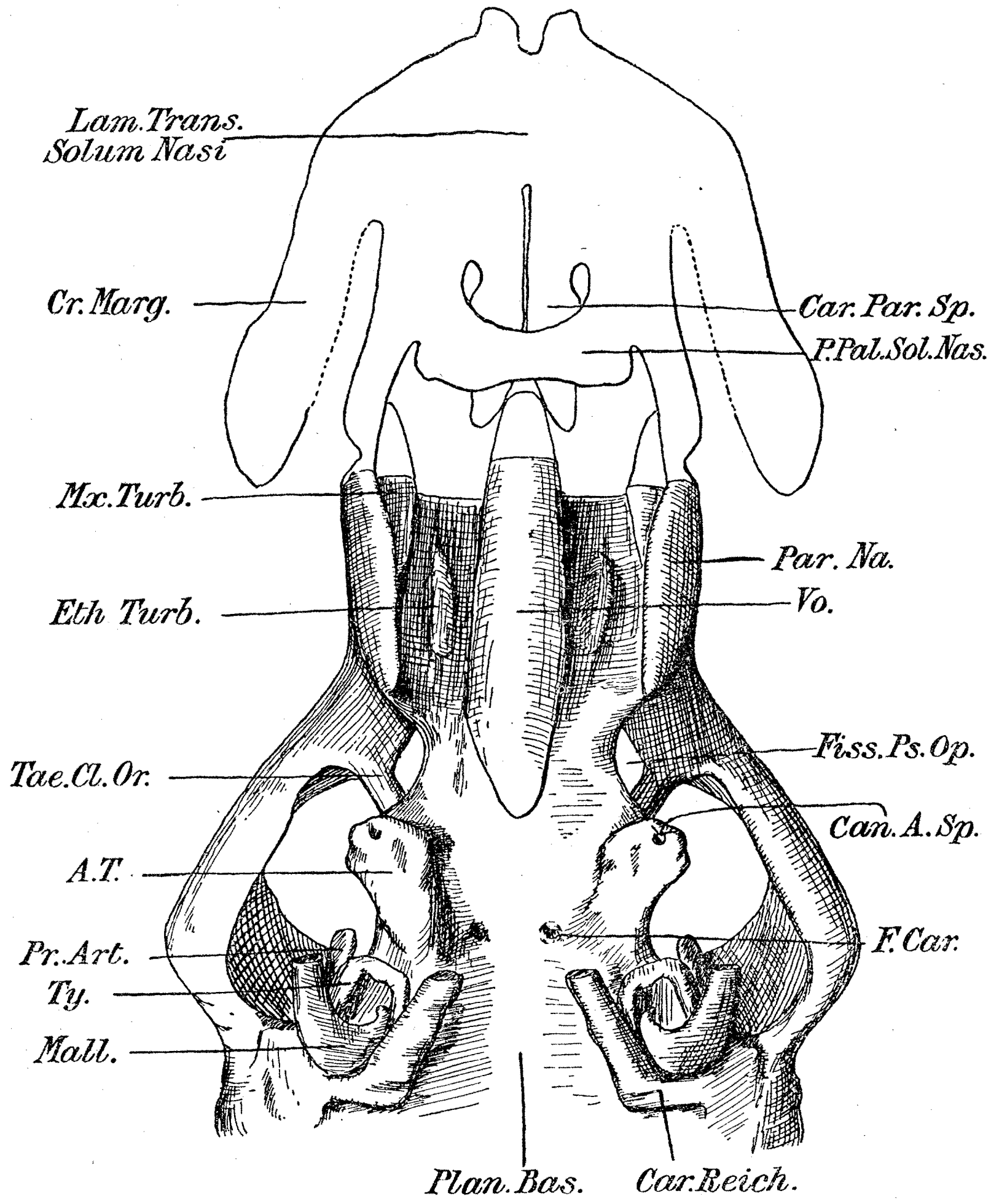

FIG. 1.—*Ornithorhynchus paradoxus.* Embryo δ. J. T. WILSON Coll. Ventral aspect of a model of the chondrocranium on a scale of 80 diameters. The left side, not represented in the model, is transposed from the right, and the snout in outline is added from Prof. WILSON'S previously described model. Scale $\frac{2}{21}$ of the model = about 8 dia. of original. *A.T.*, ala temporalis; *Can.A.Sp.*, canal in ala temporalis; *Car.Par.Sp.*, paraseptal cartilage; *Car.Reich.*, Reichert's cartilage; *Cr.Marg.*, crista marginalis of the solum nasi; *Eth.Turb.*, ethmoturbinal; *F.Car.*, carotid foramen; *Fiss.Ps.Op.*, fissura pseudo-optica; *Lam.Trans. Solum Nasi*, transverse lamina of the solum nasi; *Mall.*, malleus; *Mx.Turb.*, maxilloturbinal; *P.Pal.Sol.Na.*, palatine process of the solum nasi; *Par.Na.*, paries nasi; *Pr.Art.*, prearticular (GONIALE, GAUPP); *Plan.Bas.*, planum basale; *Tæ.Cl.Or.*, tænia clino-orbitalis; *Ty.*, tympanic; *Vo.*, vomer.

(a) *Regio occipitalis.*

The series of sections does not show the posterior end of the planum basale. As seen it is a thick plate of cartilage of nearly uniform breadth, not perforated by the notochord, which has disappeared, and with no ossification. Laterally it passes into the pars lateralis, regio occipitalis, and into the otic capsule in front, and it is directly continuous with the broad basal cartilage of the orbitotemporal region. The region in which the basal plate passes into the lateral wall of the occipital region is shown by the rather small foramen jugulare.

The occipital region is only incompletely shown, and the lateral walls pass without any demarcation into the planum basale, and are connected together dorsally by the tectum posterius, which presents no features of interest.

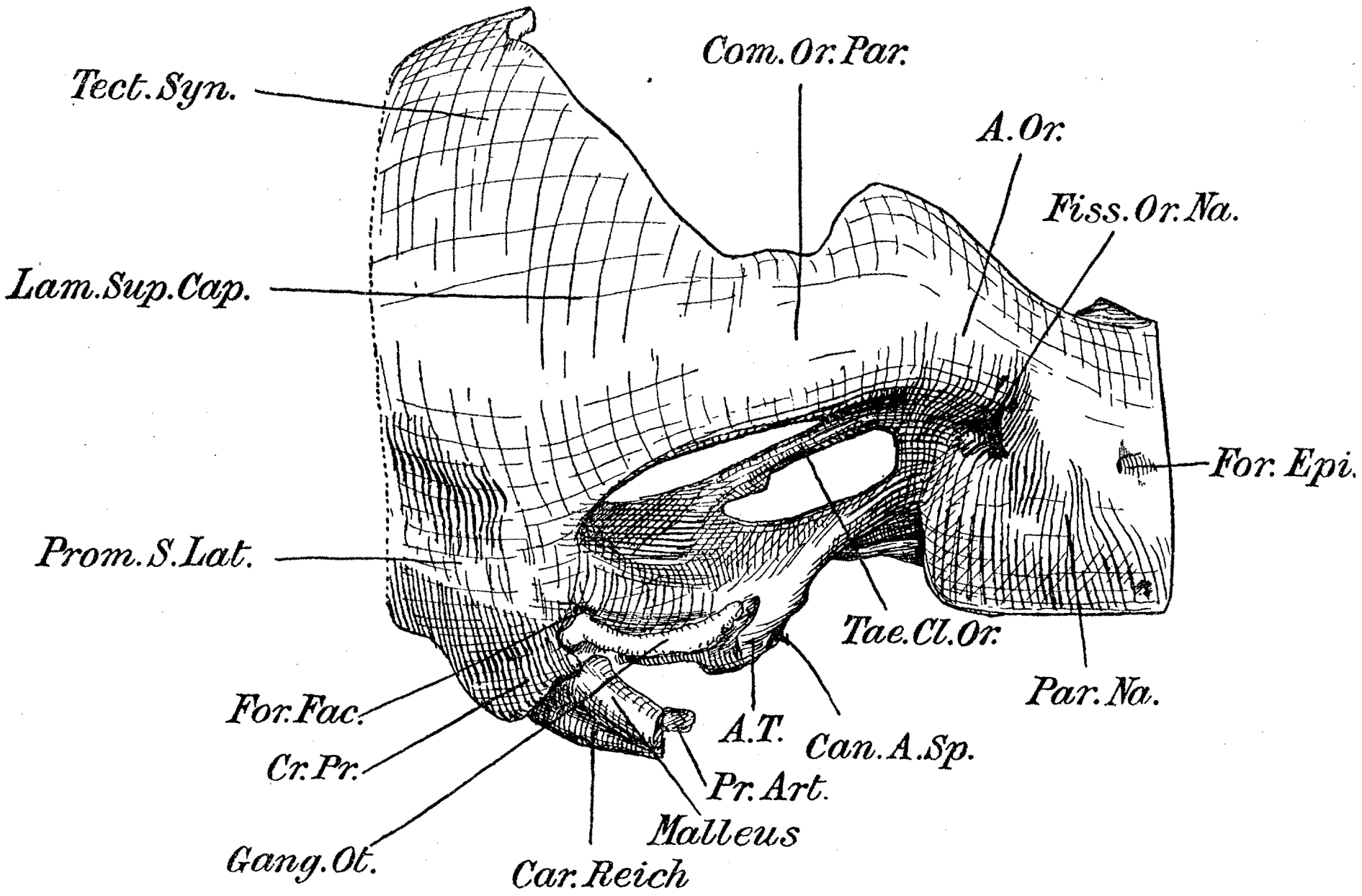

FIG. 2.—The same model as fig. 1. Right lateral aspect. Reference letters as before, with—*A.Or.*, ala orbitalis; *Cr.Pr.*, crista parotica; *Com.Or.Par.*, commissura orbito-parietalis; *Fiss.Or.Na.*, fissura orbito-nasalis; *For.Epi.*, foramen epipanale; *For.Fac.*, foramen facialis; *Gang.Ot.*, ganglion oticum with great superficial petrosal running through it; *Lam.Sup.Cap.*, lamina supracapsularis; *Tect.Syn.*, tectum synoticum.

(b) *Regio otica.*

The auditory capsules are completely and indistinguishably fused with the planum basale, the pars lateralis regio occipitalis, and the lamina supracapsularis, the latter being in some degree marked off by the presence of a prominence on the inner surface over the anterior vertical semicircular canal. In this stage the otic capsule lies very largely in the side wall of the skull, its inner surface forming a distinct angle with the dorsal surface of the planum basale.

The inner surface of the ear region is perforated by the internal auditory meatus, which is at this stage of considerable size. It lies slightly above and in front of the foramen jugulare, and is an irregularly four-sided opening. Its anterior corner transmits the seventh nerve, which, immediately after entering it, passes into the aqueductus Fallopii, which passes straight through the cartilage and opens on the outer side.

The posterior border of the inner opening of the D. fallopii is separated from the general cavity for the inner ear by a special upstanding process. Dorsal and caudal of the internal auditory meatus is a distinct though small and not very deep fossa subarcuata, which is limited above by a distinct prominence over the anterior vertical semicircular canal. Immediately behind the fossa subarcuata is a distinct prominence over the joint portion of the vertical semicircular canals; on this, just ventral to the fossa floccularis, is the opening of the ductus endolymphaticus. The anterior border of the otic cartilage lies immediately in front of the aqueductus fallopii and forms a gentle concave curve passing into the cochlear part of the capsule and the ala temporalis below, and the broad commissura orbito-parietalis above. There is no distinction of this margin into commissura prefacialis and limbus præcapsularis such as GAUPP found in Echidna. As, however, I find that this distinction is obliterated in later embryos of Echidna it is not improbable that it may have occurred in younger specimens of Ornithorhynchus.

The external surface of the otic capsule is pierced by a large nearly circular fenestra vestibuli, which lies immediately opposite the internal auditory meatus, and by the outer opening of the facial foramen, which is situated anteriorly and dorsally to the fenestra vestibuli. The fenestra cochleæ (rotunda) is a small foramen opening backwards into the extreme outer end of the foramen jugulare.

Immediately above the fenestra vestibuli is the short but powerful crista parotica, separated from the outer wall of the vestibular portion of the otic capsule by a deep but narrow sulcus facialis, which is of nearly uniform breadth and depth.

The posterior end of crista parotica is in direct cartilaginous connection with Reichert's cartilage, and about 100 μ behind its anterior end the incus has a quite definite connection by synchondrosis with it. The extremely small size of the processus perioticus superior is very noticeable. Above the crista parotica the outer surface of the capsule is nearly flat for some distance, but the position of the horizontal semicircular canal is shown by a sudden depression of the surface dorsal to it.

The cochlear part of the capsule forms a rounded swelling which lies laterally to the planum basale and stretches forward to the region of the ala temporalis.

The cavity of the otic capsule is of comparatively simple form.

The cavum vestibuli is of somewhat small size, and considerably longer than high or wide. Anteriorly its roof is incomplete, because the very large fossæ for the ampullæ of the anterior and lateral semicircular canals open into it by one very large joint foramen. Posteriorly it is drawn out into a distinct narrow process, into the roof of which the fossa for the ampulla of the posterior semicircular canal opens at its extreme posterior end, whilst the hinder end of the lateral semicircular canal opens into it just below its termination.

On the inner side the foramen ductus endolymphaticus opens into the cavum ventriculi by a slit lying just posterior to the hinder margin of the large internal auditory meatus.

The cavum sacculi is a small, nearly spherical, chamber, not very markedly separated from the cavum vestibuli, with which it is in wide communication dorsally. Anteriorly it leads into the wide lumen of the cavum cochleæ, and on the outer side its wall is pierced by the large fenestra vestibuli. Posteriorly and medially it passes into the short canal of the fenestra rotunda. The cavum cochleæ is a short and rather wide tube, directed anteriorly and somewhat medially, and bent upwards through about a quadrant of a circle.

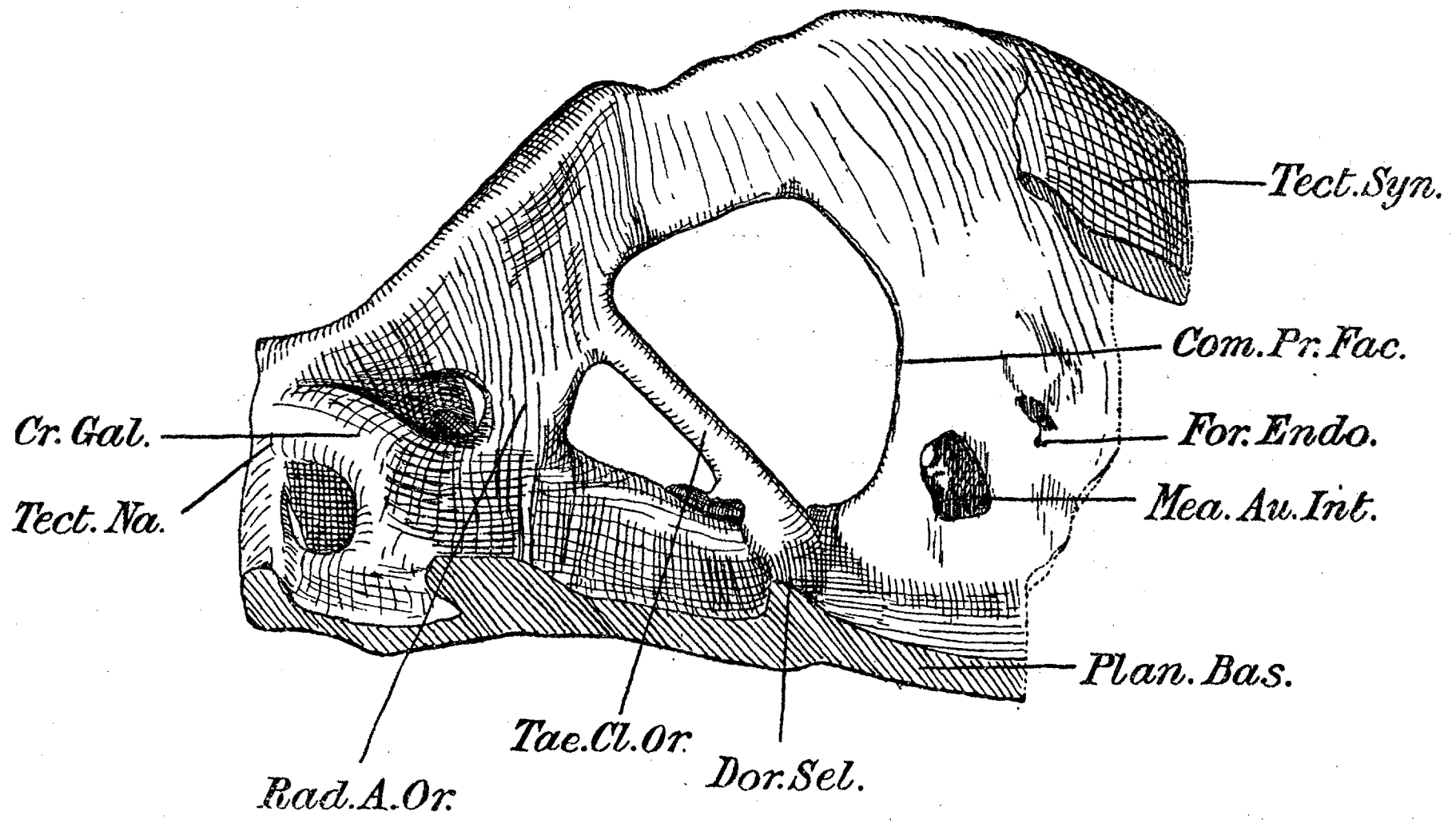

FIG. 3.—The same model, right side, viewed from within and above. Reference letters as before, with—*Com.Pr.Fac.*, commissura prefacialis; *Cr.Gal.*, crista galli; *Dor.Sel.*, dorsum sellæ; *For.Endo.*, foramen endolymphaticum; *Mea.Au.Int.*, internal auditory meatus; *Rad.A.Or.*, root of the ala orbitalis; *Tect.Na.*, tectum nasi.

The cavity of the otic capsule of the embryo of Ornithorhynchus resembles in many respects that of GAUPP'S Echidna, but differs in the considerably smaller size of the internal auditory meatus, a feature depending merely on age; in the backward process of the cavum ventriculi, and in the more medial position of the fenestra cochleæ. Its chief interest lies in its extraordinary resemblance to that of the adult of the Cynodont Diademodon. The only differences between these two types are :—

1. In the Cynodont the seventh nerve, although it leaves the skull in very close relationship to the internal auditory meatus, does not actually pass through that opening.

2. The foramen jugulare of Diademodon leaves the skull through the internal auditory meatus, the distinct and powerful ridge which separates it from the

internal ear not reaching the general level of the internal surface of the cranium, and not bridging the fenestra cochleæ, which is hence represented in the bony skull by a notch, and not a foramen.

3. The cavum sacculi is somewhat less clearly marked off in the bony Cynodont than in the cartilaginous monotreme skull.

In all other features, such as the peculiar backward prolongation of the cavum ventriculi, the opening of the fenestra cochleæ into the foramen jugulare, the form and position of the cavum cochleæ, and the relation of the ductus fallopii to the region of the inner ear, the two types are exactly similar.

It is interesting to note that the fenestra cochleæ is very widely removed from the tympanic cavity (which is shown in the model), and that, as the animal becomes adult, it gradually passes round towards the outside of the skull. In all more advanced adult mammals it opens on the same surface as the fenestra vestibuli, immediately behind it.

Judging from a specimen of Dimetrodon which Prof. WILLISTON was so good as to give me, in the most primitive Therapsids the fenestra rotunda opens on the inner aspect of the skull at the internal opening of the foramen jugulare; in the more advanced anomodonts (*e.g.*, Dicynodon) it opens into the middle of the foramen jugulare, which in those types is converted into a long canal, whilst finally, in the very advanced Diademodon, it has a position identical with that in the small mammary fœtus of Ornithorhynchus described above.

(c) *Regio orbitotemporalis.*

The basis cranii in the orbitotemporal region consists of a thick and wide plate of cartilage continuous behind with the planum basale, laterally with the cochlear portion of the otic capsules and the alæ temporales et orbitales, and in front with the ethmoidal region of the skull. Its ventral surface is nearly flat and terminates at the lamina transversalis.

The dorsal surface is excavated rather behind the middle of its length by the sella turcica, which is overhung posteriorly by the dorsum sellæ, a prominent transverse ridge whose lateral corners are produced into the tæniæ clino-orbitales. The sella turcica is entered by the carotid foramina at its extreme posterior end. Anteriorly the sella turcica is not defined in any way, the dorsal surface of the basis cranii rising gradually and evenly to the lamina infracribrosa.

The ala temporalis is a small irregularly-shaped process projecting downwards and laterally from the side of the posterior part of the basis cranii in the orbitotemporal region. Posteriorly it is directly continuous with the cochlear part of the otic capsule, anteriorly it subsides into the lateral border of the basis cranii. The outer part of the ala temporalis is pierced by a foramen which passes from above downwards and forwards and transmits a branch of the external carotid artery.

Anteriorly the upper edge of the thick basis cranii passes into the powerful root of the ala orbitalis, which runs outwards nearly horizontally, forming behind the anterior border of the sphenoparietal fissure and in front the posterior edge of the fissura orbitonasalis. The main mass of the ala orbitalis runs outward and backwards, to be continued by the slightly narrower orbitoparietal commissure to the lamina supracapsularis. Its lower border practically at its root is in connection with the upper end of the tænia clino-orbitalis.

The tænia clino-orbitalis is a narrow and essentially straight rod of cartilage which is provided with a small anterior process just above its root.

(d) *Regio ethmoidalis.*

Only the posterior part of the ethmoidal region of the skull is represented in the model which I am at present describing; the anterior part has already been modelled and described by Prof. J. T. Wilson.

The posterior part resembles generally that of Gaupp's model of the 48 stage of the Echidna skull. The only differences are the lack of any specialised processus maxillaris posterior, and the absence of any definite lamina transversalis posterior, the ventral surface of the basis cranii sloping gradually into the nasal cavity.

There is a short but very distinct ethmoturbinal, lateral to the fenestra cribrosa, and a small maxilloturbinal, formed apparently by the infolding of the lower edge of the paries nasi.

(e) *Ossicula auditus.*

The stapes is a small conoidal cartilage showing faint traces of a basal plate at its proximal end. Its distal end is in direct connection with the incus by a narrow, somewhat imperfectly cartilaginous neck. The incus is a flattened cartilaginous nodule whose anterior dorsal corner is in direct cartilaginous connection with the anterior end of the crista parotica; on the inner side of the connection it is directly continuous with the malleus, with which cartilage the whole of its outer aspect is in close proximity. The malleus is merely the specialised posterior end of Meckel's cartilage at this stage. Posteriorly it is continuous with the incus, being flattened and broadened to cover the whole outer surface of that cartilage. From the bottom of the lamina so formed the manubrium mallei projects forwards, downwards and inwards as a rather slender process whose outer (lower) surface is inserted into the tympanic membrane.

(f) *Hyoid arch.*

Reichert's cartilage is only represented in the models by its proximal end. It is a slender rod of cartilage directly continuous with the crista parotica and running almost horizontally inwards over the facial nerve to come into contact by a special short process with the cochlear part of the auditory capsule joint medial to the fenestra vestibuli. From this point it runs downwards and then forwards.

(g) *Bones.*

In the stage under consideration there are no cartilage bones present, but all the membrane bones are already well developed.

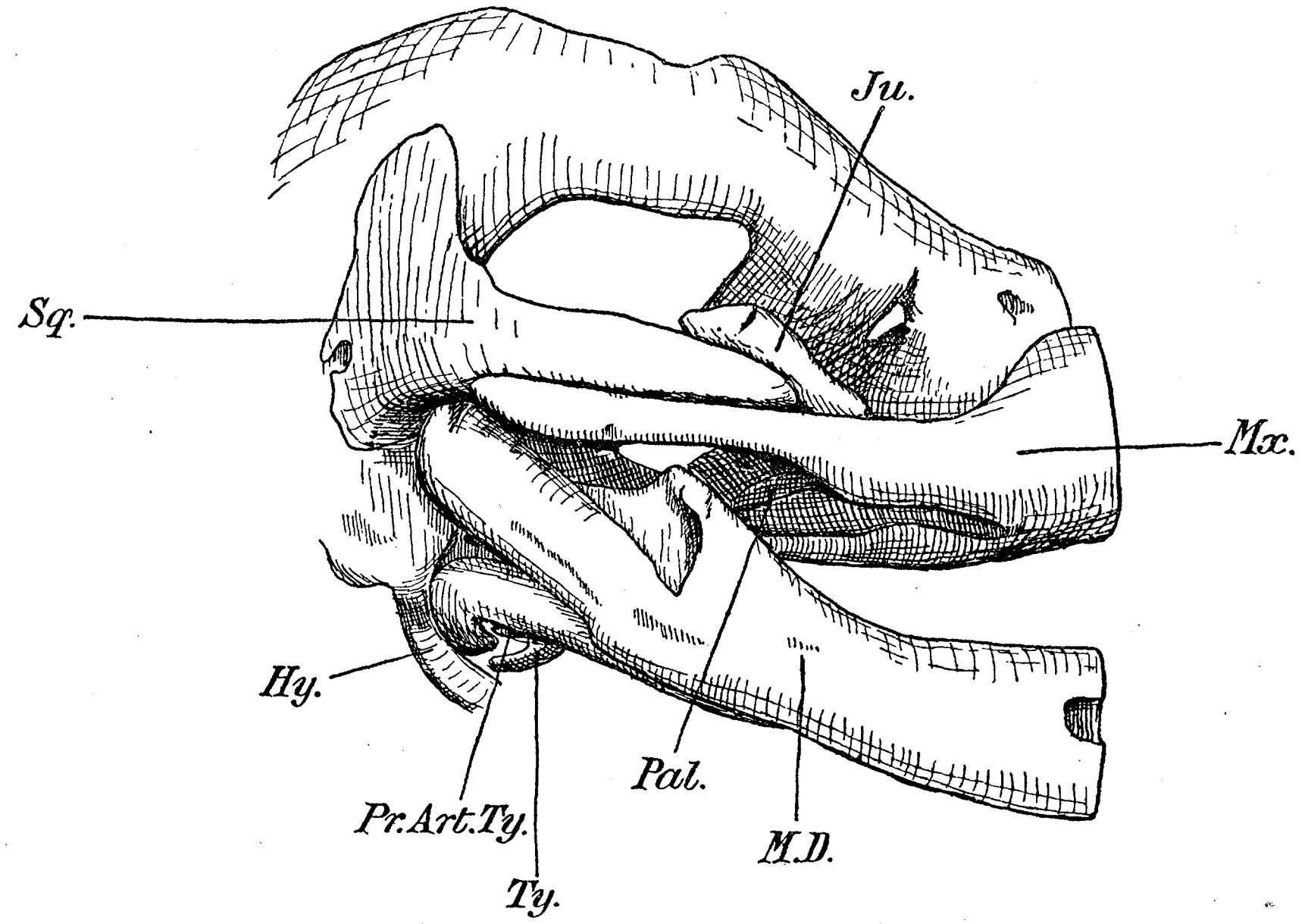

FIG. 4.—The same model with some of the membrane bones replaced. *Ju.*, jugal: *Md.*, mandible (dentary); *Mx.*, maxilla; *Pal.*, palatine; *Sq.*, squamosal.

Parietal.—The two parietals are already fused in the middle line, forming together a wide plate which covers the dorsal surface of the brain cavity from a point immediately dorsal to the posterior end of the crista parotica as far forward as the fissura orbitonasalis. The posterior end of this joint bone is deeply notched and it is pierced by one or two very small vacuities in the middle line, which throughout gives some evidence of being a recently closed suture. The anterior border is provided with three projections, the median one being very short, while the others form a pair of long lappets at the extreme edge of the bone, extending forward over the posterior ends of the frontal on to the alæ orbitales.

Frontal.—The two frontals are widely separated in the middle, and extend from the alæ orbitales, down which they send a special orbital lamina, on to the commissuræ spheno-ethmoidales as far forward as the foramen epipanale. Their anterior ends are covered by the nasals.

Squamosal.—This is a large bone in contact with the prominentia canalis semicircularis lateralis by an expansion and with the lamina supracapularis by a still larger one, the two articular faces being separated by a groove which, with the pronounced groove on the outer side of the otic capsule corresponding to the anterior vertical semicircular canal, forms the post-temporal canal of the animal, which is nearly filled by part of the temporal muscle. The massive plate formed by the bone in this region bears on its outer face and lower edge a shallow depression which is the glenoid cavity, from it the pars zygomaticus runs forward as a strong trihedral rod, the lower face of which is completely covered by the processus zygomaticus of the maxilla, whilst the inner and upper surfaces of its distal end are covered by the jugal.

Jugal.—The jugal is a small bone resting on the zygomatic arch behind the orbit, towards the border of which it contributes, being raised into a low but quite distinct postorbital process.

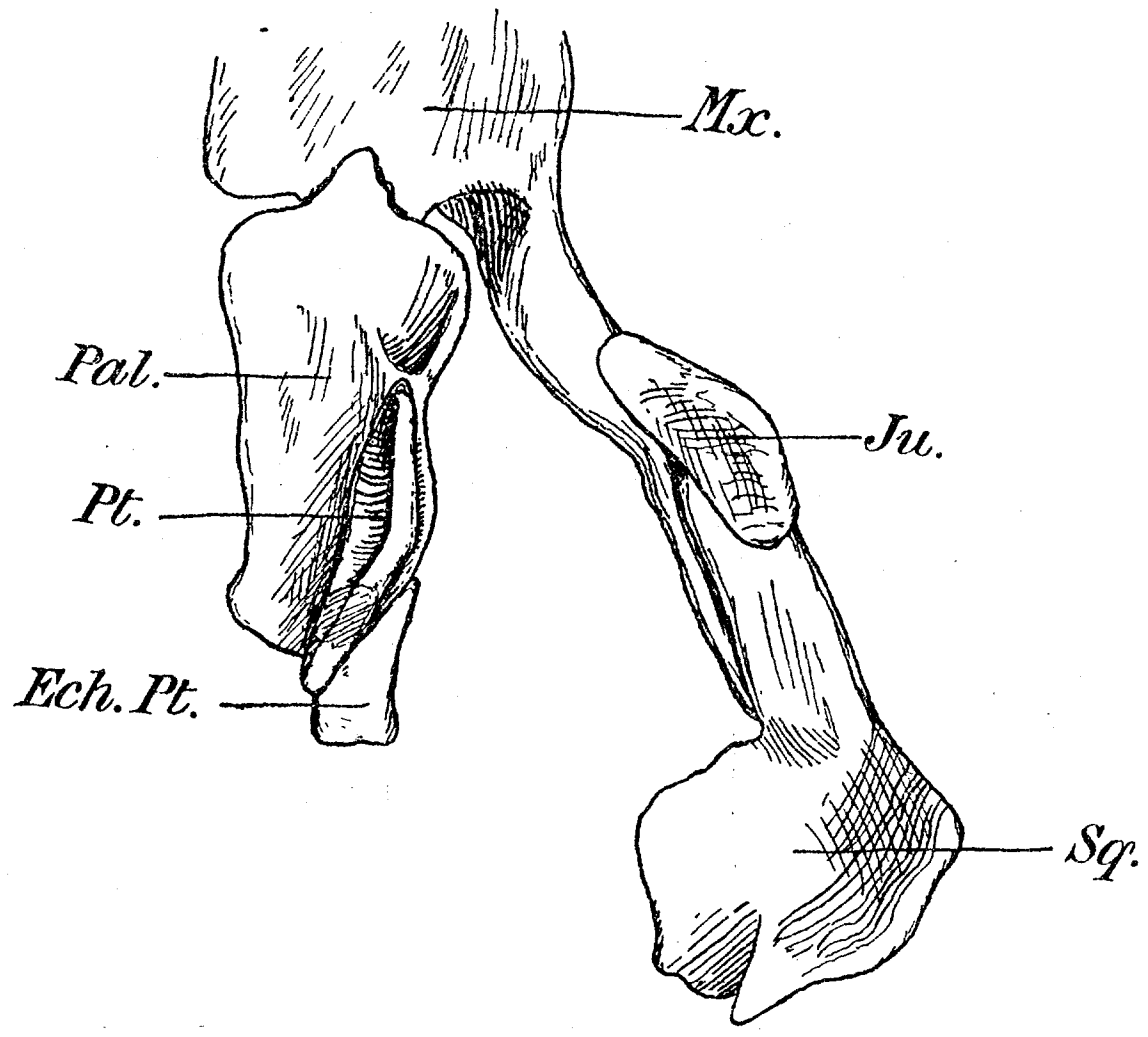

FIG. 5.—The same model, bones of the palate viewed from above. *Ech.Pt.*, "Echidna pterygoid"; *Pt.*, pterygoid, the small uniformly shaded area represents the region in which it is co-ossified with the basisphenoid.

"*Pterygoid.*"—The "pterygoid" is a small bone whose posterior end rests on the inner and lower surface of the ala temporalis, into which region a very slight extension of ossification has taken place over a very short (200 μ) region. Anteriorly the bone forms a vertical plate in the side wall of the ductus nasopharyngeus. The whole lower and part of the lateral surface of the anterior part are covered by the palatine.

The pterygoid is not pierced by a "foramen parabasale" (GAUPP) for the Nervus Vidianus.

"*Echidna Pterygoid*" (GAUPP).—The Echidna pterygoid is a small oblong bone lying in close contact with the under surface of the ala temporalis. It comes into contact with no other bone at this stage, although it closely approaches the postero-lateral corner of the palatine.

Palatine.—The palatine is a large bone lying horizontally. It consists of a flat secondary plate lying in the floor of the ductus nasopharyngeus, from which rises an orbital lamella which posteriorly covers the outer side of the anterior part of the pterygoid and anteriorly is moulded on the processus maxillaris posterior of the paries nasi. The antero-lateral portion of its ventral surface is in contact with a special process of the maxilla.

Maxilla.—The maxilla may be regarded for descriptive purposes as consisting of three parts, facial, zygomatic and palatine.

The palatine plate of the maxilla continues forward along the bony floor of the ductus nasopharyngeus in the same plane as the palatine, with which bone it is connected by a long triangular process from its postero-lateral corner. The facial part of the bone rises from the palatal and covers much of the paries nasi, rising so as nearly to touch the lower border of the frontal in the orbital region.

The zygomatic ramus is a powerful bone running back below the jugal and squamosal to the outer part of the glenoid cavity.

Vomer.—This is a median bone, clasping the lower edge of the ethmoidal septum, and extending back over the basis cranii as far as the anterior border of the ala temporalis.

The bones of the snout have been described by Prof. J. T. WILSON, *op. cit. supra*, p. 312.

Pre-articular (GONIALE, GAUPP).—The pre-articular is a small bone lying parallel to but some distance removed from the inner and upper surface of Meckel's cartilage. It is pierced by a foramen for the chorda tympani.

Tympanic.—The tympanic is a horseshoe-shaped bone lying with its inner leg in close connection with the lower border of the pre-articular.

It shows no trace of the anterior projection lying alongside Meckel's cartilage which occurs in Perameles and Dasyurus.

IV. THE OLDER FŒTUS OF ORNITHORHYNCHUS (Specimen β).

The skull of this specimen has not been reconstructed by the wax-plate method, but I have made numerous graphical reconstructions of portions of it, and some glass-plate models of the otic region.

The chondrocranium of this individual, which is probably about five months old, is considerably ossified, but agrees extremely closely in its general features with that of the younger fœtus described above. It is also nearly identical in stage, though older than the young skull figured by VAN BEMMELEN.

Regio occipitalis.

The basi-occipital is an irregularly hexagonal ossification in the planum basale, which, except for its presence, has not altered in its structure.

The exoccipital is a very complete ossification of the side wall of the regio occipitalis. It reaches upwards, very nearly to the side of the notch which forms the upper edge of the foramen magnum.

The supra-occipital is also a large ossification, which forms the front of the notch at the summit of the foramen magnum and extends forwards for some distance in the tectum posterior. The tectum posterior at this stage shows a very feebly marked process on its front margin in the middle line, presumably the processus ascendens tectum synotium of many reptiles.

Regio otica.

The auditory capsule has changed somewhat during the period, perhaps 3–4 months, separating stages δ and β. There has developed a powerful distinct prominence over the posterior semicircular canal which projects laterally to the exoccipital and above the foramen jugulare. All the prominences and depressions, particularly the prominentia canalis semicircularis anterior and the fossa subarcuata on the inner aspect of the periotic, are now much more distinctly marked.

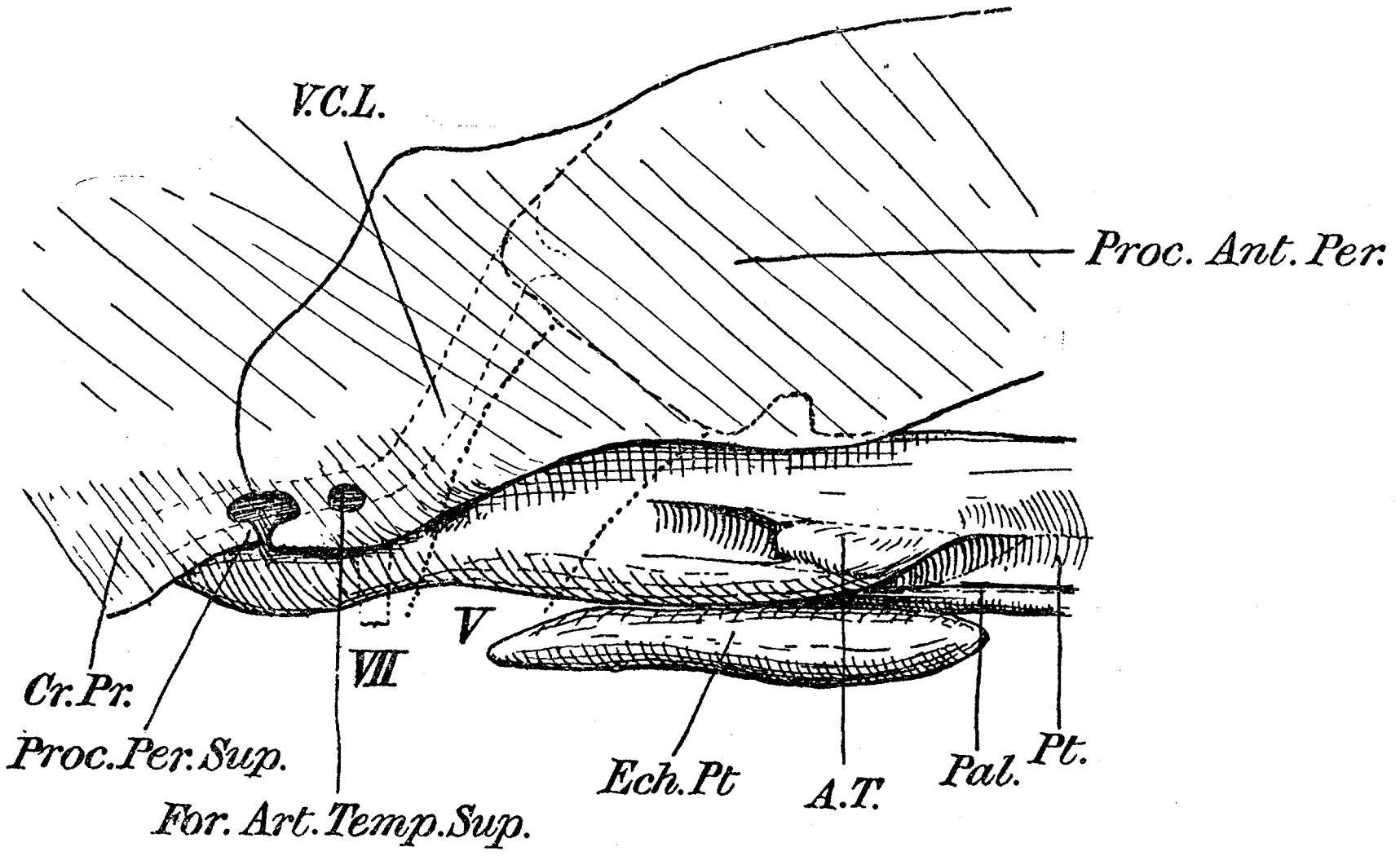

Fig. 6.—*Ornithorhynchus paradoxus.* Graphical reconstruction of the skull of Embryo β in the otic and temporal region, seen from the side. Reference letters as before, with—*For.Art.Temp.Sup.*, foramen for the superficial temporal artery: *Proc.Per.Sup.*, processus perioticus superior; *Proc.Ant.Per.*, processus anterior perioticus, the ossification in the membrana spheno-obturatoria which belongs to the prootic. The broken line lying within this bone represents the front edge of the cartilaginous otic capsule: *V.C.L.*, vena capitis lateralis, course in the sulcus facialis and the canal in the prootic; *VII*, the position of the facial foramen; *V*, the mandibular division of the fifth nerve.

By far the most interesting changes, however, are those depending on the ossification. There are two centres of ossification. The first lies ventral to that posterior part of the vestibule which runs caudally to meet the posterior ends of the horizontal and posterior vertical semicircular canals, and passes forwards from here along the ventral and inner side of the otic capsule, surrounding the fenestra cochleæ and extending a slight distance into the planum basale. This ossification extends forward under the fenestra vestibuli below the posterior portion of the cochlea. The other ossification is of a very much more complicated character. From the anterior corner of the crista parotica a new cartilaginous process, the processus perioticus superior, has grown forwards as a rod lying outside the sulcus facialis. The periotic capsule immediately above the crista parotica shows the very beginning of ossification as a thin perichondral lamella with slight traces of bone in the cartilage below it. This ossification as it is traced forward becomes much more extensive, extending right through the outer wall of the vestibular cavity at a point a little in advance of the fenestra vestibuli. In this region it is in direct connection with an ossification obviously not preformed in cartilage, which lies outside the sulcus facialis in such a manner as directly to continue the processus perioticus superior. This ossification sends back a process which very nearly meets the anterior extremity of that process, which is itself ossified. Above the two opposed processes is an oval foramen.

The ossification in the cartilaginous wall of the vestibule continues forwards, always in complete continuity with the membrane ossification, until at a point about 1 mm. behind the aqueductus fallopii the two meet so as to form a foramen, through which the vena capitis lateralis passes, and below and parallel with it a deep groove for the nervus facialis. In this region there is a foramen opening outwards from the canalis venæ capitis lateralis, through which passes the superficial temporal artery. The aqueductus fallopii is completely surrounded by the ossification in the cartilaginous otic capsule, and the membrane ossification still in complete continuity with it forms a ridge on the outer side of the opening.

The foramen venæ capitis lateralis still runs forwards.

The ridge formed by the membranous portion of this bone becomes thinner and deeper in the region, and the hinder border of the mandibular division of the fifth nerve is received in the pocket between it and the cartilaginous capsule.

Somewhat farther in advance the vena capitis lateralis turns inwards to the cranial cavity, the inner opening of the foramen being completely surrounded by bone. Study of the younger Specimen δ shows that the anterior edge of this foramen must be formed by the membranous portion of the bone, the posterior border being the incisura pro-otica of the commissura præfacialis.

The cartilaginous portion of the ossification continues forwards for a few sections along the limbus prefacialis and the anterior border of the pars cochlearis, which gives off a low process, well ossified and continued upwards and forward by a small independent nodule of cartilage.

The membranous portion of the bone runs forward in the outer wall of the brain case, still with a pronounced groove on its lower border, the outer lamina running down the outer side of the semilunar ganglion and the inner side covering a small part of its dorsal surface.

By loss of this internal ridge the bone farther forward becomes converted into a single thin plate of bone lying in the membrane closing the great sphenoparietal fissure. It runs forward in the membrane, with its upper edge in contact with the commissura orbitoparietalis and its lower edge completely free, until it finally ends freely in a pointed anterior border.

Regio orbitotemporalis.

The orbito-temporal region has not undergone any profound changes in its structure: except for a relative lengthening of its cartilaginous foundation it remains as it was.

The ala temporalis is no more prominent but has been considerably lengthened, so that the foramen piercing it is now a long horizontally directed canal entering at the side, somewhat on the dorsal surface, and running forward to open on the lower surface at the anterior end.

The basisphenoid is a large ossification. The floor of the sella turcica and the ala temporalis in its vicinity are completely ossified; farther back under the dorsum sellæ the ossification is restricted to the lower part of the thick cartilaginous basis cranii and extends out into the ala temporalis to the inner side of the foramen. The ala temporalis lateral to the foramen is still entirely cartilaginous. It is important to note that the ala temporalis at no place touches the great ossification in the membrane closing the spheno-parietal fissure.

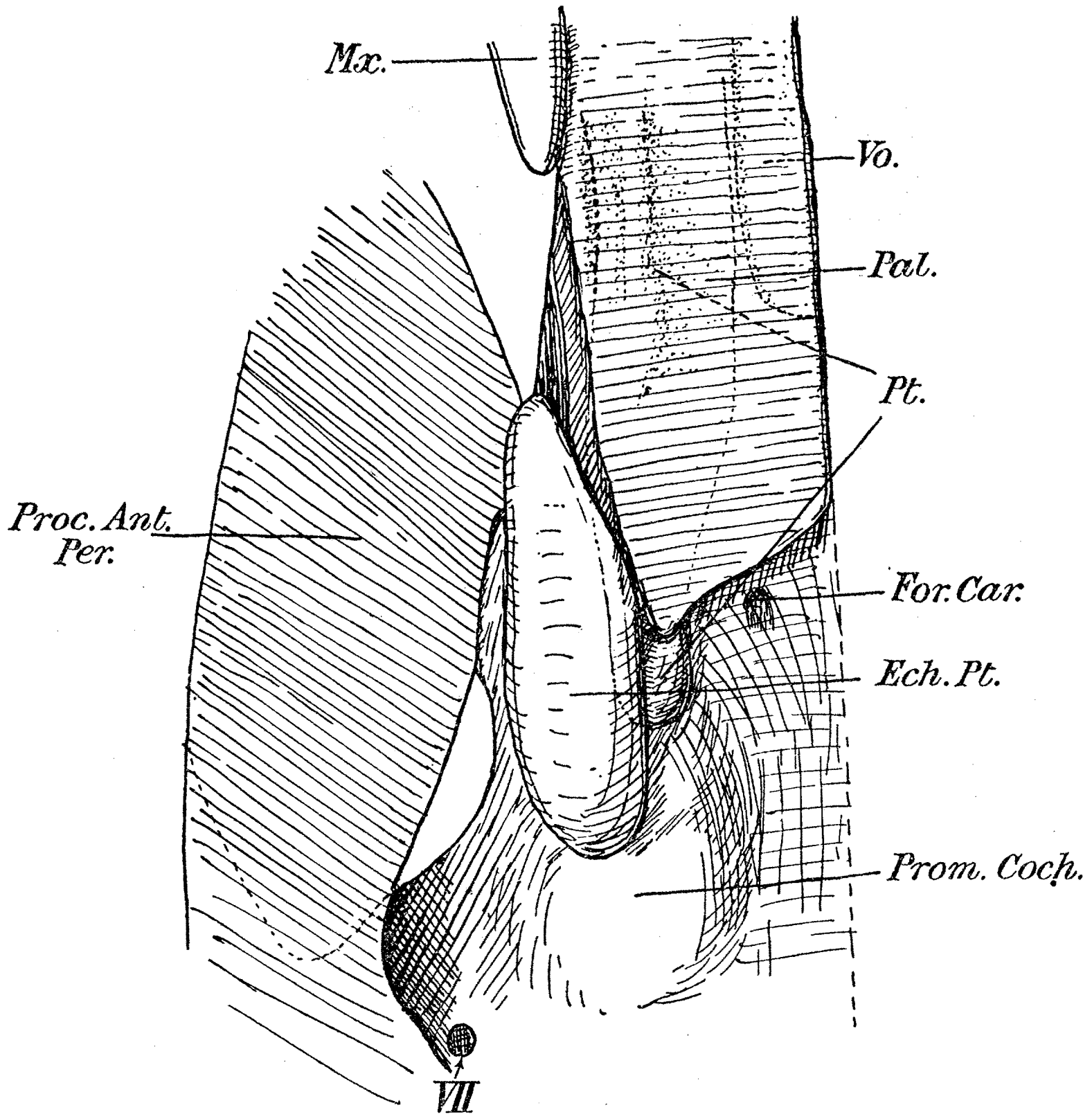

FIG. 7.—Graphical reconstruction as in fig. 6, but viewed directly from below. *Prom.Coch.*, prominentia cochleæ. The vomer and anterior part of the pterygoid are seen through the palatine.

Bones.

In the region of the ala temporalis the pterygoid is co-ossified with the basisphenoid, but becomes separated from it behind and in front. It is a long thin splint of bone ventral and medial to the ala temporalis and forming the lateral wall of the ductus nasopharyngeus. Farther forward, where it becomes free of the basisphenoid, it broadens and forms the lateral wall and most of the dorsal roof of the ductus nasopharyngeus, which is in this region paired. The lower and outer border of the bone is received in a groove in the dorsal surface of the palatine, and its upper and inner border is for a long distance in contact with the outer border of the vomer. The bone reaches forward as far as the posterior end of the paries nasi. The lower border of the extreme posterior end of the bone is in contact with the "Echidna pterygoid."

The *Echidna Pterygoid* is a large membrane bone lying ventral to the ala temporalis, with the lower surface of which its dorsal surface is in contact for some distance. In the middle of its length its upper surface just comes in contact with the lower border of the pterygoid. Farther forward its inner border is nearly in contact with the palatine. The posterior end of the bone stands out freely, being separated from the pars cochlearis of the otic capsule by the Eustachian tube.

The *palatine* is a large bone forming the posterior part of the floor of the ductus nasopharyngeus. For the greater part of its length it is fused with its fellow in the middle line, where the joint bones are thickened and articulate with the lower surface of the vomer.

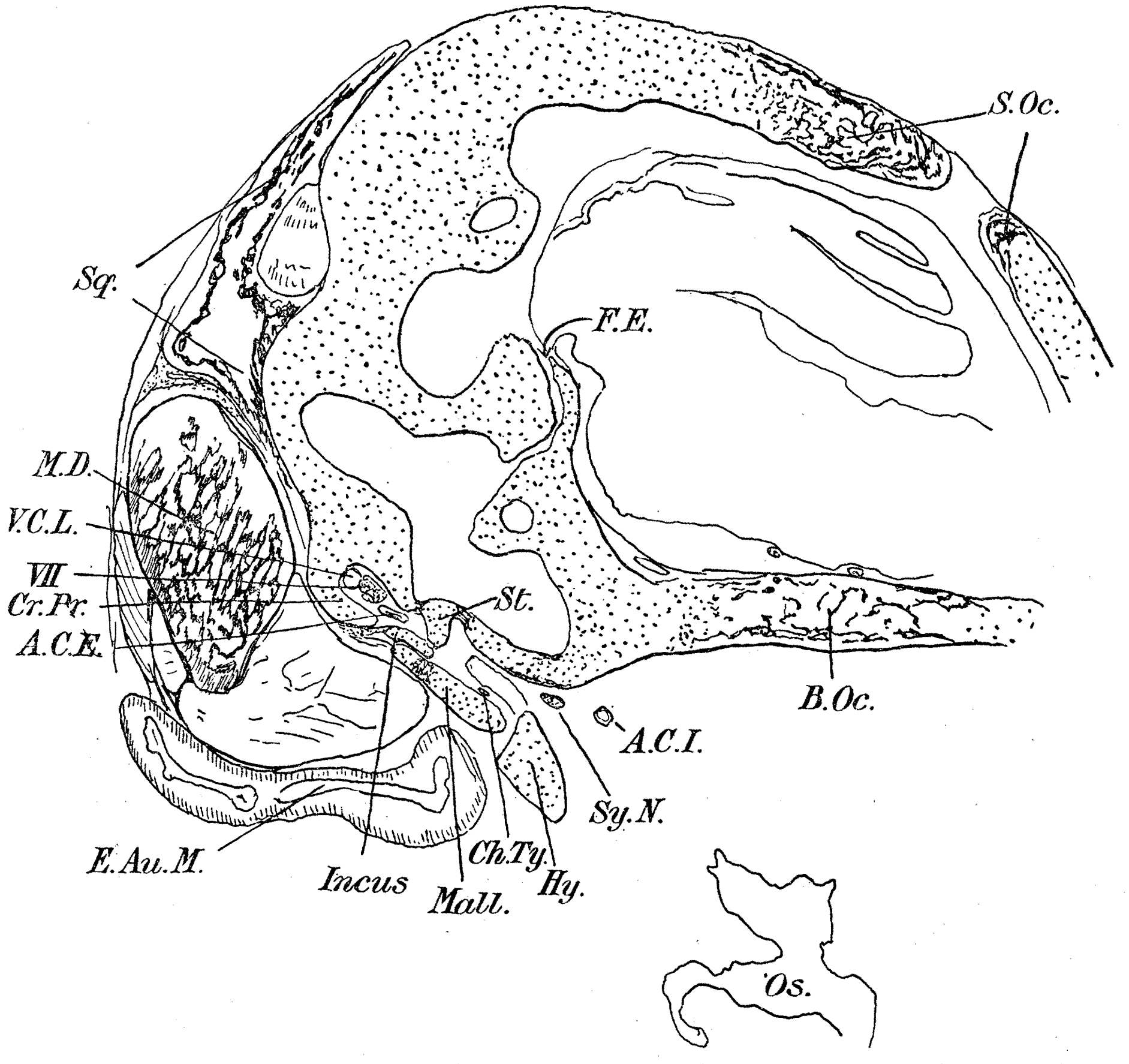

Fig. 8.—*Ornithorhynchus paradoxus.* Fœtus β of J. T. Wilson's collection. Section drawn with a Zeiss projection apparatus. × 8 dia. Section 245, slide B 26, row 1, section 2. Reference letters as before, with—*A.C.E.*, external carotid artery; *A.C.I.*, internal carotid artery; *Ch.Ty.*, chorda tympani; *E.Au.M.*, external auditory meatus; *F.E.*, foramen endolymphaticum; *Mall.*, malleus; *S.Oc.*, supra-occipital; *St.*, stapes; *Sy.N.*, sympathetic nerve; *VII*, posterior, hyomandibular branch of the facial nerve.

Posteriorly the bone articulates by its dorsal surface with the pterygoid, and in the middle of its length is provided with a groove into which the lower edge of that bone is received. Anteriorly the ridge forming the outer edge of this groove deepens and becomes a shallow orbital ramus covering some of the lower and posterior part of the paries nasi. The anterior border of this bone is fused with the maxilla, which sends a process backwards, underlying its outer margin.

The *maxilla* is a large bone agreeing in its general structure with that of the adult, but provided with a series of vacuities in which the teeth are placed.

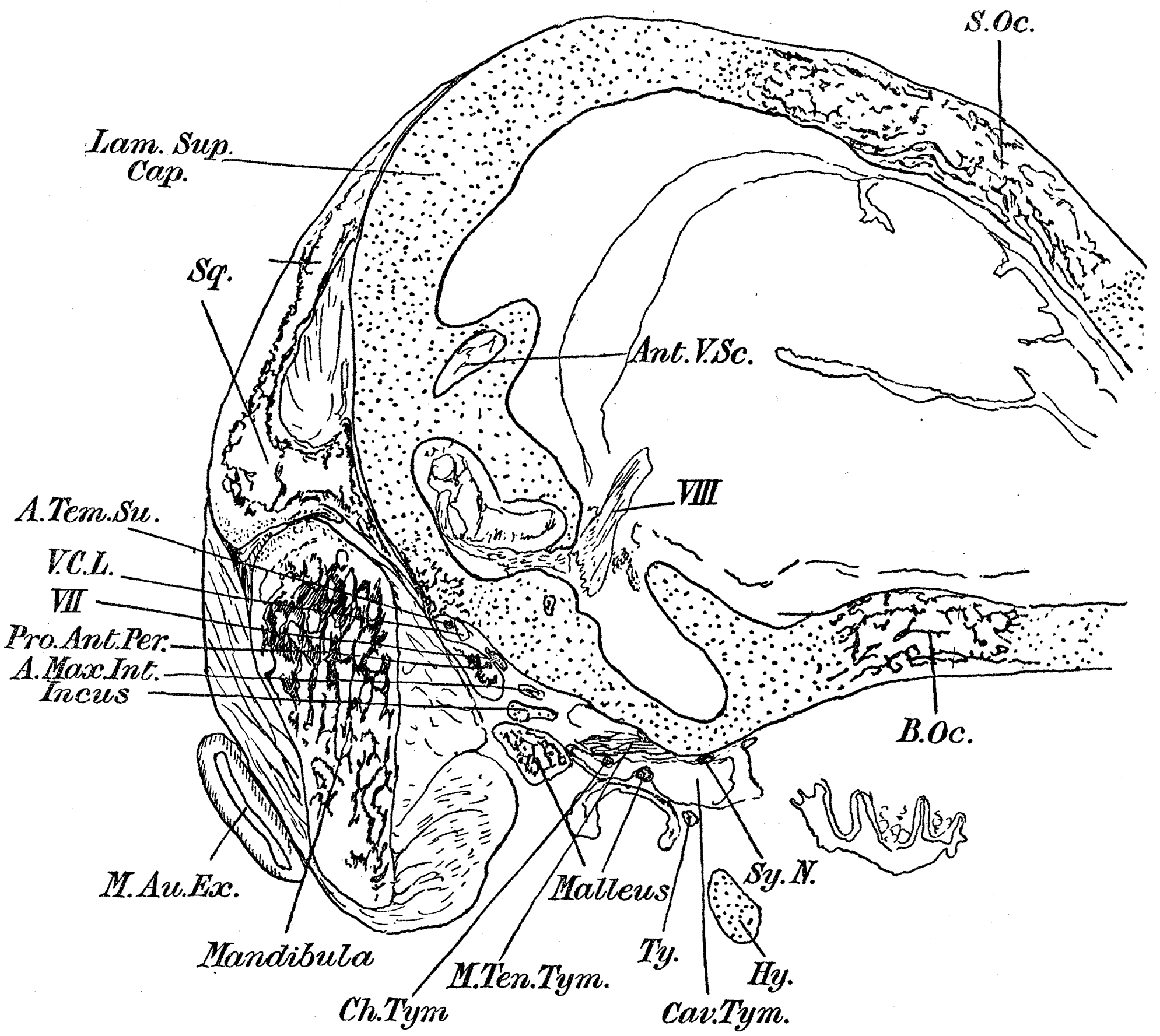

FIG. 9.—As in fig. 8. Section 209, slide B 32, row 1, sect. 3. Reference letters as before, with—*A.Tem.Su.*, superficial temporal artery: *A.Max.Int.*, internal maxillary artery; *Cav.Tym.*, cavum tympani; *Pro.Ant.Per.*, anterior process of the periotic, *i.e.* the membranous portion of the prootic; *M.Ten.Tym.*, musculus tensor tympani.

The *vomer* runs forward under the basis cranii from the posterior end of the sella turcica well into the ethmoidal region. For practically the whole of its length its dorsal surface is channelled, embracing the ridged lower surface of the basis cranii in the anterior orbito-temporal region and the nasal septum in front. Its ventral surface throughout the great part of its length is in contact with the palatine and maxilla, and its lateral border for some distance with the pterygoids.

Except for their much larger size the *parietals* agree with their condition in the younger fœtus, the peculiar trifid anterior border being still well marked.

The *frontals* are still unfused, and cover most of the paries nasi, sending down orbital plates inside the orbits to touch the maxilla, and being overlapped by the parietals and nasals.

The *squamosum* has practically reached its adult form, the squamosal canal being now very large, and the two crura which it separates articulating with the cranium just as in the adult. The zygomatic process agrees with that in the younger fœtus.

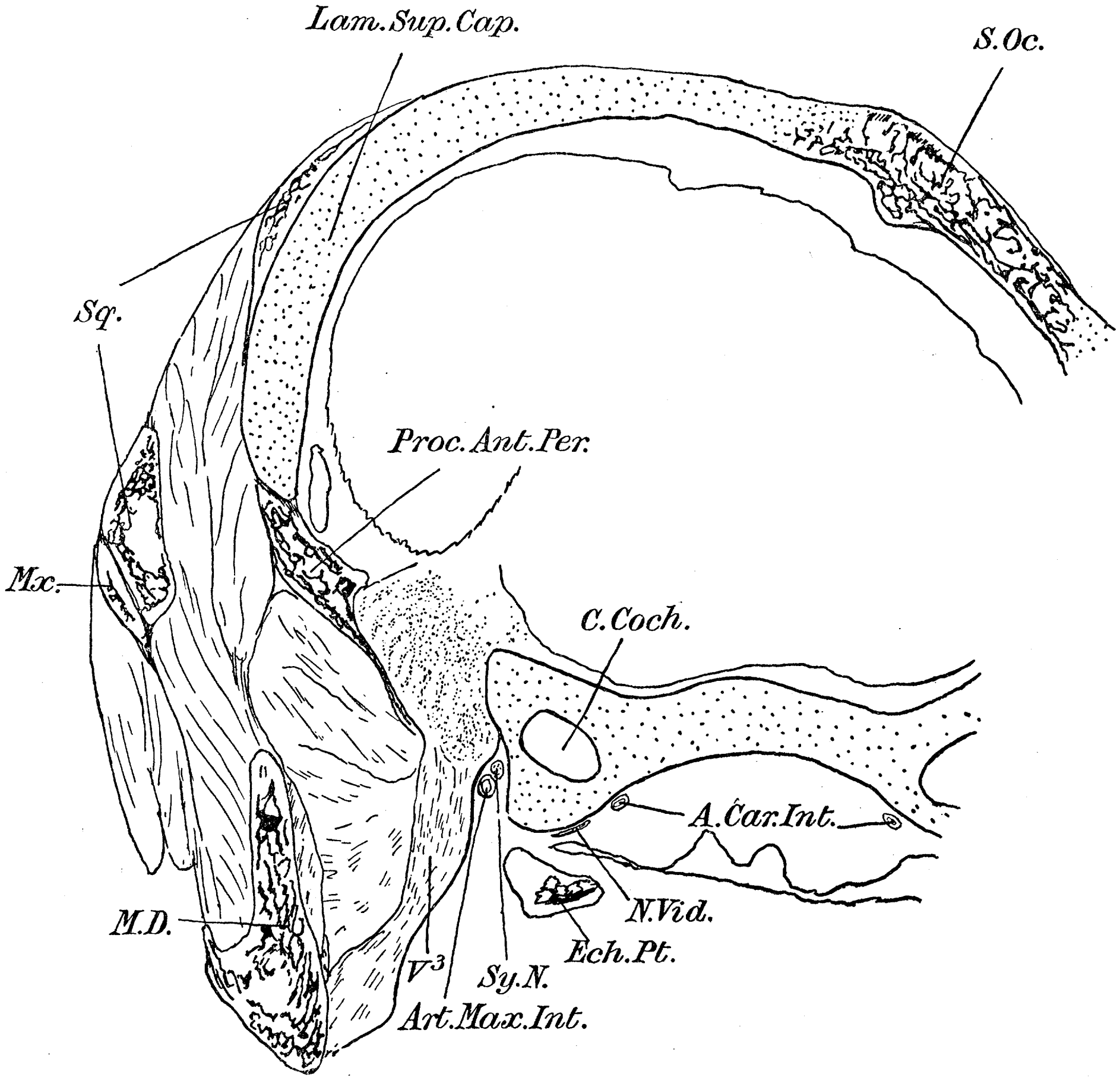

FIG. 10.—As in fig. 8. Section 140, slide B 44, row 2, sec. 3. Reference letters as before, with—*C. Coch.*, cochlear recess; *N. Vid.*, Vidian (parabasale) nerve; V^3, mandibular branch of the fifth nerve.

The *jugal* is still a distinct bone of similar shape and relations to that described in Specimen δ.

The only remaining bones except those of the snout, previously described by Professor WILSON, are a pair of very remarkable ossifications in the ala orbitalis. Each of these is a thick double ectochondral ossification stretching from a point just in advance of the anterior termination of the ossification of the membrana spheno-parietalis as far forward as the orbitonasal fissure.

Ossicula auditus.

In general features the auditory ossicles of Specimen β resemble those of δ. The stapes is a short straight cartilaginous rod, with a distinct but not large foot-plate. Its distal end is in very close (apparently cartilaginous) connection with the incus.

The *incus* is a flattened nodule of cartilage in which there is incipient ossification. It is no longer in direct cartilaginous connection with the crista parotica, but its crus brevis is continued by a ligament which reaches round over the lower margin of the crista parotica to be inserted on its lateral surface. Nearly the whole outer surface of the incus is articulated with the malleus.

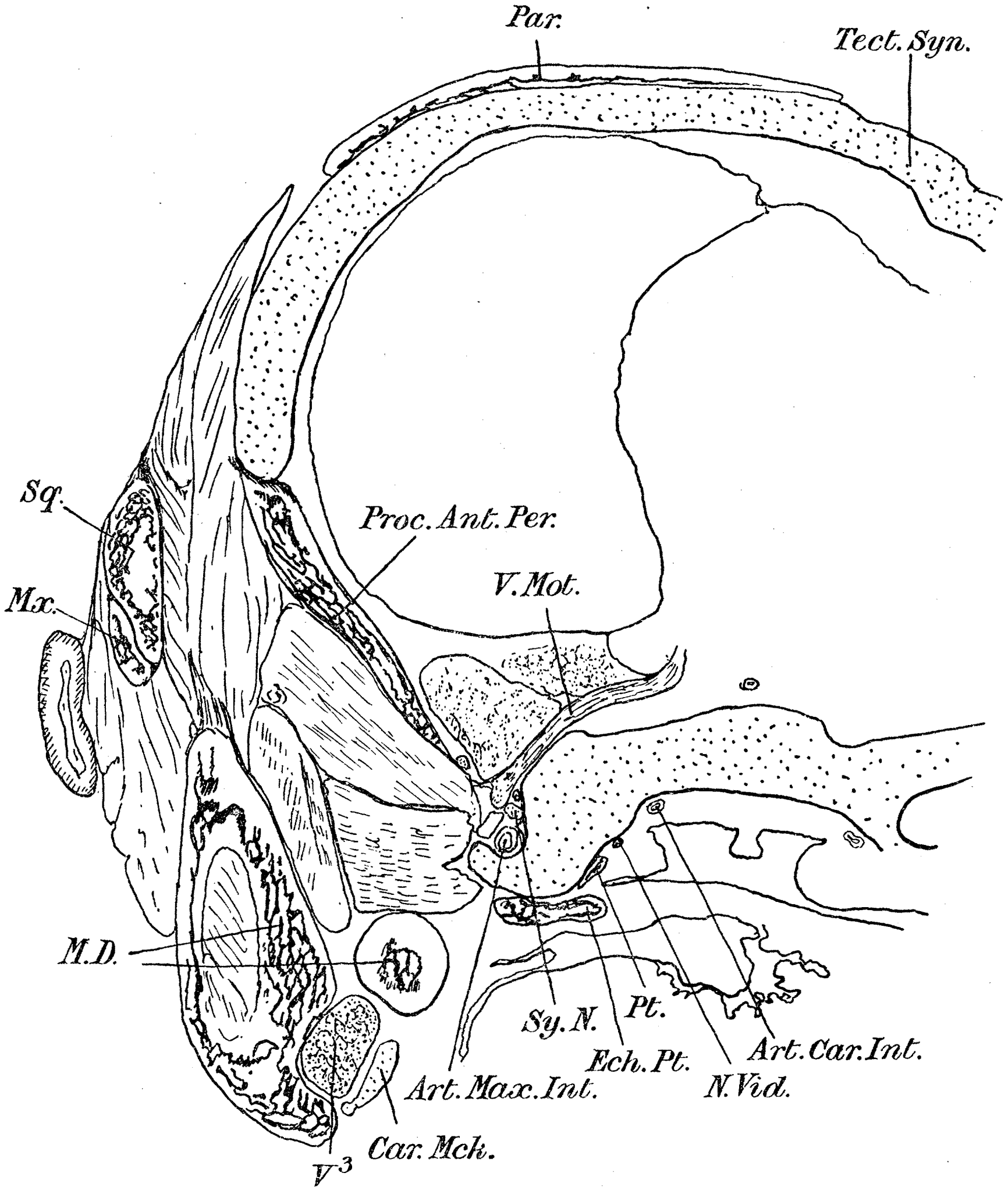

FIG. 11.—As in fig. 8. Section 104, slide B 50, row 2, sec. 3. Reference letters as before, with—*Car.Mck.*, Meckel's cartilage; *V.Mot.*, motor branch of the fifth nerve.

The body of the *malleus* is a very thin plate of cartilage lying outside the incus, and with its lower margin and the ventral part of its inner surface lying in a special depression in the hyoid cartilage, which here, immediately ventral to the fenestra vestibuli, is in contact with the auditory capsule.

From the thin body of the malleus Meckel's cartilage gradually detaches itself, becoming much thicker as it runs forward. From the lower part of the very thin body the thick manubrium runs forward to terminate in the centre of the tympanic membrane. The whole proximal part of Meckel's cartilage is well ossified, the ossification running back in the upper part of the body of the bone to the region of the stapes.

The *pre-articular* (GONIALE) is completely fused with the ossified Meckel's cartilage behind, but in advance of the foramen for the chorda tympanii which pierces it, separates from that element and passes inwards and upwards until its anterior end comes into close relationship to the posterior end of the "Echidna pterygoid.".

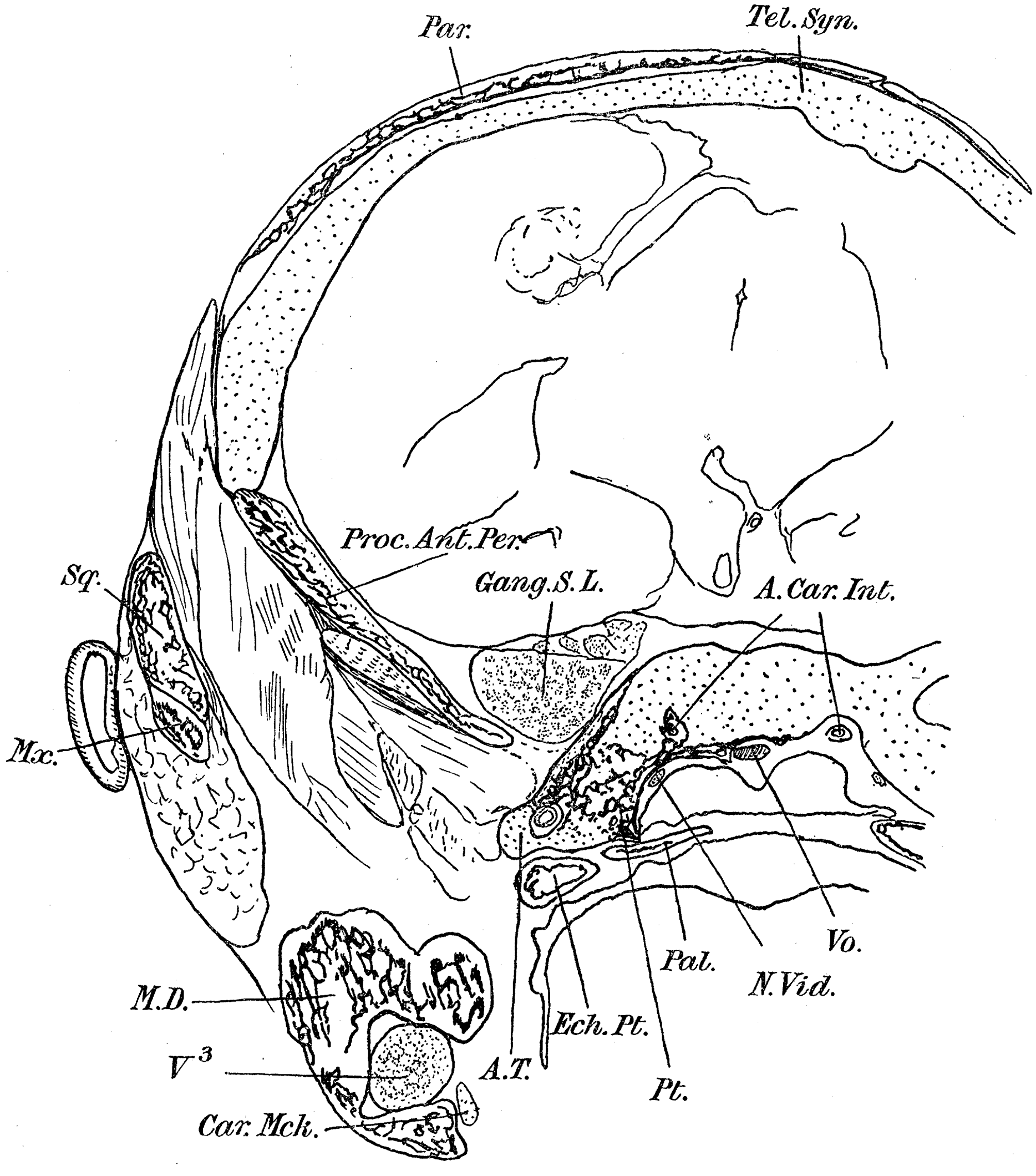

FIG. 12.—As in fig. 8. Section 67, slide B 56, row 2, sec. 3. Reference letters as before, with—*Gang.S.L.*, ganglion semilunare.

The musculus tensor tympani is inserted on to the inner side of Meckel's cartilage or of the pre-articular fused with it immediately in advance of the body of the malleus.

One curious feature which I do not at all understand is the presence of a small, very thin, perfectly independent cartilage lying closely adpressed to the lower part of the outer side of the body of the malleus.

The *tympanic* is a purely membrane ossification with its upper limb lying in close connection with the inner side of the pre-articular, which is grooved to receive it. Its lower limb rises smoothly from the upper and curves gently round the ventral (internal) border of the tympanic membrane.

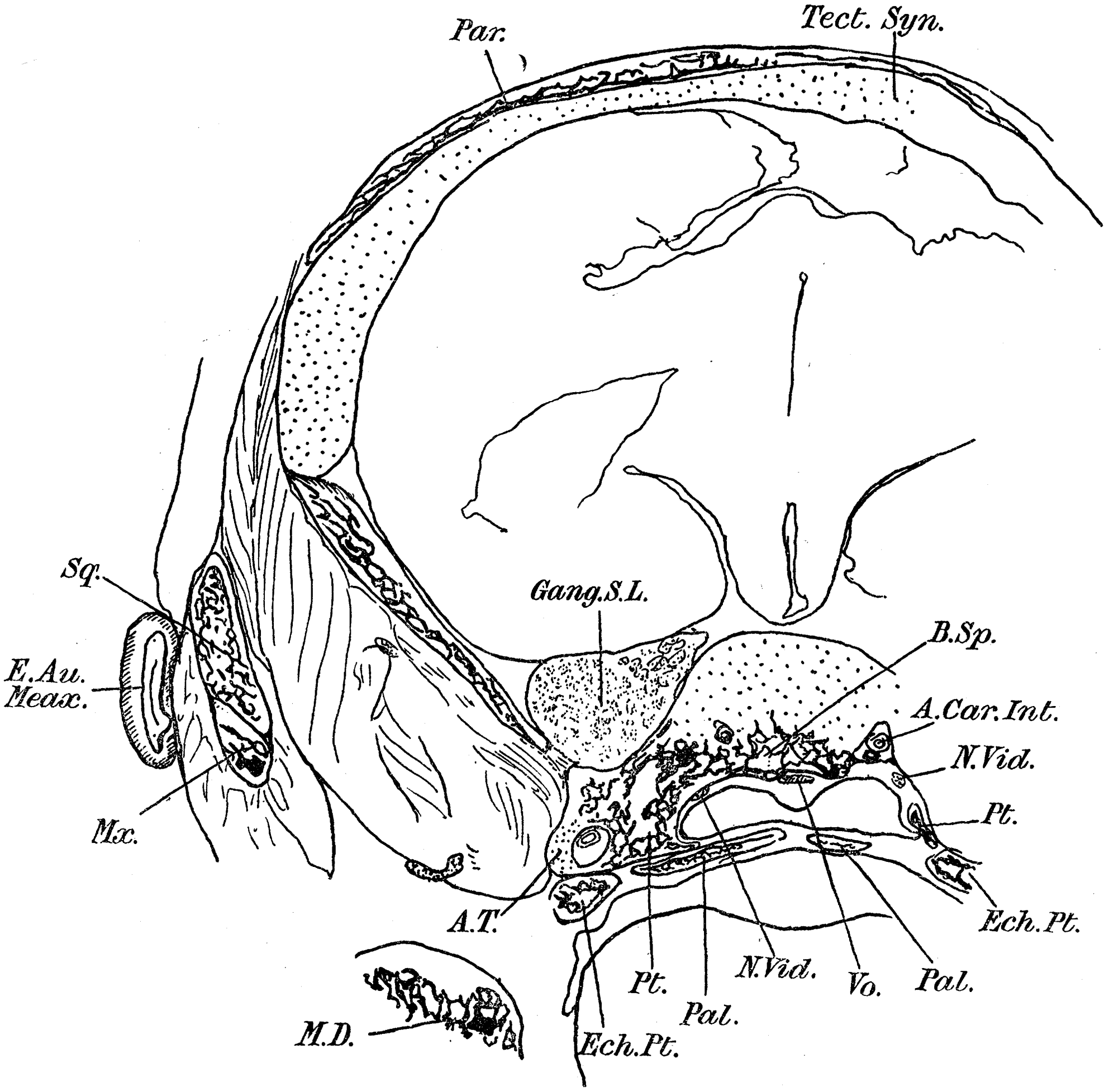

FIG. 13.—As in fig. 8. Section 48, slide 59, row 2, sec. 4. Reference letters as before, with—*B.Sp.*, basisphenoid.

The *dentary* (mandible), so far as can be seen without plastic reconstruction, is of practically adult form. Meckel's cartilage runs forward along its lower and inner side in a special groove, and is completely ossified anteriorly.

The Courses of Some of the Nerves and Blood-vessels round the Skull.

The twelfth, eleventh, tenth, and ninth nerves leave the skull through the large foramen jugulare, a feature quite peculiar to and no doubt developed in the monotremes.

The auditory nerve leaves the skull through the internal auditory meatus and is distributed to the internal ear, the details being of no importance for our present purpose.

The facial nerve leaves the skull by the Fallopian canal, in the outer end of which is the small geniculate ganglion. From this the great superficial petrosal nerve turns forwards and almost immediately passes right through the otic ganglion, presumably receiving some sympathetic fibres at this time; the resulting nerve, the Vidian, runs inwards over the pars cochlearis of the capsula audita behind the "Echidna pterygoid" until it lies on the lower surface of the planum basale just external to the internal carotid artery.

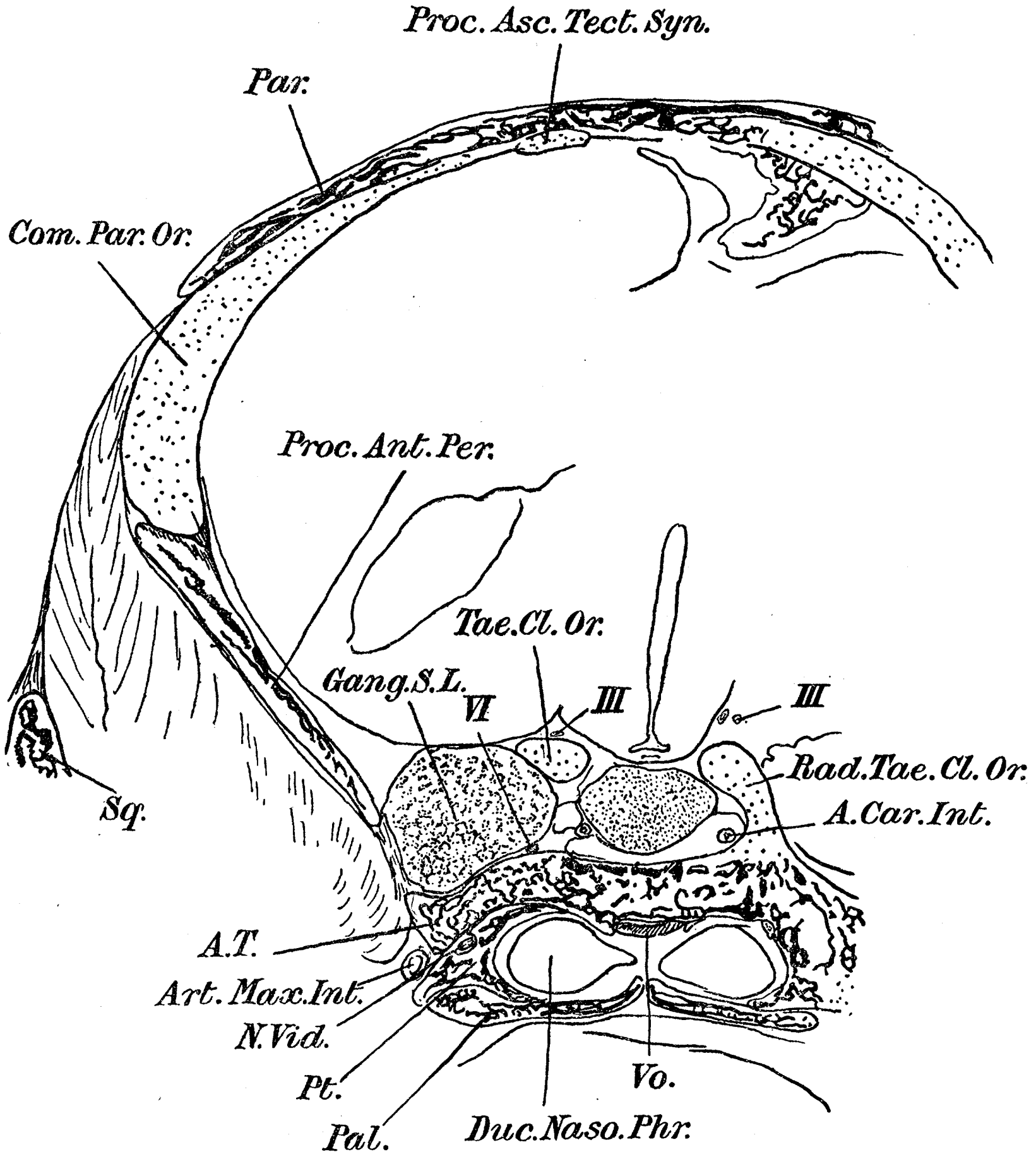

FIG. 14.—As in fig. 8. Section 2, slide 64, row 1, sec. 2. Reference letters as before, with—*Duc.Naso.Phr.*, ductus nasopharyngeus; *Proc.Asc.Tect.Syn.*, processus ascendens tectum synoticum; *Rad.Tæ.Cl.Or.*, root of the tænia clino-orbitalis.

The Vidian nerve continues forward above the posterior end of the pterygoid until it passes between that bone and the ala temporalis, finally running forward along the outer face of the pterygoid to the spheno-palatine ganglion.

The otic ganglion lies in a depression on the outer surface of the pars cochlearis of the auditory capsule. It is formed by a large sympathetic nerve which runs up the neck in close connection with the internal carotid artery, but separates from that vessel as it passes medial to the otic capsule on to the planum basale. This nerve splits up, apparently, into a reticulation, the resulting nerves fusing in the large ganglion, which is pierced by the great superficial petrosal of the seventh nerve.

From the ganglion a nerve of medium size passes forwards lying along the inner side of the internal maxillary branch of the external carotid artery; it has connections with the mandibular and motor division of the fifth nerve, and then splits into two, the larger branch running forward dorsal to the internal maxillary artery, and the smaller passing under the semilunar ganglion. As the artery enters the foramen in the ala temporalis the nerve accompanying it decreases very rapidly in size and turns inwards to join the other branch below the Gasserian ganglion, the joint nerve running forward.

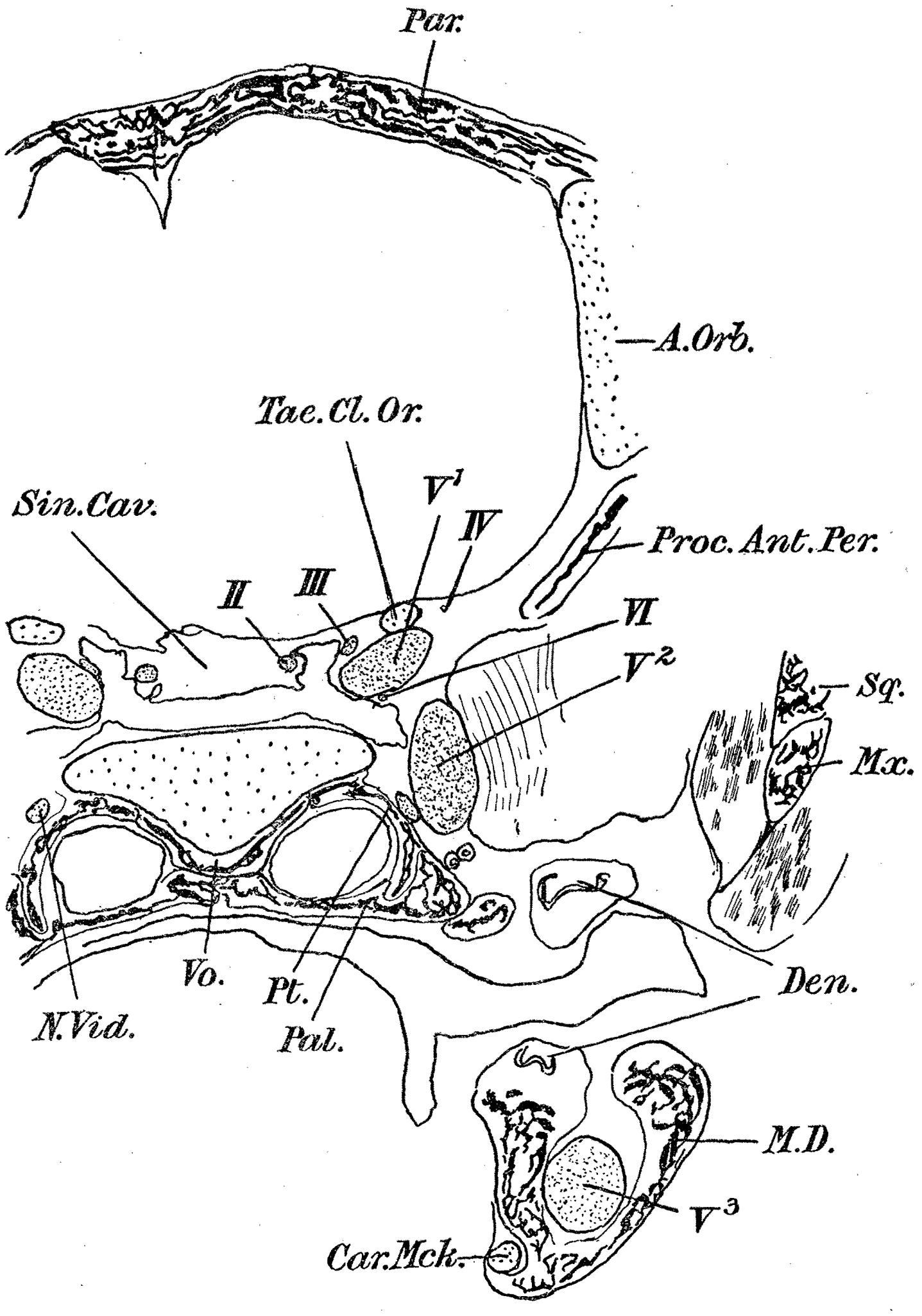

FIG. 15.—As in fig. 8. Slide A 34, row 1, sec. 1. Reference letters as before, with—*Den.*, teeth; *II*, *III*, *IV*, V^1, V^2, *VI*, the corresponding cranial nerves.

The main portion of the seventh nerve runs backward in the sulcus facialis, which is partly converted into a canal, until at the posterior end of the crista parotica it gives off the chorda tympani, which passes across the outer side of Reichert's cartilage, between that element and the lower part of the body of the malleus, then alongside the musculus tensor tympani which grooves the posterior end of the tympanic cavity, to pass through a foramen in the pre-articular, and so forwards somewhat removed from the dorsal surface of Meckel's cartilage.

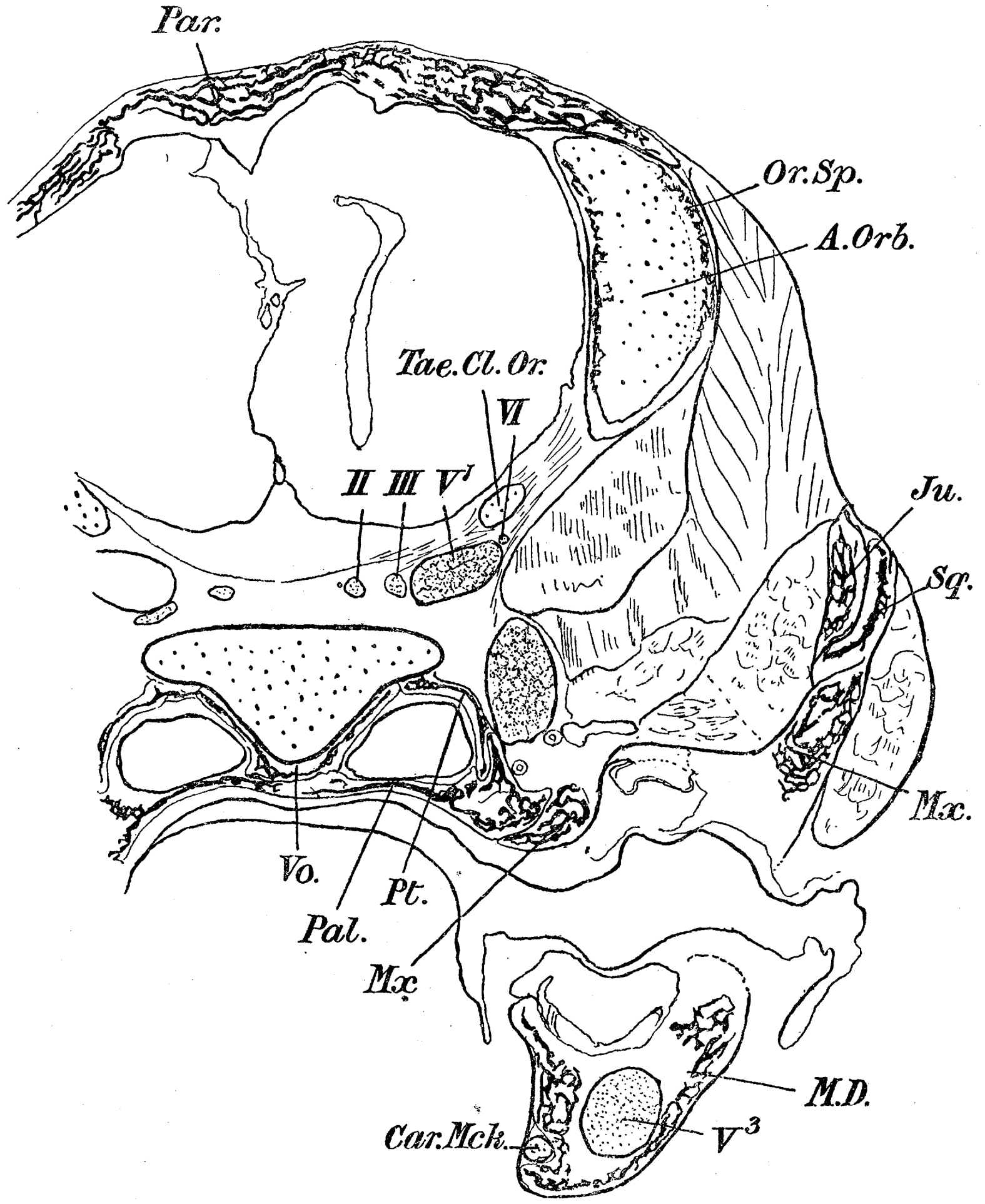

Fig. 16.—As in fig. 8. Slide A 29, row 2, sec. 4. Reference letters as before.

The sixth nerve is rather difficult to follow on account of the short gap represented only by imperfect sections. It seems to run along below the semilunar ganglion, receiving a small branch from the sympathetic nerve, and passing out on the lower and outer surface of the ophthalmic branch of the fifth nerve. It lies entirely outside of the tænia clino-orbitalis.

The trigeminus has an enormous semilunar ganglion, and all its sensory branches are of very great size. The mandibular division leaves through the space between the membrane bone in the membrana spheno-obturatoria, which is continuous with the otic capsule and the pars cochlearis of the capsule, its posterior border being clasped by this bone.

The small motor portion of the fifth nerve passes downwards from its origin and then directly outwards below the ganglion semilunare, leaving the cranial cavity by the anterior part of the slit below the membrane ossification in the sphenoparietal fissure and the posterior end of the ala temporalis. It lies dorsal to the arteria maxillaris interior and the sympathetic nerve and to the abducens.

The ophthalmic and maxillary branches of the trigeminus are of enormous size, and leave by the anterior part of the sphenoparietal fissure. The maxillary branch runs forward outside the pterygoid, from which it is separated by the Vidian nerve, gives off a branch to the sphenopalatine ganglion, and finally enters a great canal in the maxilla.

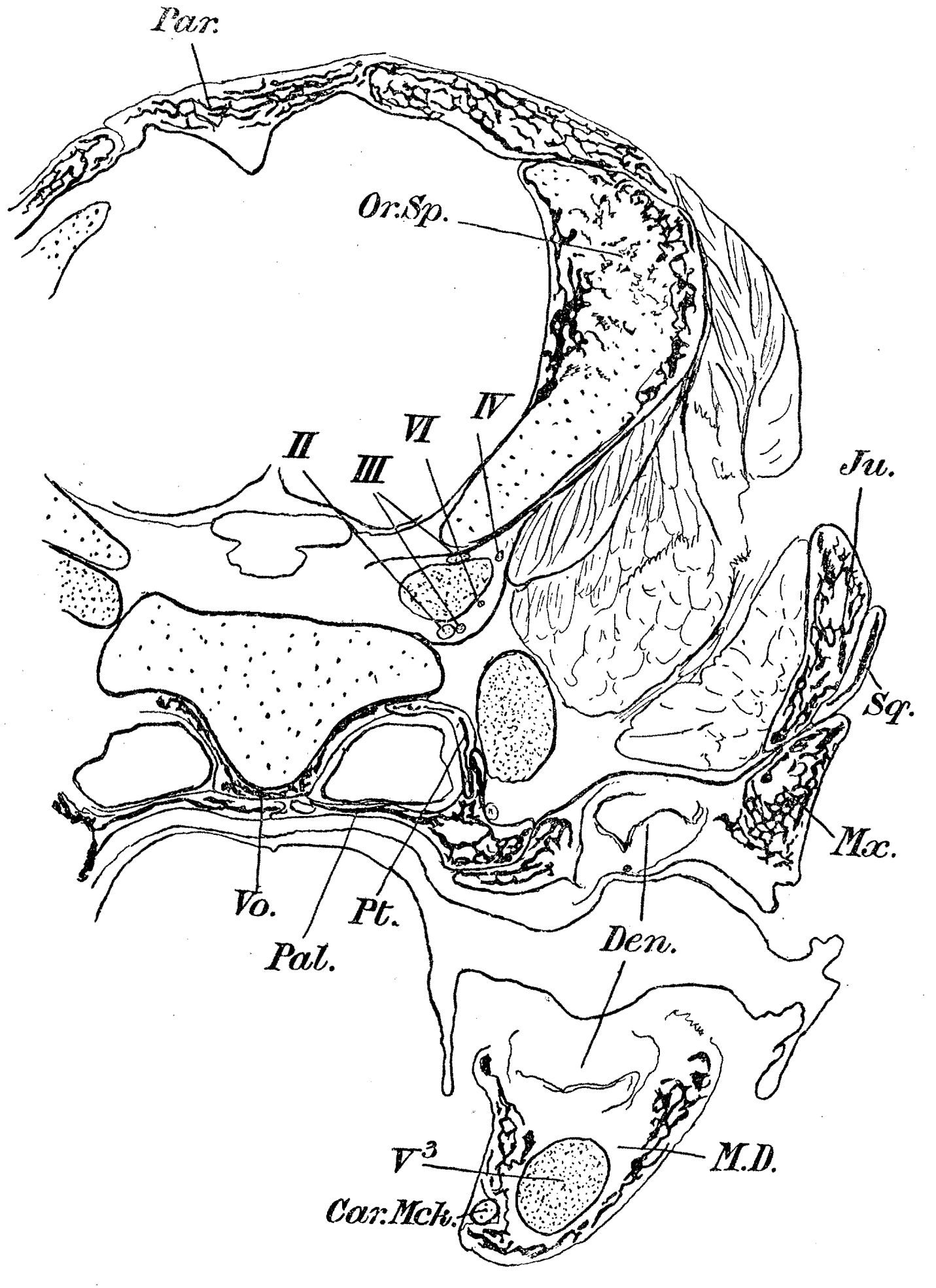

FIG. 17.—As in fig. 8. Slide A 27, row 2, sec. 5. Reference letters as before.

The ophthalmic branch runs forward and upwards, passing through the orbitonasal fissure and immediately entering a canal in the paries nasi.

Owing to the gap in the series of sections I have not been able to trace the whole course of the fourth nerve. In the anterior portion of its course it lies dorso-lateral to the ophthalmic division of the fifth nerve.

The third nerve descends from its origin to the upper surface of the base of the tænia clino-orbitalis, and gradually passes on to the inner side of that bar lying in the roof of the sinus cavernosus, passing out through the pseudo-optic fissure, as Gaupp has shown it to do in Echidna. It then divides into two branches, one of which passes above and the other below the ophthalmic branch of the fifth nerve.

The optic nerves are of very small size, and have a normal course, lying mesial of the third nerve in the roof of the cavernous sinus, and passing out through the fissura pseudo-optica under the ophthalmic branch of the fifth nerve.

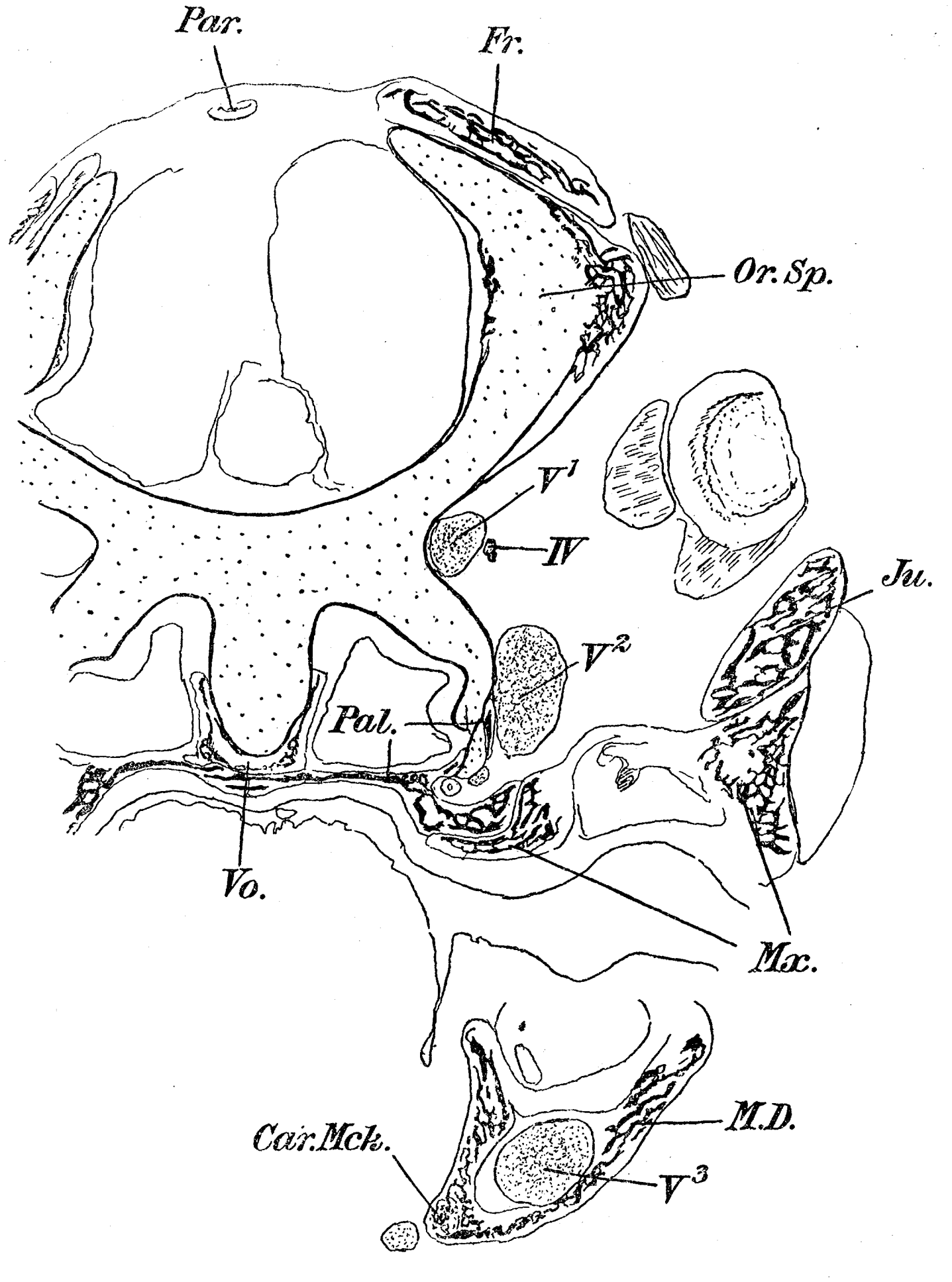

Fig. 18.—As in fig. 8. Slide A 23, row 2, sec. 5. Reference letters as before.

The external carotid artery enters the sulcus facialis at the posterior end, running forward immediately ventral to the seventh nerve, it gives off the superficial temporal artery, which is a small branch passing out through a foramen in the membranous ossification associated with the otic capsule. The remaining portion of the artery, the internal maxillary branch, then runs forward between the incus and the pars cochlearis of the otic capsule, above the musculus tensor tympani, finally, in close connection with the sympathetic nerve, running forward from the otic ganglion below the exits of the mandibular and motor branches of the fifth nerve to enter and pass through the canal in the ala temporalis.

The internal carotid passes up the neck in company with the main sympathetic nerve, and reaches up, to lie immediately below the pars cochlearis of the otic capsule, farther forward it passes on to the lower surface of the planum basale, and has a simple course forward to pass through the carotid foramen to the posterior end of the sella turcica.

The course of the vena capitis lateralis has been described above in connection with the ossification of the otic capsule; inside the skull it splits up into two main divisions, one of which runs upwards and backwards in the dura mater. The other splits up and seems to send branches both above and below the ganglion semilunare to the sinus cavernosus.

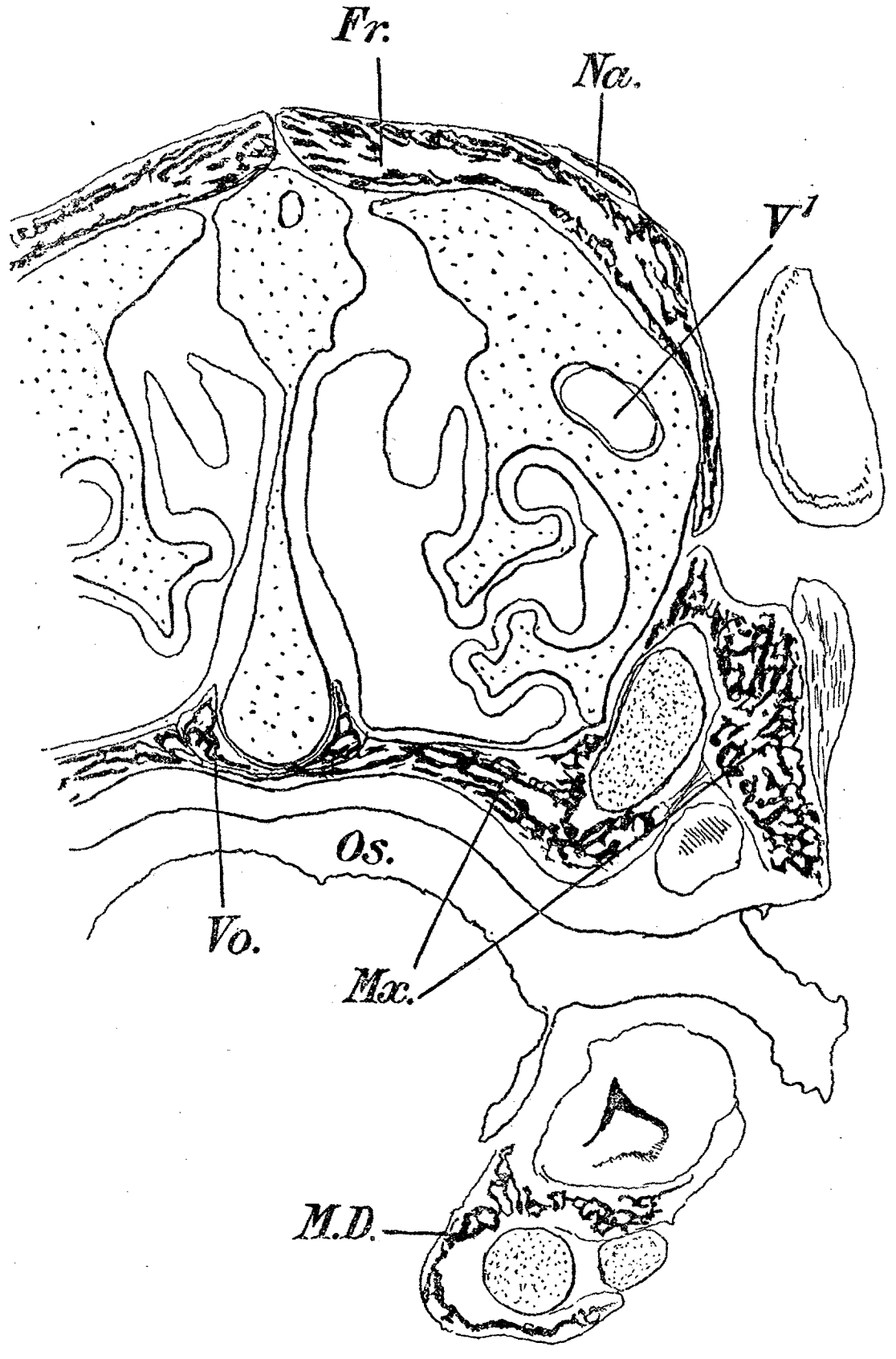

FIG. 19.—As in fig. 8. Slide A 12, row 3, sec. 2. Reference letters as before.

V. THE ADULT SKULL OF ORNITHORHYNCHUS.

I have unfortunately been unable to find in any Australian institution a skull of a young adult Ornithorhynchus which shows the sutures, but the specimen described in the preceding pages has so nearly reached its adult form as to justify me in criticising Prof. VAN BEMMELEN's description.

In fig. 4, Plate 32, of his paper, a figure of the side of the skull of Platypus with the zygomatic arch removed, it is at once obvious that the area labelled *plt. tmp.*, and supposed by him to be a "temporal plate of the palatine," is really entirely the ossified ala temporalis, as is shown conclusively by the passage of the "pterygoid canal" through it and by the articulation of the Echidna pterygoid with its lower and outer edge.

The large bone labelled *ali. sph.* (alisphenoid) is really the large ossification in the membrane closing the sphenoparietal fissure, which in Specimen β is in complete continuity with the anterior ossification in the periotic capsule.

The bone labelled *mast. pter.* (ala pterotica mastoidea) can only be an ossification of the commissura parieto-orbitalis, a view which is supported by the fact that in Prof. SEELEY's fig. 7 ('Q.J.G.S.,' vol. 56, p. 643 (1900)) its anterior end is seen to be squarely truncated and separated by a space from the squarely truncated hinder end of the "postfrontal," that is the ossification in the ala orbitalis. In Prof. VAN BEMMELEN's skull it is no doubt in complete osseous connection with the rest of the periotic, but whether it be ossified by extension from the great cartilage ossification which surrounds the foramen fallopii, or whether, as I think perhaps more probable, it arises from a separate centre, is unknown. In VAN BEMMELEN's figure the suture labelled *prc. ptrg.* is probably that between the pars cochlearis of the periotic and the basisphenoid.

In this figure the area of bone between the foramen "rotundum" and the "sphenorbital and optic" foramen, which is labelled *sph. bsl.* (basisphenoid), is at any rate in large part pterygoid, the long process lying between the presphenoid and the palatine being entirely that bone.

I have never, in any skull, seen any trace of VAN BEMMELEN's parietal laterale.

The incomplete suture between the foramen vasculare lateralis and the processus mastoideus must mark the place where the backward process of the ossification in the sphenoparietal membrane and the processus parioticus superior meet and join.

VI. THE SKULL OF ECHIDNA.

Examination of Echidna, of which I have very abundant material, will lend support to these criticisms. The skulls of pouch-young of Echidna at my disposal are slightly older than that figured by VAN BEMMELEN, but agree with it in all important features.

There is a large basioccipital bone and a small basiphenoid ossification showing clear evidence of derivation from two centres. The small ala temporalis is still entirely cartilaginous, and immediately in advance of its anterior end is a small "temporal" wing of the palatine.

The "Echidna pterygoid" articulates with its lower surface posteriorly. The pterygoid is a long slip of bone lying mesial to the ala temporalis in the side wall of the ductus nasopharyngeus. The great sphenoparietal fissure is closed by a thick membrane, and there is no ossification in the otic capsule.

In young adult skulls I can corroborate VAN BEMMELEN'S accounts of the nasal and occipital regions, but find it necessary to re-describe the palate and orbito-temporal region.

Skull No. S 1154 of *Echidna aculeata* is so young that it disarticulates very readily and completely. The basisphenoid is already completely fused with the presphenoid, if such a bone has an independent existence in monotremes, of which I am doubtful, and with the ethmoidal ossification and the orbitosphenoids.

The pterygoids are fused with the basisphenoid at the middle of their length, but the anterior and posterior ends are still perfectly distinct.

The basisphenoid consists of a median body with a low ridge on the ventral surface and the sella turcica dorsally; as Prof. WILSON has shown, the walls of that depression are formed by the ossified hinder ends of the tæniæ clino-orbitales. The basisphenoid is perforated by the widely separated carotid foramina which enter the sella turcica.

This massive part of the basisphenoid is continued outward by a thin lateral process on each side. The posterior end of this is in contact with the periotic by a small face. The lateral border has its ventral surface in contact with the Echidna pterygoid, and the anterior part stands out and forwards as a special process lying immediately posterior to the temporal wing of the palatine; comparison with the pouch-young skulls of Echidna shows that this process is beyond question the ossified ala temporalis. Its posterior edge is in contact with the Echidna pterygoid.

The pterygoid is a thin strip of bone lying on the ventral surface of the basisphenoid just medial to the ala temporalis.

Its anterior end extends forward, quite free in this skull, along the under surface of the basis cranii. In the middle of its length this bone is fused with the thin lateral part of the basisphenoid forming the lateral wall of the ductus nasopharyngeus, posteriorly it slightly overlaps the basisphenoid on to the petrosal, the separate articulation with that bone being very obvious in the skull named. This region articulates also with the Echidna pterygoid. In the middle of its length the pterygoid is pierced by a small foramen for the Vidian (parabasal, GAUPP) nerve, which must pursue a course exactly similar to that described by GAUPP in pouch-young.

The palatine agrees generally with VAN BEMMELEN'S description, the exact relations of its orbital wing with the ethmoid, orbitosphenoid and frontal are subject to considerable individual variation, but in most cases, at any rate, the frontal, orbitosphenoid and orbital plate of the palatine exclude the ethmoid from the orbit.

The temporal wing of the palatine is quite certainly a mere process of the bone, its gradual increase in size being obvious in my series of skulls, where in pouch-young it is a very small tubercle rising in front of the still cartilaginous ala temporalis; in full-grown adults it fuses with a process from the orbital wing completely to surround the exits of the cranial nerves V (1 and 2), VI, IV, III, and II.

In the very young skull under consideration there is still a large sphenoparietal fissure unclosed by bone. The series of skulls figured in Plate 1 shows the gradual outgrowth of two processes from the anterior edge of the periotic, which meet and fuse with each other and with the ala pterotica mastoidea, of VAN BEMMELEN, and grow forward to acquire a connection with the orbitosphenoid, the temporal wing, and the process growing down to it from the orbital wing of the palatine, and the ala temporalis.

Comparison of this description of Echidna with the criticisms of VAN BEMMELEN'S description of the Ornithorhynchus skull on p. 336 and the detailed description of Specimen β of Ornithorhynchus shows that the two living monotremes agree in that the sphenoparietal fissure is not closed by an ossification of the ala temporalis, that is an alisphenoid, but by the gradual growth forward of an ossification which is always continuous with the anterior ossification of the otic capsule, and only very late in life acquires any connection with the ala temporalis.

This fact, which is obvious in presence of suitable material such as that figured from untouched photographs of Echidna skulls in Plate 1, is of fundamental importance in any discussion of the homologies of the bones of the monotreme skull, but seems to have escaped the attention of all previous authors, with the partial exception of Prof. GAUPP.

VIIA. DISCUSSION OF THE OTIC CAPSULE OF MONOTREMES.

It is now necessary to discuss the homology of the anterior process of the periotic. Such discussion divides itself into two parts: (1) Are the processes in Echidna and Ornithorhynchus the same? and (2) what do they correspond to in Reptiles and later mammals?

It will be remembered that when describing the anterior process of the periotic in Specimen β I pointed out its relationship to the vena capitis lateralis, the superficial temporal artery, and the seventh nerve, and that it directly continued the line of the crista parotica, or rather of its processus perioticus superior. It is quite easy to recognise quite similar relations in the adult skull of Ornithorhynchus. In such skulls the crista parotica is of very large size, and projects strongly backward. From its lower edge, just posterior to the fenestra vestibuli, a special process supports Reichert's cartilage. The lower border of the ossified crista parotica, the processus mastoideus of VAN BEMMELEN, is continuous with the lower border of the ossification in the spheno-parietal fissure (VAN BEMMELEN'S alisphenoid). Just below and mesial to the external opening of the facial foramen the bone, whose lower edge is otherwise free, has a prominent thorn-like process, and is connected with the outer surface of the periotic so as to form a canal through which the hyomandibular branch of the seventh nerve runs backward. Posterior to this, in the deep pocket between the lower edge of the membrane ossification and the external surface of the periotic above the fenestra vestibuli, there are the lower openings of two canals, the larger of which, for the vena capitis lateralis, runs upwards, outwards and backwards to open on the inner surface of the skull, dorsal to and lateral of the anterior end of the anterior vertical semicircular canal.

The other foramen for the superficial temporal artery passes forward, upward and outward to open just in front of the glenoid portion of the squamosal; it is VAN BEMMELEN'S foramen vascularis lateralis.

Prof. VAN BEMMELEN'S figure of the periotic of Ornithorhynchus is unfortunately very misleading, as it is quite certain that the so-called margo alisphenoid is nothing but a broken edge.

By comparing together Prof. GAUPP'S Echidna model, my series of sections of a small Echidna, the skull of the pouch-young of Echidna and those of young adults, it is possible to discover accurately the position of the various regions of the periotic.

The otic region of my series of sections of a pouch-young of Echidna slightly more advanced than Prof. GAUPP'S model, differs from it in the development of a distinct though short processus perioticus superior. The distinction of a limbus præcapsularis from a commissura præfacialis is quite obvious.

The vena capitis lateralis runs forward in the sulcus facialis and curves round to enter the skull over the commissura præfacialis, and immediately below the limbus præcapsularis which is, as it were, moulded on it. In front of this vein is a small upstanding cartilaginous process quite similar to that represented by an independent nodule in Ornithorhynchus embryo β. (As this does not occur in the skull of an older pouch-young of Echidna it may be only exceptionally present.)

In the ossified periotic the vena capitis lateralis passes through a canal whose inner opening always lies in the line of the ventral edge of the upper of the two processes which grow forward in the membrane closing the sphenoparietal fissure.

From the canal for the vena capitis lateralis a small foramen opens outwards at about the level of the lower edge of the squamosal; it is sometimes slightly above and sometimes below this line; it varies considerably in size and may be double. It agrees exactly in position with the foramen vascularis lateralis of VAN BEMMELEN in Ornithorhynchus, and, no doubt, like that opening, transmits the superficial temporal artery, a groove for which may be seen on the outside of the periotic in front of it.

The foramen fallopii primitivum opens into the canal at its hinder and lower end, and the ramus palatinus runs forward through a hiatus Fallopii, which forms a canal of variable length. It sometimes stretches to the extreme antero-internal corner of the bone.

The lower of the two bony processes in the sphenoparietal membrane lies outside the course of the nerve and in older stages surrounds the hinder and outer side of the mandibular division of the fifth nerve.

Comparison of this account with that of Ornithorhynchus given above will show that the two processes in the sphenoparietal membrane in the one type are strictly homologous with the one in the other, the lower process in Echidna being generally homologous with the small process which in Ornithorhynchus invariably bounds the back of the mandibular division of the trigeminus.

The difference between the two forms depends very largely on the fact that in Echidna there is a distinction between the limbus precapsularis, from which the upper process starts, and the commissura prefacialis which gives origin to the lower process, whilst in Ornithorhynchus the front border of the otic capsule is one uniform curve.

VIIb. Comparison of the Monotreme Otic Capsule with that of Reptiles.

I have shown above that in Ornithorhynchus in the only stage at my disposal there are only two ossifications in the otic capsule.

The first of these surrounds the fenestra cochleæ and extends forward under the cochlea and backwards below that posterior part of the vestibule which goes to the hinder ends of the posterior vertical and horizontal semicircular canals. This ossification corresponds very closely with the paroccipital of a reptile, which also surrounds the fenestra cochleæ, the hinder halves of the posterior vertical and horizontal canals, and forms the hinder wall of the cochlear recess.

The other ossification, lying around the anterior part of the root of the crista parotica, running forward above the fenestra vestibuli, completely surrounding the foramen faciale and extending out to the anterior face of the pars cochlearis, agrees equally closely with the reptilian prootic if the great ossification in the membrana sphenoparietalis be disregarded.

The conditions in Ornithorhynchus, and still more those in Echidna, show that this is really an integral part of the prootic ossification, with which it is always in complete bony connection and from which it grows forward. The alisphenoid of man (for example) affords a good example of a bone which is undoubtedly one morphological entity arising partly as an ossification replacing a cartilage and partly as an extension of ossification from the cartilage into membrane.

In reptilian embryos, Lacerta, Sphenodon, Crocodilus, Emys, there is a distinct crista parotica lying, as in mammals, on the outer side of the ear capsule in the region of the horizontal semicircular canal. The series of figures of models of different stages of Sphenodon figured by Swynnerton and Howes shows that this actually becomes the large paroccipital process of the adult which is mainly ossified by the opisthotic, but has a thin slip of prootic on its anterior surface.

The hyomandibular branch of the facial nerve and the vena capitis lateralis lie in the groove between the crista parotica and the ear capsule, just as they do in Ornithorhynchus.

In adult lizards the vena capitis lateralis and the seventh nerve run forward together under the paroccipital process and then pass into the deep groove between the crista prootica and the prootic. The external opening of the facial foramen lies in this deep groove. The vena capitis lateralis in front of the facial foramen passes downwards to the side of the basisphenoid, receiving the vena cerebralis media as it does so; this vein passes down from the endocranial cavity through the incisura prooticum. In Prof. GAUPP'S model of the Lacerta chondrocranium the crista prootica is already obvious as a ridge lying considerably in front of, and quite distinct from, the crista parotica.

It will be noticed that the relations of the crista prootica in lizards are quite similar to those held by the posterior part of the membrane ossification of the prootic in Ornithorhynchus, for that region lies outside the external opening of the facial foramen and the vena capitis lateralis runs mesial to it. Furthermore, it lies entirely anterior to the crista parotica, with the processus perioticus superior of which it only comes in contact in still later stages.

It is, therefore, natural to hold that the lower and posterior part of the process of the prootic of monotremes, which closes the sphenoparietal fissure, is homologous with the crista prootica of lizards.

It may be objected that the two differ in their mode of development, one replacing cartilage, the other being formed purely in membrane. It is, I think, now commonly recognised that a distinction of this kind has not the great morphological importance which was formerly claimed for it, and, furthermore, it seems very probable that part of the crista prootica in those lizards in which it is a very deep and thin ridge is actually not preformed in cartilage.

The group of the Therapsids is now recognised by the great majority of palæontologists as lying in very close relation to the reptilian ancestors of the Mammalia. The evidence for this close relationship, which rests not only on an enormous series of independent resemblances, but on the gradual and steady approach to mammalian structure which takes place with time, has recently been summarised by BROOM, GREGORY, and the present author, and need not be further discussed. I feel, however, that it is essential to consider the conditions of the otic region in this group, because the mode of development of the mammalian periotic from the reptilian otic region is still a very obscure one, and is furthermore of great importance for a true appreciation of the process and reasons which have led to the development of the mammalian skull. The most primitive Therapsid of which the otic region is known to us is Dimetrodon, where it has been described by CASE and v. HUENE (many of whose determinations require revision), and figured in another connection by myself.

Except for the presence of the typical Therapsid character of a very ventrally situated vestibule and a broad supra-occipital, this region in Dimetrodon agrees so closely with that in a lizard as to render the homologies of the various parts quite obvious.

There is a powerful paroccipital process formed mainly by the opisthotic but with a thin film of prootic on its anterior face. The prootic is pierced by the facial foramen in the ordinary way. Somewhat behind the foramen is a large and well defined crista prootica.

In a skull of the Anomodont Endothiodon in the British Museum there is a well defined crista prootica, below which is a large rounded groove, undoubtedly for the vena capitis lateralis, which leads forward to the incisura prooticum. The external opening of the facial foramen lies somewhat ventral to the crista, immediately below the groove. In the majority of Anomodonts the crista prootica is less well defined, but occupies a similar position.

The brain case of the "Therocephalia" and Gorgonopsids is not yet known in great detail, but that of the Cynognathids, the most advanced of all Therapsid groups, has been described by the present author, and is nearly as well known as that of Echidna. The only feature which at present concerns us is the structure of the lateral surface.

The prootic of Diademodon corresponds generally with that of any more primitive Therapsid, but is modified by the development of numerous special processes.

The crista prootica is readily recognised in a thin flange covering a deep groove for a vein which runs from the pterygo-paroccipital fossa to the incisura prooticum; the vein is obviously the vena capitis lateralis, having absolutely its normal position in a lizard. From the hinder and outer end of the crista prootica a special process is given off which runs outwards, lying parallel to and in front of the paroccipital process, to meet a similar special process of the squamosal. Another flange, also covering a venous canal, runs directly upwards from the special squamosal process of the crista prootica; the vein which it covers when it reaches the level of the parietal turns forward, and runs for a long distance towards the ethmoidal region; it receives a branch from the cranial cavity through a special foramen between the prootic and the parietal.

On the outer surface the prootic is overlapped by the parietal, and its anterior and upper corner is prolonged by a special process which runs forward in contact with the lower edge of the parietal, medial to the epipterygoid, whose posterior border overlaps the outer surface of the prootic in a suture, which terminates below in the foramen for the fifth nerve, at the prootic fissure. This anterior projection has arisen within the group Therapsida; there is absolutely no trace of it in Dimetrodon; in the Anomodont skulls I have examined it can scarcely be said to be represented. In the Gorgonopsid *Scymnognathus Whaitsi* it is present and distinct, though very small; this type is in many ways a morphological ancestor of the Cynognathids. In Cynognathids the process is large, and seems to have more the appearance of a membrane than of a cartilage bone.

The whole appearance of the inner side of the brain cavity is such as to suggest that the commisura parieto-orbitalis was never ossified, the hinder end, the lamina supracapsularis, remaining in the cartilaginous condition in the adult skull.

The external opening of the facial foramen lies far below the crista prootica, separated from the groove for the vena capitis lateralis below it by the development from the prootic of a special process which touches and supports the quadrate ramus of the epipterygoid, and is itself touched by the crista prootica so that the vena capitis lateralis actually runs in a canal for some distance. This process has arisen within the group Cynognathidæ.

Comparison of the otic region of Diademodon with the periotic of Echidna suggests very strongly that the anterior superior process of the Cynodont prootic is really homologous with the upper of the two processes which in the Monotreme close the sphenoparietal fissure; it will be remembered that in this latter type the process arises from the limbus precapsularis, which lies above the incisura prooticum, just as does the Cynograthid process.

The development of a special connection between the crista prootica and the squamosal is of great importance, because in Echidna that part of the periotic which I have shown reasons above for regarding as the homologue of the crista prootica is actually in contact with the squamosal.

VIIc. COMPARISON OF THE PERIOTIC CAPSULES OF MONOTREMES WITH THOSE OF OTHER MAMMALS.

This involves difficulty owing to our extraordinary lack of knowledge of the mode of ossification in any one type, except man, in which even different accounts do not agree.

In a Schultze preparation of a mammary fœtus of a Macropid I find the beginning of ossification at the bottom of the fossa subarcuata. In a series of sections of Dasyurus there were several centres of ossification, the chief forming a ring round the cochlear portion of the capsule; others lay in the fossa subarcuata and on the outer surface associated with the anterior semicircular canal.

The account of the ossification of the human periotic given by VROLIK claims six centres of ossification. Probably all that can legitimately be said is that in its mode of ossification the periotic of Ornithorhynchus much more resembles that of a reptile than it does that of an ordinary placental or marsupial animal.

The crista parotica of the ordinary mammalian embryo, whether placental or marsupial, agrees closely with that of the monotremes. Its anterior corner is extended by a processus perioticus superior, quite similar to that which I find to be present in both monotremes at suitable stages.

Ossification of this process forms the tegmen tympani, or at any rate its hinder end; but in man, BROMAN finds that the anterior part of the tegmen is a separate membrane ossification, which may remain as a separate bone according to BARDEEN.

This author's suggestion that it may represent the ossiculus acessorium malleoli is most probably incorrect, as that bone appears to arise in close connection with the tympanic and Meckel's cartilage (*cf.* VAN KAMPEN'S figure of a new-born sheep), and is hence probably a bone of the reptilian lower jaw.

In the light of our new knowledge of the development of the periotic of Ornithorhynchus, it may be suggested that this ossification in membrane, which subsequently fuses with the processus perioticus superior in man, is actually homologous with the posterior part of the great ossification of the prootic in the membrane sphenoparietalis in monotremes. Its relationships to the fifth nerve and to the tympanic cavity are similar; it fuses with the processus perioticus superior in the same way, and it forms part of the side wall of the brain cavity. Finally, in both cases, it articulates with the squamosal.

VII. THE HOMOLOGY OF THE MAMMALIAN PTERYGOID.

(A.) Before discussing the homologies of the pterygoid and Echidna pterygoid of monotremes it is, I think, necessary to give an account of the development of the Cynognathid palate and epipterygoid. Existing materials are amply sufficient to enable us to determine with certainty the main lines of this development with one or two exceptions. Most of the specimens on which this account is based have already been described, the vast majority either by Dr. BROOM or the present author.

The earliest and most primitive Tetrapod palate which is known is that of the Embolomerous Amphibian Anthracosaurus from the Lower Carboniferous ironstone of Gilmerton, Midlothian, Scotland. This specimen is not well preserved, but is shown to agree in all important features with the Upper Carboniferous "Loxomma."

In "Loxomma" there is a basisphenoid with small but very well marked and protuberant basipterygoid processes. The basisphenoid, which in this type is pierced with a pair of carotid foramina, is indistinguishably fused with a complex bone, the lower edge of which is undoubtedly parasphenoid, while the upper part is equally certainly ethmoidal in origin, surrounding as it does the anterior part of the brain behind, and forming an interorbital septum which runs forward very nearly to the anterior end of the skull.

The lower (parasphenoidal) edge of this bone appears in the palate for a very great distance. The large pterygoids articulate by well-marked faces with the basipterygoid processes, being separated by a very narrow interpterygoid space: they have a posterior ramus extending backward behind the quadrate to touch the squamosal. The anterior rami of the pterygoids have sutural connection with the prevomers, palatines and ectopterygoids. Whether an epipterygoid was present or not is quite uncertain.

This type of palate, which is the only one known in the Lower Carboniferous, affords a morphological ancestor for all other Tetrapod types.

The most primitive known reptilian skull—that of Seymouria from the Texan deposits—has a palate which in nearly all details, including the distribution and mode of replacement of the teeth, is identical with that of "Loxomma." The only difference is that in the Munich specimens a separate small element seems to intervene between the short basipterygoid process and the pterygoid; this bone is presumably the fish metapterygoid, and perhaps gives a clue to the origin of the meniscus pterygoideus of Sphenodon, which may be a secondary articular cartilage replacing it. The actual presence of the element in Seymouria, however, requires confirmation from other specimens. Crushing of the type specimens makes it impossible to say for what distance the parasphenoid appeared on the palate; the bone is actually quite long.

The work of Prof. WILLISTON and the present writer has suggested that the Captorhinidæ, a group of Cotylosauria from the lower Permian (? Carboniferous) of Texas are in some way connected with the ancestors of the Therapsids, and in any case the palate of Captorhinus is very similar to, though somewhat more primitive than, that of Varanosaurus, on the whole the most primitive known Therapsid.

The basisphenoid of Captorhinus has basipterygoid processes projecting downwards and outwards, and much resembling those of Sphenodon. There is a very long parasphenoid shown excellently in a Munich specimen of Labidosaurus, which lies in the palatal roof at least posteriorly.

The pterygoids articulate with the basipterygoid processes by special faces and have between them an interpterygoid vacuity of considerable size. Each sends back the usual posterior ramus behind the quadrate, and runs forward to the prevomer; laterally each articulates with the palatine.

WILLISTON has described the epipterygoids of Labidosaurus as small nodules of bone lying in the upper and outer surface of the pterygoid in the region of its articulation with the basisphenoid.

The structure of the basipterygoid region of the palate in the very primitive Therapsid Varanosaurus is perfectly shown in the beautiful type specimen at Munich, described by Prof. BROILI and the present author. In Varanosaurus the basisphenoid has a great resemblance to that of Labidosaurus, but the basipterygoid processes are horizontally directed. They are provided with definite articular faces.

The parasphenoid is a long bone which can be seen through the orbit running forward for a considerable distance; it is quite stout and, probably, grooved dorsally, clasping the lower edge of the "ethmoid."

The pterygoids resemble those of Captorhinus, but the interpterygoid vacuity is small, the two bones meeting in a long median suture. There is evidence that suggests that the lower edge of the parasphenoid is in contact with the dorsal surface of the pterygoids in advance of the interpterygoid vacuity.

The epipterygoids are slender rods resting on the upper surface of the pterygoids behind the basipterygoid processes.

In the most primitive South African group of Therapsids, the Deinocephalia, the bones of the basipterygoid region are fused together, and the extraordinary shape of the skull makes them of little importance for our present purpose. It may be noticed, however, that the parasphenoid is represented by a vertical plate whose split upper edge clasps the lower margin of the ethmoid, and that the epipterygoid is a very slender rod.

In the Therocephalia, represented by the genus Lycosaurus, we have a type displaying many of the characteristic advances in the basipterygoid region which occur in all known South African Therapsids. In this type the basipterygoid processes, instead of being provided with definite articulating surfaces on their distal ends, are directed horizontally and transformed into flattened plates.

The triradiate pterygoids are rigidly articulated with the lower surface of these peculiar basipterygoid processes covering them almost entirely.

The posterior ramus of the pterygoid is reduced to a slender trihedral bar, which has its normal relations to the much reduced quadrate.

Cephalad of the basipterygoid articulations the pterygoids are separated by a narrow interpterygoid vacuity and then meet in a median suture. Their anterior rami run forward to the prevomers and are separated from one another by a long narrow bone, which appears, on comparison with the Anomodonts, to be certainly the anterior end of the parasphenoid.

The epipterygoid is a narrow but laterally flattened rod, which articulates with the outer end and apparently to some extent with the upper side of the flat basipterygoid process; behind this it is in contact with the upper surface of the posterior ramus of the pterygoid.

The curiously modified group of the Anomodontia are of interest in the present connection, because their structure throws light on the interpretation of the palate of Lycosaurus.

As shown extremely well in Prof. and Miss SOLLAS' "Platten model" of the skull of Dicynodon and in a disarticulated skull of Endothiodon in the British Museum (Natural History), the basipterygoids form small lappets projecting laterally at the anterior end of the basisphenoid. The whole of their lower surface across the middle line is rough and jagged, and has a sutural connection with the pterygoids. The parasphenoid forms a long, laterally compressed plate, whose grooved upper surface in the Dicynodon skull receives the lower border of the ethmoid and is itself received in a groove on the upper surface of the fused prevomers.

Prof. and Miss SOLLAS regard this parasphenoid as part of the basisphenoid, but BROOM has recently found a specimen in which it is separated by clear suture. The pterygoids fuse together below the basipterygoid region and are rigidly connected with the basisphenoid.

The posterior rami (in other specimens) are thin rods running back to the quadrate, with which they have a normal relation.

The anterior rami of the pterygoids are separated by an interpterygoid vacuity of moderate size, the extreme anterior border of which is, in the two specimens mentioned, formed by the prevomers.

The prevomers are fused, but they have otherwise all the relations of the prevomers of Lycosaurus. They articulate with the palatal process of the premaxilla, separating the anterior nares; posteriorly they articulate with the anterior ends of the pterygoids and laterally with the palatines. In both types they clasp the lower edge and anterior end of a median bone, which in the Anomodont is definitely known to be the parasphenoid; the difference is that in the Therocephalian the bone is exposed in the palate, whereas in the Anomodonts it lies slightly higher in the skull, but it is not one of much importance. The only other difference, the fact that in Lycosaurus the pterygoids meet in median suture in advance of the interpterygoid vacuity, whilst they do not in Endothiodon, is simply due to the extraordinarily short distance between the posterior nares and the basipterygoid process in the latter type.

The epipterygoid in Anomodonts is a slender rod rising from the pterygoid articulation to the parietal. Its lower end lies on the outer and upper surface of the pterygoid, and sends a process backwards along the outer and upper side of the posterior ramus of the pterygoid; the length of this process is very variable in different forms, in some it may very nearly reach the quadrate. The suture below this part of the epipterygoid is that found by Prof. and Miss SOLLAS in their Dicynodon skull (p. 219, *loc. cit.*).

The Gorgonopsids are almost certainly in the line of descent of the Cynognathids, to which they gradually approximate. Unfortunately, the structure of the anterior part of the palate is still not certainly known in any type.

The basipterygoid processes are quite similar to those of Lycosaurus, being in all known cases thin, horizontally and laterally directed flanges from the sides of the anterior part of the basisphenoid. In one case the base of the process is pierced by a "Vidian" foramen, which is certainly not present in other forms.

The pterygoid covers the greater part of the lower surface of the basipterygoid process, extending inwards to the thin ridge in the middle line of the basisphenoid. The posterior ramus runs backwards and passes behind the quadrate in the usual way; it is a slender bar. In front of the basipterygoid articulations the two pterygoids and the parasphenoidal rostrum of the basi cranii run forward, forming a compact rod. At the anterior end of this the pterygoids separate, leaving a minute interpterygoid vacuity, to form the powerful external rami which, with the ectopterygoid, form a flange against the inner side of the lower jaw. The Gorgonopsids show the beginning of the formation of a secondary palate by the raising of the middle part of the palate and approximation of the lower margins of the maxillæ.

The epipterygoids of Gorgonopsids are not very completely shown; they articulate with the upper edge of the pterygoid and with the end of the basipterygoid process, There is a long process, passing back nearly to the quadrate along the upper side of the posterior ramus of the pterygoid.

The Cynognathid skull is now completely known. The basipterygoid processes are still horizontally directed flanges, but are somewhat modified by the development of a process backward from the posterior and outer corners.

The pterygoids articulate with their lower surface, covering nearly the whole of it, in front extending inwards to the thin ridge of parasphenoid. There is no posterior ramus of the pterygoid, which terminates behind at the level of the back of the basipterygoid process. The pterygoids run forward, separated from one another throughout their whole length by a median bone. In front they articulate with the jugal, the very small ectopterygoid, and the palatinus. There is a secondary palate, formed in a thoroughly mammalian way, by plates from the maxillæ and palatines.

The whole middle part of the palate behind the posterior nares is formed by a median bone having all the relations, not only to the bones of the palate but also to the ethmoid, of a mammalian vomer. It is shown in many specimens to be directly continuous with the anterior end of the basisphenoid, separating the pterygoids for their whole length. In all its relations it agrees exactly with the median bone of the palate of Lycosaurus, in its relation to the ethmoid and basisphenoid with the undoubted parasphenoid of the Anomodonts. Its posterior portion is obviously identical with the undoubted parasphenoid of Gorgonopsids.

The epipterygoid of Cynognathids is a remarkable bone forming a thin plate on the side wall of the brain cavity, having a suture with the parietal bone above and overlapping the anterior superior process of prootic behind. It has an articulation with the outer end and to some extent with the lower surface of the basipterygoid process, articulating with the pterygoid in a long suture in this region. It sends back a posterior process occupying the position of a quadrate ramus of the pterygoid, which reaches to the quadrate, but passes in front and outside of that bone. This arrangement is derived from that of Gorgonopsids by the complete reduction of the small posterior ramus of the pterygoid and the concomitant enlargement of the posterior process of the epipterygoid. The posterior ramus of the epipterygoid is connected with the prootic by a special process of that bone lying between the groove for the vena capitis lateralis and the foramen pro nervo VII and also by that lamina covering the venous groove, which, in a previous part of this paper, I have shown to be homologous with the crista prootica of a lizard's skull.

As Prof. GAUPP has used the course of the nervus palatinus (VII) as a criterion of the homology of the mammalian pterygoid it is of importance to try and discover its course in Cynognathids.

In Varanus this nerve, issuing from the external opening of the facial foramen, runs forward under the crista prootica and passes through the "Vidian" foramen in the basipterygoid process to reach the dorsal surface of the pterygoid, along which it runs to the nasal cavity.

GAUPP has shown that this foramen really lies between the basisphenoid and the parasphenoid, so that the course of the nerve is ventral to the cartilaginous basipterygoid process.

In the single known Gorgonopsid in which there is a foramen through the basipterygoid process, the ramus palatinus nervus facialis no doubt runs through it and has a course just as in a lizard. In all other known South African Therapsids its course must be different. As Diamemodon (a Cynognathid) is a terminal type and very well known I shall consider the conditions in this genus.

As there is no "Vidian" foramen present the nerve must have passed either completely dorsal or completely ventral to the basipterygoid process.* So far as I know there is no case of the nerve passing dorsal to the basipterygoid, so that it seems certain that it actually passed ventral to it.

As the whole width of the under surface of the pterygoid process is covered by the pterygoid, leaving no opening between the two, it follows that the nerve must have passed ventral to that bone. Now in all Cynognathids there is a small but well defined groove on the under surface of the pterygoid, whose inner wall is formed by the parasphenoid. This groove runs forward from the basipterygoid region, to pass on to the ventral surface of the ptergoid medial to the great flange against the inner side of the lower jaw. The pterygoid in this region is pierced by a small foramen. I think that it is probable that the palatine branch of the seventh nerve passed along the groove and through the foramen just described, finally running forward on the dorsal surface of the pterygoid in the usual way.

(B.) When comparing together the skulls of Cynognathids and other Therapsids and those of Mammals, particularly the Monotremes, it is essential to have always in mind the great difference in the shape of the skulls. All Therapsids are very tropibasic, whilst the Monotremes represent an extreme of platybasy.

GAUPP has brought forward much evidence to show that the ala temporalis of a mammal is homologous with the basipterygoid process of a reptile, and the fundamental truth of this view cannot be doubted. It has been shown by WINCZA for the cat, dog, and bear; by LEVI, GAUPP, and FAWCETT for man; by NOORDENBOOS for the mole; and by BROOM for Trichosurus, that the extremity of the ala temporalis is distinct from the processus alaris, chondrifying separately according to the last three authors. M. VOIT has pointed out that the constancy of this division implies that the ala temporalis is compound, consisting of a processus alaris and the true ala temporalis articulated with its distal end.

The nature of GAUPP'S evidence is such that it is incapable of deciding whether the processus alaris alone, or the ala temporalis alone, or both together, are homologous with the reptilian basipterygoid process. Judging from the mode of development of the basipterygoid process in Sphenodon, it seems to me probable that the processus

---

* The peculiar cancellous structure of the basipterygoid process of Diademodon may in section present a quite illusionary resemblance to a foramen.

alaris alone really represents the processus basipterygoideus of reptiles. Broom has pointed out the remarkable similarity between the separate anlage of the ala temporalis in Trichosurus and that of the palatoquadrate cartilage of a lizard, especially Chameleo, and, so far as I know, no decisive evidence against the view that they are homologous has ever been brought forward.

The pterygoid of Ornithorhynchus as it exists in the stage of the pouch-young β has been described above. It lies on the ventral surface of the basis cranii, its posterior end being applied to the inner side of the ala temporalis. The edge of the bone has a long suture with the lateral border of the vomer. The pterygoid forms much of the roof and side walls of the ductus nasopharyngeus, and its lower edge is in contact with the palatine, which forms the floor of that canal. The posterior end is in connection with the Echidna pterygoid.

If this condition is compared with that in a Cynognathid, it will be seen that the undoubted reptilian pterygoid of that type is extremely similar in its relations to the surrounding bones. It covers the ventral surface of the basipterygoid process, has a long suture with the lateral edge of the median vomer, forms much of the roof and side wall of the posterior end of the ductus nasopharyngeus, is in contact with the palatine laterally and the epipterygoid posteriorly.

The chief difference is that in the reptile the palatine does not extend so far back; as it is known from palæontological evidence in Therapsids (and crocodiles) and from developmental evidence in mammals that the secondary palate closes from before backwards, and as the posterior nares in both monotremes have an extreme caudal position, which is almost certainly due to their (primarily ant-eating?) habits, this difference is really one of no importance.

If the course of the palatine branch of the seventh nerve in Diademodon which I have arrived at above be a true one, then we have a very remarkable resemblance between that type and Echidna, in which the nerve runs along the ventral surface of the posterior part of the bone and then passes through a foramen to its dorsal surface.

The superficial differences between the pterygoids of the two types are all simply due to the extreme distinction of shape of their skulls, one a small-brained type with a very tropibasic skull, the other a very large-brained type with a platybasic skull.

From these resemblances I am driven to conclude that the pterygoid of monotremes, originally discovered by Gaupp, and which he has shown to be homologous with the mammalian pterygoid, is actually the homologue of the reptilian pterygoid.

If I understand his position rightly, Gaupp founds his objection to recognising in the mammalian pterygoid the true descendant of that of reptiles on the following two facts:—

1. That the reptilian pterygoid is developed in connection with the pars palatina of the palato-quadrate cartilage, whilst the mammalian pterygoid constantly lies on the base of the neural skull.

2. That if the mammalian pterygoid is really homologous with the reptilian pterygoid, then it is necessary to find a new homology for the Echidna pterygoid. If that bone be the ectopterygoid (an obvious first idea), then it must have changed its position enormously.

Neither of these objections is a very powerful one. If BROOM'S idea that the independently developed exterior part of the ala temporalis is homologous with the pars palatina of the palato-quadrate cartilage is correct, and no evidence has been brought forward against this view, then the pterygoid of Ornithorhynchus develops in close proximity to the palato-quadrate cartilage, as it should do. Even if this view be not upheld by further discussion, we have the fact which I have pointed out above, that in all the advanced Therapsids of South Africa, which we know, as surely as we know anything in phylogeny, to be related to the ancestor of the mammals, the pterygoids invariably cover the whole lower surface of the basipterygoid processes, which are, of course, part of the neural cranium. Even in the living Chelonia the pterygoids spread inwards under the lower surface of the basal plate.

The discovery of a new homology for the Echidna pterygoid presents no difficulty. The fact that, according to SCHULMANN, a rudimentary muscle connects the Echidna pterygoid of Ornithorhynchus with the sphenoidal and petrosal region, shows, as GAUPP has pointed out, that the bone was originally free. It must therefore, from its general relations, be some bone belonging to the palato-quadrate series. If the mammalian pterygoid be really the true reptilian pterygoid, it must be either the ectopterygoid or the epipterygoid. GAUPP has shown that it is very improbable that it is the ectopterygoid.

In both monotremes the "Echidna pterygoid" develops as a membrane bone on the ventral surface of the ala temporalis: in stage β of Ornithorhynchus it does not extend at all lateral to this process. This fact affords some additional evidence that the independently developed part of the ala temporalis is really homologous with the pars palatina of the palato-quadrate of reptiles; for no one will deny that this bone belongs to the palato-quadrate series.

The sketch of the phylogenetic development of the epipterygoid of Therapsids, which I have given above, shows that throughout that group there is a constant tendency for a special process of the epipterygoid to be developed, which reaches back towards the quadrate region. In the most advanced group this process actually passes outside and in front of the quadrate, and the posterior ramus of the pterygoid has entirely disappeared, that bone lying entirely in front of the basipterygoid region. In the Cynognathids this part of the epipterygoid has the following relations:—It articulates with the outer side, and to a small extent with the lower surface of the basipterygoid process, having a suture with the pterygoid over this process. From here it extends backwards ventral to the exit of the fifth nerve, forming the front wall of the tympanic cavity, and articulates with the prootic by a special process dorsal (external) to the exit of the seventh nerve and ventral to the vena capitis lateralis, it touches the lower edge of the lamina which covers this vein.

The "Echidna pterygoid" in the adult skull of Echidna has the following relations :—

It articulates with the hinder edge and lower surface of the ala temporalis, has a suture with the hinder edge of the palatine, and with the hinder edge of the pterygoid. It lies ventral to the exit of the fifth nerve, and forms the front of the tympanic cavity. It articulates with the prootic part of the periotic ventral to the vena capitis lateralis; owing to the shape of the bone it is impossible to determine definitely whether the point of contact is dorsal or not to the exit of the seventh nerve, but the ramus palatinus passes mesial (*i.e.* ventral) to the bone.

It will be seen that, except for its connection with the palatine, the whole of the relations of the Echidna pterygoid in Echidna are those of the quadrate process of the epipterygoid in Cynognathids.

The connection between the Echidna pterygoid and the palatine seems to me to be certainly secondary, depending on the extreme caudal position of the posterior nares in both monotremes. Amongst terrestrial mammals this feature is only paralleled in such ant-eating types as Myrmecophaga, and it is certain that in ancestral mammals the secondary palate was far forward, as in Cynognathids.

These considerations seem to me to justify the identification of the pterygoid of monotremes with that of reptiles, and the "Echidna pterygoid" with the quadrate process of the epipterygoid of Cynognathids. This view implies that the whole dorsal part of the epipterygoid, that is the part corresponding to the lizard columella, has disappeared in monotremes.

In Cynognathids the epipterygoid forms the side wall of the anterior part of the cranial cavity, which is therefore not homologous with that of other reptiles but increased by the addition of epipterygoid cavities, analogous to but not completely homologous with those of mammals.

That this is actually so is shown by the position of the process which I have at various times described as a processus anterior inferior of the prootic in Therapsids. This process forms the lower border of the incisura prooticum, and in various species of the Cynognathid genus Diademodon varies very greatly in its development; in *D. browni* it is an extremely long spicule of bone running forward and upward, whilst in *D. entomophonous* it is a very short blunt process. It always lies medial to the epipterygoid, leaving a space in which the semilunar ganglion must have lain. It is, I think, permissible to compare it with the tænia clino-orbitalis of a monotreme, although, as it seems (in many cases, at any rate) to belong to the prootic, it can scarcely be strictly homologous with that element; it is, however, undoubtedly a relic of the original reptilian cranial wall.

The anterior superior process of the prootic of a Cynognathid, which passes inside the upper end of the epipterygoid, forms part of the side wall of the anterior part of the brain cavity, and it is easy to see how, by a great expansion of this process, we can arrive at the monotreme condition, where the whole side wall of the anterior part of the cranial cavity is formed by a homologous ossification in the membrana spheno-obturatoria, and the whole of the dorsal part of the epipterygoid has disappeared, leaving only its quadrate process.

(c.) To complete the discussion of the monotreme "pterygoids, "it remains to discuss their homologies with bones in the Therian skull.

GAUPP'S conclusion that the pterygoid of Echidna is homologous with the pterygoid of ordinary mammals seems to be a natural one, supported by sufficient evidence.

Comparison of the monotreme skull, as interpreted in the preceding parts of this paper, with that of a mammal shows that in the otic and sphenoidal regions the two agree bone for bone, except that in one case there is an "Echidna pterygoid" and no alisphenoid (for the small ala temporalis, ossified apparently by extension from the basisphenoid, can scarcely be called such), and in the other no Echidna pterygoid and an alisphenoid. This fact suggests a comparison of the Echidna pterygoid and the alisphenoid.

In the Marsupials and some Insectivora we find a special tympanic wing of the alisphenoid. As the Marsupials, whatever their exact origin, do retain in their adult structure and in their development many primitive features, and as the Insectivora are undoubtedly the most primitive living group of placental mammals, it is probable that this tympanic wing is really an essential part of the alisphenoid of early Theria. Little or nothing is known of its mode of development, but, judging from such marsupial embryos as I have examined, it is not preformed in cartilage, but must be entirely a membrane ossification.

This process has the following relations:—It rises from the body of the alisphenoid and passes backwards below the foramen for the exit of the mandibular division of the fifth nerve to form a variable amount of the front of the tympanic cavity. Its dorsal edge articulates with the tegmen tympani and its distal end with the tympanic bone. The Eustachian tube passes from the tympanic cavity in a notch between the tympanic wing of the alisphenoid and the basisphenoid, or petrosal. It will be seen that these dispositions are extremely similar to those of the Echidna pterygoid of Echidna, which passes out from the ala temporalis below the foramen for the exit of the mandibular division of the fifth nerve, forms part of the front wall of the tympanic cavity, articulates with the periotic and the tympanic, and has the Eustachian tube passing through a notch between it and basisphenoid. These relations are exactly those of the posterior process of the epipterygoid in Cynognathids.

Some years ago, before I was acquainted with the phylogenetic history of the epipterygoid region of the skull of Cynognathids, I was so impressed with the resemblance of the primitive part of the epipterygoid of Diademodon (which I then believed to belong to the pterygoid) to the body of the alisphenoid of Dasyurus that

I thought it probable that the first two divisions of the fifth nerve actually passed out in front of it as in mammals. Study of its history, which shows that it is undoubtedly homologous with the "columella" of lizards, renders this extremely unlikely, and I now find that there is a groove running forward on the outer side of the epipterygoid of Cynognathus from the front of the incipiently divided foramen between the prootic and epipterygoid, which can only be for the maxillary division of the fifth nerve.

This difference renders it probable that the vertical (cranial) part of the epipterygoid of the Cynognathids is not homologous with the vertical (cranial) part of the alisphenoid of mammals as BROOM and FUCHS believe, as it does not seem probable that the second division of the fifth nerve should change its relations to the bone in this way. It is therefore probable that the (vertical) cranial part of the alisphenoid is a new formation in mammals. This view is in agreement with that of M. VOIT, founded on other reasoning.

We may suggest that the history of the side wall of the cranial cavity in mammals is as follows :—

In some very remote ancestor the brain case essentially resembled that of the lizard. The prootic was provided with an incisura, through which the fifth nerve left the cranial cavity and the vena capitis lateralis entered it; immediately in front the cranial wall was partly cartilaginous, partly membranous, the fourth, third and second nerves leaving by a foramen. The anterior part of the brain was surrounded by a "sphenethmoid" ossification or by a pair of orbitosphenoids.

The semilunar ganglion lay outside the skull wall, its outer side being protected by the epipterygoid, the first branch of the fifth nerve passing in front of that bone, the other branches behind. The epipterygoid articulated with the end of the basipterygoid process, and the pterygoid with its lower surface, a feature the origin of which is obscure but is connected with that reduction of all parts of the skull which lie below the vestibule, which I have shown to be an important feature of South African Carnivorous Therapsids.

This condition brought the palato-quadrate cartilage into very close connection with the neural cranium. In subsequent stages the epipterygoid was widened so as to give more adequate protection to the Gasserian ganglion, and gradually acquired a posterior process which reinforced the much reduced posterior ramus of the pterygoid. It is probable that at this time the extreme reduction of the quadrate led to the separation of the pars palatina of the palato-quadrate cartilage from its posterior end (*cf.* Lacerta).

Concurrently with this widening of the epipterygoid an extension of the anterior corner of the prootic over the vena capitis lateralis took place, which finally reached and passed inside the upper end of the epipterygoid. Expansion of the brain practically crushed out of existence the original cranial wall, leaving only narrow rods to represent it. This is essentially the condition in Cynognathids.

Further enlargement of the processus anterior superior of the prootic led to the reduction of the epipterygoid, until finally the whole side wall of the cranium was formed by the prootic process which, as it started outside the vena capitis lateralis, necessarily grew down outside the mandibular division of the fifth nerve, and hence the semilunar ganglion, coming into connection with the crista prootica. In this stage the epipterygoid was only represented by its posterior ramus, and the palato-quadrate cartilage had lost all trace of its processus ascendens. The reduction of this process permitted the maxillary branch of the fifth nerve to assume an endocranial course. This is essentially the condition in Monotremes.

At this stage a new secondary upgrowth takes place from the rudiment of the pars palatina of the palato-quadrate cartilage, which has become very closely connected with the basipterygoid process of the basisphenoid as the ala temporalis. Ossification spreads into this cartilage from the Echidna pterygoid, the posterior process of the epipterygoid of the Cynognathids, and by its extension, both in the secondary cartilage and in the membrana spheno-obturatura, in which the anterior process of the prootic is also ossified, leads to the reduction of the latter until only its posterior and lower corner is left as the tegmen tympani, which, by subsequent enlargement of the brain, leading to the formation of a cavum supracochleare (M. VOIT), becomes part of the cranial wall. It is not inconceivable that the os intertemporale, occasionally found in man and other mammals, is really a remnant of the anterior part of the great anterior process of the prootic in Monotremes.

The relatively great importance of the cranial part of the alisphenoid over its tympanic wing leads, in accordance with the ordinary laws of acceleration in development, to its earlier ossification and to a chondrification of the pars perpendicularis of the ala temporalis at an earlier period than its phylogenetic age would justify.

IX. THE HOMOLOGY OF THE MAMMALIAN VOMER.

Another important problem of the mammalian skull on which the structure of that of Ornithorhynchus sheds light is the homology of the mammalian vomer. According to the old view, to which Prof. GAUPP subscribes, the mammalian vomer is homologous with the paired (pre)vomers of a reptile.

In such a reptile as Lacerta or Sphenodon the vomer is a bone which supports the inner side of the paraseptal cartilage and extends horizontally between that cartilage and the mouth. To convert such a vomer into that of a mammal it is necessary to assume that the following changes have taken place :—

The horizontal parts of the vomer gradually disappear, and the vertical parts, primitively developed in association with the paraseptal cartilages, have fused medially and grown back along the lower border of the nasal septum into the orbitotemporal region ; concurrently the large parasphenoid of the reptiles must have degenerated, as GAUPP suggests, "durch die vollständigere

Verknocherung des primodialen Craniums am Boden der Orbitotemporalisregion bei den Säugern."

At the same time special palatine processes of the premaxilla grow backward below and on the inner side of the paraseptal cartilages.

Such a series of changes is not absolutely unparalleled, and that its most essential part, the freeing of the vomers from the paraseptals and their association with the septum nasi, is possible is shown by the mode of development of the vomer in Emys and Crocodiles.

In the former case (*vide* KUNKEL, figs. 9 and 10) the two vomers, which arise independently, soon fuse, the lateral sides of the extreme anterior end of the resulting bone being applied to the inner surfaces of the much reduced paraseptal cartilages. The greater part of the bone, however, merely forms a sheath for the lower edge of the nasal septum.

In Crocodilus (SHIINO, figs. 11, 12, 13, 20, 21, and 22) the vomer is a small splint in the fenestra basalis of the nasal capsule, which in later stages (fig. 22) has a connection with the inner surface of that extreme posterior end of the uprolled inner edge of the solum nasi which corresponds to the paraseptal cartilage of other types. The more posterior part of the bone lies parallel to the lower edge of the septum nasi in such a way that it might hypothetically be expected to fuse with its fellow to form a bone similar to the mammalian vomer.

These two cases show that it is not impossible for the paired vomers of a reptile to a great extent to lose their primitive connection with the paraseptal cartilages and form a sheath to the lower edge of the nasal septum. At the same time the process is not really similar to that which must have occurred in mammalian ancestors, if the view that the mammalian vomer is the homologue of that of the reptiles be correct, because in each case it is associated with a very great reduction of the paraseptal cartilages and of Jacobsen's organ. Judging from the large size of the paraseptal cartilages in Monotremes, Marsupials, and Insectivora, this region was well developed in ancestral mammals.

This view of the mode of development of the mammalian vomer is supported by the fact that in Echidna and Mus (GAUPP) and the Guinea-pig (PARKER) the mammalian vomer is developed as a paired bone.

The alternative view of the homology of the mammalian vomer is that of BLAND-SUTTON as developed by BROOM. According to this theory the mammalian vomer is not homologous with the prevomers of reptiles, but is developed from the reptilian parasphenoid.

In specimen β of Ornithorhynchus the paraseptal cartilages are well developed, as shown in the model which Prof. WILSON has already described. The shape and relations of the two splints which support them and which by their fusion form the dumb-bell-shaped bone are adequately expressed by the following quotation from Prof. GAUPP, "Entsteht in der Umbegung der Cart. paraseptalis, diekt mit seiner

Pars ascendens die mediale Seite derselben und liegt mit seiner Pars horizontalis unter der Mundschleimhaut. Bei manchen Saurien verwachsen die beidenseitigen," which originally described the vomers of a lizard.

It is difficult to believe that elements in different animals whose origin and relations can be adequately described by the same words are not homologous.

If the os paradoxum is the homologue of the reptilian (pre)vomers, then the mammalian vomer is something else.

Prof. WILSON has shown that the os paradoxum of Ornithorhynchus co-exists with actual palatine processes of the premaxillæ, so that it cannot be claimed as merely a detached portion of that bone.

The vomer in my two young Ornithorhynchi shows no trace of a paired origin, it is a membrane bone stretching along the under surface of the septum nasi and of the basis cranii in the orbitotemporal region, terminating just in front of the pituitary. In neither stage has it any connection with the paraseptal cartilages, only reaching as far forward as their posterior end. That this element does present a striking resemblance, real or apparent, to the unpaired rostral portion of the parasphenoid of a lizard cannot be denied, a fact which renders extremely improbable GAUPP'S explanation of the loss of the rostral part of the parasphenoid in mammals as due to the complete ossification of the base of the orbitotemporal region; for if this explanation were true we should not expect another precisely similar splint bone to be developed in face of the very factors which are supposed to have led to its disappearance.

These facts seem to me to establish a case, too strong to be lightly set aside, for the homology of the os paradoxum with the reptilian prevomers and of the mammalian vomer with the rostral part of the parasphenoid of reptiles.

The most serious objections to homologising the mammalian vomer with the reptilian parasphenoid are:—

(1) The paired origin of the bone in several types. The rostral part of the parasphenoid in reptiles seems to be always unpaired (Sphenodon, Lacerta, Crocodiles, and Emys).

(2) The occurrence, recorded by FUCHS, of a small median membrane bone on the base of the skull, below the pituitary in Didelphis. The shape of this bone is not very completely described, and it is not improbable that it may really only be a detached part of the vomer.

The most trenchant objection to the old view of the mammalian vomer lies in the os paradoxum of Ornithorhynchus. If the relations of a membrane bone to the chondrocranium mean anything in morphology, this bone is the fused prevomers. It is quite independent of the vomer, which hence cannot be homologous with the prevomers.

On the other hand the relations of the anterior part of the vomer in embryo mammals lend little support to the view that it really represents the reptilian (pre)vomers.

In Macropus and Dasyurus the paraseptal cartilages are long, extending back mesial of the fenestra basalis of the nasal capsule to the lamina transversalis, which they join. Their inner sides and a good deal of the anterior part of their lower surfaces are covered by the palatine processes of the premaxillæ, which have exactly similar relations to them to those between the os paradoxum or the prevomers and the paraseptal cartilages in Ornithorhynchus and Lacerta respectively. The vomer in Macropus and Dasyurus is a splint on the lower edge of the nasal septum, whose anterior end is expanded and passes under the lower surface of the extreme posterior end of the paraseptal cartilages. This relation is scarcely that which would be expected if the vomer be formed by the fused perpendicular parts of the reptilian vomers, and appears to be more probably a secondary association.

The exact similarity between the palatine processes of the premaxillæ in all mammals and the os paradoxum in Ornithorhynchus, suggests that these processes are really independent in origin and have secondarily fused with the premaxillæ. This view is supported by the common occurrence reported by W. K. PARKER of "anterior paired vomers" in many mammals, not one of which, strangely enough, seems to have been investigated by modern methods.

Comparison of these two series of arguments seems to me to show that BROOM'S view is most probably correct, but that the embryological evidence at present available is scarcely sufficient finally to settle the point at issue.

The conditions found by FAWCETT in Man have an important bearing on the vomer problem. This author finds that the processus palatinus of the premaxilla has an independent origin, arising in the connective tissue between the parachordal cartilages in the region of Stenson's ducts. They thus agree in origin with W. K. PARKER'S anterior paired vomers, with the os paradoxum of Ornithorhynchus, and with the reptilian prevomers.

FAWCETT finds that the vomer in man is paired, arising at the lower part of the septum nasi a little distance behind and in a plane mesial to the paraseptal cartilages. These centres spread forward into the region of the paraseptal cartilages and backwards along the septum, their upper parts being largely ossified in the connective tissue which apparently represents the middle part of such a paraseptal cartilage as that of Macropus. The anterior end of the vomer reaches the paraseptal cartilages, which ossify and from which special membrane bones spread downwards, subsequently fusing with the vomer.

The whole series of conditions is very difficult to explain on either theory of the mammalian vomer, but seems to suggest, merely as a plausible hypothesis, that both the premaxilla and the vomer contain portions of the prevomers, represented by the palatal processus in one and the special antero-lateral plates in the other bone.

It is becoming more and more evident that morphological questions can only be settled by a comparison of palæontological and embryological facts: the former giving us in a broken and incomplete form the actual stages by which changes have been brought about, the latter, owing to tachygenesis, an equally broken and incomplete history of these changes.

The palæontological evidence so far as it concerns the origin of the undoubtedly mammalian vomer of Cynognathids, has already been given in this paper. It is certain that when we have a complete knowledge of the Gorgonopsid palate, even in any one type, the whole problem will be solved. At present the evidence may be summarised as follows:—

Primitive Therapsids have typical reptilian prevomers and a large parasphenoid (Varanosaurus, Dimetrodon, Deinocephalia). Later types, such as the Anomodonts, retain a large parasphenoid and large prevomers, which, in the group named, have fused together and actually support the nasal septum (SOLLAS), forming a bone extremely similar to the os paradoxum of Ornithorhynchus.

In the "Therocephalian" Lycosaurus there is a large parasphenoid appearing on the palate in the exact region occupied by the mammalian vomer of Cynognathids and large prevomers, occupying a position in respect to the dentigerous portion of the premaxillæ and to the anterior end of the parasphenoid which is exactly similar to that held by the palatine processes to the rest of the premaxillæ and the vomer in many mammals, *e.g.* Dasyrus and Macropus.

In Cynognathids there is a bone agreeing exactly with the mammalian vomer in its anterior end, which posteriorly joins the basisphenoid and has exactly the relations of the undoubted parasphenoid of the lower Therapsids.

The absence of knowledge of the anterior part of the palate in Gorgonopsids leaves an important gap in this series, for the resemblance of the palatally exposed lower edge of the parasphenoid in Lycosaurus to the vomer in Cynognathids, although it is, I think, sufficient when taken with other facts to support their complete homology, may not be convincing to every one.

In any case, the certain persistence of a large parasphenoid in so many groups of Therapsids, and its probable occurrence in all, renders it very improbable that the bone should have completely disappeared in mammals.

The whole of this evidence taken together seems to me to support BROOM'S view of the homology of the mammalian vomer, although it is not yet quite conclusive. In any case, until the whole problem is finally settled one way or another, it is essential for clearness of thought and statement to use BROOM'S term "prevomer" for the reptilian vomer and all bones definitely known to be homologous with it.

X. THE MAMMALIAN OSSICULA AUDITUS.

Another of the great morphological problems of the mammalian skull on which the development of that of Ornithorhynchus might be expected to throw light is the mode of origin of the ossicula auditus.

The mode of development of these bones is typically mammalian, and I have been unable to recognise any characters which can be held to be more primitive than those occurring in other young mammals ; in fact the whole structure seems to be distinctly more modified than it is in Perameles.

The evidence which GAUPP has brought forward, and which he has so ably and so lengthily stated, seems to prove quite conclusively that the incus equals the quadrate, the malleus the articulare, the processus folianus (GONIALE) the prearticular of reptiles. The exact resemblance that Mr. PALMER has shown to exist between the tympanic in a mammary fœtus of Perameles and the angulare of a Cynognathid seem to establish the homology of these two bones.

The ossiculus acessorium malleoli of a sheep and of Xenartha has a characteristic relation to the upper limb of the tympanic and to the posterior part of Meckel's cartilage. It seems, therefore, to be a bone of the reptilian lower jaw, and it is not improbable that it is really the surangular.

XI. THE NATURAL RELATIONSHIPS OF THE MONOTREMES.

The new knowledge of the structure of the monotreme skull which is given in this paper makes it possible to estimate with greater ease and certainty the natural relationships of the monotremes.

The chondrocrania of Platypus and Echidna are very similiar, and this similarity is most striking in the most specialised region of the skull, the snout. This region in the chondrocranium is characterised by the crista marginalis of the solum nasi, a cartilaginous sheet on to the upper surface of which the septomaxilla is grafted, the premaxilla having a similar relation to its inferior face.

In Ornithorhynchus this cartilage persists in a much enlarged form as the skeleton of the lateral part of the "beak," in Echidna it is lost. As no similar structure is known in either reptiles or other mammals it must be a special feature developed by some common ancestor of the two monotremes. It is probably connected with the specialisation of the anterior part of the face into the great tactile sense organ which it is in both living monotremes, and this modification itself is certainly associated with some special (probably primarily insectivorous) diet. This curious similarity suggests that the distinction between the two families is not one of any great age.

Our new knowledge of the skull shows that the Monotremes differ from the Theria much more widely than has hitherto been supposed. The absence of the alisphenoid as an important bone in the side wall of the cranial cavity is a very remarkable difference, which alone makes the monotreme skull differ far more greatly from that of any Therian than the members of the latter group do amongst themselves. This difference is, however, as I have already shown, one that is not inconsistent with a close relationship, as the monotreme condition may be, and quite possibly is, a stage in the development of the characteristic mammalian skull from that of a Therapsid reptile.

The most interesting result of the present work is that it is now possible satisfactorily to compare the monotreme skull with that of a Cynognathid, and that such a comparison establishes the fact that many of the most remarkable and unexpected features of the monotreme skull are merely extreme developments of features already found in the latter group. Such a comparison shows how, by the mere expansion of the brain, the auditory capsule, lying between it and the fixed point formed by the articulation between the dentery and the squamosal which is already predicted in Cynognathids, is as it were crushed, the long paroccipital process of the opisthotic and prootic of Therapsids being reduced to the small paroccipital process (ossified crista parotica), the incus which primitively lies outside it being drawn within its outer end, a process the end stages of which may be followed in my two Ornithorhynchus young.

The whole comparison shows that the monotremes are not to be regarded as representatives of a separate stock distinct from that which gave rise to the Theria, but merely as the much specialised descendants of very early (probably only just post-Therapsid) mammals.

General Summary of Results.

1. The *chondrocranium* of Ornithorhynchus is typically mammalian and much resembles that of Echidna.

2. The *planum basale* is broad, not being narrowed by the convergence of the cochleæ.

3. The cavity of the *otic capsule* is of very primitive form, agreeing in all its features with that of the Cynognathid Diademodon. The only openings into it are, the internal auditory meatus, the ductus endolymphaticus, and the fenestræ ovalis et cochleæ.

4. The *facial canal* is identical with that of a reptile in its course.

5. The basal plate in the *orbitotemporal* region is broad and pierced by foramina for the internal carotid arteries.

6. The *ala temporalis* is very short, being completely devoid of any processus ascendens, and is traversed by a canal for a branch of the external carotid artery.

7. The primitive side wall of the reptilian skull is represented by the tænia clino-orbitalis and by a cartilaginous process projecting up from the pars cochlearis of the otic capsule.

8. There is no definite *lamina transversalis posterior*, the ventral surface of the basis cranii passing gradually into the nasal cavity.

9. There are small and distinct *ethmo- and maxillo-turbinals* in the younger fœtus.

10. The stapes is imperforate and in imperfect cartilaginous connection with the incus

11. The *incus* is a flattened nodule in cartilaginous connection with the crista parotica.

12. The *malleus* is in no way marked off from Meckel's cartilage, and is provided with a large manubrium. It is in cartilaginous connection with the incus.

13. Reichert's cartilage is in full cartilaginous connection with the crista parotica.

14. The basi-occipital, exoccipital, supra-occipital are cartilage bones of the ordinary type.

15. The ala temporalis, at any rate for the greater part of its structure, is ossified by extension from the basisphenoid.

16. The otic capsule in the older "embryo" has two ossifications: one, surrounding the fenestra rotunda and the posterior vertical semicircular canal, agrees exactly with the reptilian paroccipital (opisthotic). The other consists of a cartilage ossification, with a perichondral and membrane ossification in complete continuity with it. This ossification surrounds the facial foramen, the vestibule in front of the fenestra vestibuli, and the upper and anterior part of the pars cochlearis. The membranous part of the ossification passes backwards to the processus perioticus superior outside the seventh nerve and the vena capitis lateralis; it extends forward into the membrana spheno-obturatoria.

17. The periotic of Echidna is shown to agree with that of Ornithorhynchus in having connected with it an ossification which grows forward in the membrana spheno-obturatoria. It is shown that all regions in the periotics of the two types can be definitely homologised.

18. The anterior ossification of the otic capsule of Ornithorhynchus is shown to agree with the prootic of reptiles, and the lower part of its membranous portion is homologous with the crista prootica of a lizard.

19. The development in phylogeny of the otic region of the Therapsids is sketched, and the gradual production of a long "anterior superior process" is described. The fate of the crista prootica in this group is also discussed.

20. The anterior superior process of the prootic of a Cynognathid is homologised with the upper part of the membranous part of the prootic ossification in monotremes.

21. It is shown that the mode of ossification of the periotic of a Therian mammal differs very widely from that of Ornithorhynchus.

22. The tegmen tympani is homologised with the lower part of the membranous part of the prootic in Monotremes.

23. A sketch of the phylogenetic development of the Cynognathid palate and epipterygoid are given. The important features are:—

(i) The articulation of the pterygoids with the *lower surface* of the basipterygoid processes, which they completely cover in the later forms.

(ii) The development of a posterior process from the epipterygoid, which in later types reaches back to pass in front of the quadrate.

(iii) The complete loss of the quadrate ramus of the pterygoid in the later forms.

24. Ornithorhynchus is shown to agree with Echidna in having a "mammalian" and an "Echidna" pterygoid.

25. Many facts combine to show that the external part of the ala temporalis which arises independently in many mammals is homologous with the pars palatina of the palato-quadrate cartilage.

26. The mammalian pterygoid of Monotremes is shown to arise on the skull base in close connection with the short ala temporalis. Comparison with Therapsids, in which the pterygoid lies in contact with the lower surface of the basipterygoid process, shows that this origin is no bar to its homology with the reptilian pterygoid.

27. Comparison of the relations of the mammalian pterygoid of Ornithorhynchus with those of the Cynognathid pterygoid shows that it is the real reptilian pterygoid.

28. The homology of the mammalian pterygoid with that of reptiles being established, it is necessary to find a new homologue for the Echidna pterygoid.

29. The presence of a rudimentary muscle connecting the Echidna pterygoid to the neural cranium shows that that bone was formerly movable. Its general relations show that it belongs to the palato-quadrate series. Its origin on the lower surface of the ala temporalis lends additional support to the view that the outer part of that process is a remnant of the palato-quadrate cartilage, as BROOM has suggested.

30. The only two possible bones in the reptilian skull with which the Echidna pterygoid could correspond are the ectopterygoid and the epipterygoid. Its position renders the first impossible.

31. The Echidna pterygoid of Echidna is compared with the posterior process of the epipterygoid of a Cynognathid, and shown to agree exactly with it.

32. The occurrence of a tympanic wing of the alisphenoid in Marsupials and in some Insectivora shows that that process is an essential feature of the primitive mammalian bone.

33. The tympanic wing of the alisphenoid in Marsupials is compared with the "Echidna pterygoid" of Echidna and the posterior ramus of the epipterygoid of Cynognathids and found to agree with them.

34. Accepting M. VOIT's view that the pars perpendicularis of the mammalian ala temporalis is a secondary upgrowth in the membrana spheno-obturatoria of Monotremes, it is found to be possible to give an account of the mode of origin of the side wall of the mammalian skull in the orbito-temporal region which is consistent with known palæontological and embryological data.

35. It is pointed out that the theory of the origin of the mammalian vomer from the fusion of the prevomers of a reptile and their subsequent growth backwards along the nasal septum is, to some extent, supported by the conditions of the prevomers in Emys and Crocodiles, but that as the approach to a mammalian condition seen in those reptiles is dependent on a great reduction of the paraseptal cartilages, the apparent resemblance to the mode of origin of the mammalian vomer is probably deceptive. This view of the origin of the mammalian vomer is also supported by the paired origin of that bone in many forms.

36. The os paradoxum of Ornithorhynchus in Embryo β is represented by a pair of bony splints having exactly the same relation to the paraseptal cartilages as the

prevomers of a lizard. This fact seems to demonstrate the strict homology of these two bones. As in this embryo (as Prof. WILSON has shown) a definite palatal process of the premaxilla is also present, these bones cannot be interpreted merely as parts of that bone.

37. The occurrence in Embryo β of Ornithorhynchus of a definite and large mammalian vomer having no connection with and lying in a different plane from that of the os paradoxum shows that this bone cannot be the fused prevomers.

38. The actual relation of the anterior end of the vomer in Macropus and Dasyurus to the paraseptal cartilage is not that which we should expect if that bone be really the fused prevomers, but appears to be a secondary one.

39. The vomer of Ornithorhynchus has a very similar position to the rostral part of the parasphenoid of reptiles, a fact which is inconsistent with GAUPP'S view that the crus longus of the parasphenoid has disappeared in mammals owing to the complete ossification of the base of the skull.

40. The occurrence of a large parasphenoid in all Therapsids in which the conditions are accurately known renders it very unlikely that this bone should have completely disappeared in mammals.

41. The development of the ossicula auditus in Ornithorhynchus adds nothing to the completeness of the case for REICHERT'S theory that GAUPP has recently summarised.

42. It is suggested that the ossiculus acessorium malleoli may be the reptilian surangular.

43. The very close agreement which is now shown to exist between the skulls, both cartilaginous and bony, of the two living Monotremes shows that these two rather divergent types are in reality very closely allied.

44. The whole structure of the Monotreme skull is best explained by regarding them as the relatively unaltered descendants of very early mammals from which the Theria sprung.

After this paper had been written in its present form, the Zoological Department of Sydney University found a very small male Ornithorhynchus in their stores. From this specimen they most kindly prepared a skull for my use. This skull shows all the sutures very clearly, and serves completely to justify the criticisms of VAN BEMMELEN'S account on p. 336 of this paper. The untouched photographs reproduced in Plate 3 will explain its structure better than any description.

The features of special importance are: the complete connection of the great ossification in the membrana obturatoria with the periotic. There is, as was to be expected from the conditions in Specimen β, no trace of any suture between the two regions. There is a closed suture below the lateral vascular foramen, which obviously marks the meeting point between the processus perioticus superior and the membrane ossification of the periotic. The suture between the lower edge of the ossification in the membrana spheno-obturatoria and the ala temporalis is quite clear although closed.

There is a very plain suture between the hinder part of the palatine and the lower edge of the ala temporalis. This lies entirely on the lower surface, in such a manner that the "Echidna pterygoid" is not in contact with the palatine at any point, but articulates solely with the outer side of the lower edge of the ala temporalis and probably with the pterygoid posteriorly. The anterior end of the pterygoid is quite distinct, being surrounded by open sutures.

Though fused to the basis cranii it is obvious that the vomer extends back on to the basi-occipital, because it crosses the open suture between that bone and the basisphenoid.

There is no trace of VAN BEMMELEN'S parietal laterale, the shape and relations of the occipital bones, the parietals, frontals, orbitosphenoids, and the hinder part of the nasal being exactly similar to those of the same bones in Echidna.

It remains only to acknowledge my indebtedness to those whose kindness has made this work possible to me. To a grant from the Commonwealth of Australia through the British Association I owe the possibility of visiting that continent. To Prof. J. T. WILSON I am indebted for the loan of the whole of his unique material of Ornithorhynchus, a piece of kindness which is the greater, in that he had already done much unpublished work on it, the notes of which he also placed at my disposal. I am indebted to him also for the use of the fine equipment and library of the Anatomical Department of Sydney University. I can only regret that his absence on the military service of the Commonwealth deprived me of much valuable advice and criticism.

Dr. S. A. SMITH, Acting Professor of Anatomy at Sydney, has helped me by his constant interest, and to Mr. LOUIS SCHAEFFER, Assistant in the Anatomical Department, I owe the beautiful photographs that illustrate this paper and much other assistance. I have also to thank for the loan of material and other help Mr. R. ETHERIDGE, Director of the Australian Museum, and Prof. W. A. HASWELL and Dr. S. J. JOHNSTON, of the Zoological Department of Sydney University

LIST OF WORKS CITED.

BARDEEN, C. R., 1912. In KEIBEL and MALL, 'Manual of Human Embryology,' vol. 2, Philadelphia.

VAN BEMMELEN, S. F., 1901. "Der Schädelbau der Monotremen," SEMON'S 'Zoolog. Forschungsreisen,' vol. 3, pp. 729–798, Taf. 30–32.

DE BLAINVILLE, 1816. "Prodrome d'une Nouvelle Distribution systématique du règne animal," 'Bull. de la Soc. Philom. pour l'année 1816,' p. 105.

BOAS, J. E. V., 1914. "Die Schläfenüberdachung und das Palato-quadratum in ihrem Verhältnis zum übrigen Schädel bei den Dipnoern und den terrestren Wirbeltieren," 'Morph. Jahrb.,' vol. 94, pp. 229–300.

BROMAN, IVAR, 1899. "Die Entwickelungsgeschichte der Gehörknöchelchen beim Menschen," 'Anat. Hefte,' vol. 11, Heft 4, pp. 507–670, 6 plates.

BROOM, R., 1895. "On the Homology of the Palatine Process of the Mammalian Præmaxillary," 'Proc. Linn. Soc. N.S.W.,' vol. 10.

Idem, 1895. "On some Developments of the Mammalian Prenasal Cartilage," 'Proc. Linn. Soc. N.S.W.,' vol. 10, pp. 555–562, 1 plate.

Idem, 1895. "On the Organ of Jacobson in an Australian Bat (Miniopterus)," 'Proc. Linn. Soc. N.S.W.,' vol. 10, pp. 571–575, 1 plate.

Idem, 1895. "On the Presence of a Pair of Apparently Distinct Prevomers in Gomphognathus," 'Journ. Anat. and Phys.,' vol. 31, pp. 277–279.

Idem, 1903. "On the Development of the Pterygo-quadrate Arch in the Lacertilia," 'Journ. Anat. and Phys.,' pp. 107–111.

Idem, 1903. "On the Structure of the Palate in the Primitive Theriodonts," 'Geol. Mag.,' ser. 4, vol. 10, pp. 343–344.

Idem, 1903. "On the Classification of Theriodonts and their Allies," 'Rep. S. Afr. Assoc. Adv. Sci.,' vol. 1.

Idem, 1904. "On the Structure of the Theriodont Mandible, and on its Mode of Articulation with the Skull," 'Proc. Zool. Soc.,' vol. 1, pp. 490–498 (1904).

Idem, 1905. "On Some Points in the Anatomy of the Theriodont Reptile Diademodon," 'Proc. Zool. Soc.,' vol. 1, pp. 96–102, Plate 10 (1905).

Idem, 1908. "On the Homology of the Mammalian Alisphenoid Bone," 'Rep. South African Ass. Adv. of Science,' 1907, pp. 114–115.

Idem, 1909. "Observations on the Development of the Marsupial Skull," 'Proc. Linn. Soc. N.S.W.,' vol. 34, pp. 195–214, 8 plates.

Idem, 1910. "A Comparison of the Permian Reptiles of North America with those of South Africa," 'Bull. Amer. Mus. Nat. Hist.,' vol. 24, pp. 197–234, 20 figs.

Idem, 1911. "On the Structure of the Skull in Cynodont Reptiles," 'Proc. Zool. Soc.,' vol. 2, p. 893 (1911).

BROOM, R., 1911. "On some new South African Permian Reptiles," 'Proc. Zool. Soc.,' vol. 2, p. 1073 (1911).

Idem, 1912. "On the Structure of the Internal Ear and the Relations of the Basicranial Nerves in Dicynodon, and on the Homology of the Mammalian Auditory Ossicles," 'Proc. Zool. Soc.,' vol. 1, pp. 419–425, 1 plate (1912).

Idem, 1913. "On the Gorgonopsia, a Suborder of the Mammal-like Reptiles." 'Proc. Zool. Soc.,' vol. 1, pp. 225–230, 2 plates (1913).

BRUNER, H. L., 1907. "On the Cephalic Veins and Sinuses of Reptiles, etc.," 'Amer. Journ. Anat.,' vol. 7, pp. 1–118, 3 plates.

CASE, E. C., 1907. "A Revision of the Pelycosauria of North America," 'Carnegie Institute of Washington Publications,' No. 55.

Idem, 1911. "Revision of the Cotylosauria of North America." 'Carnegie Inst. Pub.,' No. 145.

CORDS, E., 1909. "Die Entwickelung der Paukenhöhle von Lacerta agilis. Ein Beitrag zur Lehre vom Schalleitenden Apparat der Wirbeltiere," 'Anat. Hefte,' vol. 38, pp. 219–319, 2 plates.

FAWCETT, E., 1910. "Notes on the Development of the Human Sphenoid," 'Jour. Anat. and Phys.,' vol. 44, pp. 207–222.

Idem, 1911. "The Development of the Human Maxilla, Vomer and Paraseptal Cartilages," 'Jour. Anat. and Phys.,' vol. 45, pp. 378–405.

FISCHER, E., 1901. "Das Primordialcranium von Talpa europæa. Ein Beitrag zur Morphologie des Säugethierschädels," 'Anat. Hefte,' vol. 17, pp. 467–548, 6 plates.

FUCHS, H., 1905. "Bemerkungen über die Herkunft und Entwickelung der Gehörknöchelchen bei Kaninchen-Embryonen (nebst Bemerkungen über die Entwickelung des Knorpelskeletes der beiden ersten Visceralbogen)," 'Arch. für Anat. und Entwickel.,' Anat. Abltg. Supplement, pp. 1–178, 4 plates.

Idem, 1906. "Untersuchungen über die Entwickelung der Gehörknöchelchen, des Squamosums und des Kiefergelenkes der Säugethiere, nebst einigen vergleichendanatomischen Betrachtungen über Articulare, Quadratum und Gehörknöchelchen," 'Arch. für Anat. und Entwick.,' Anat. Abltg. Supplement, pp. 1–90, Plate 6.

Idem, 1909. "Über die Entwickelung einiger Deckknochen (Vomer, Pterygoid, Maxillare) bei Säugetieren (und ihr Verhältnis zum Knorpelskellette)," 'Verh. der Anat. Gesell. in Giessen,' pp. 85–102, 1 plate.

Idem, 1909. "Über Knorpelbildung in Deckknochen, nebst Untersuchungen und Betrachtungen über Gehörknöchelchen, Kiefer, und Kiefergelenk der Wirbeltiere," 'Arch. fur Anat. und Phys.,' Anat. Abltg., Supplement.

Idem, 1910. "Uber das Pterygoid, Palatinum und Parasphenoid der Quadrupeden, insbesondere der Reptilien und Säugetiere, nebst einigen Betrachtungen über die Beziehungen zwischen Nerven und Skeletteilen," 'Anat. Anz.,' vol. 36, pp. 33–95.

Idem, 1912. "Uber die Beziehungen zwischen den Theromorphen Copes, bzw. den Therapsiden Brooms, und den Säugetieren, erörtert auf Grund der Schädelverhältnisse (nebst einem weiteren Beitrag zur Frage der Homologie des Kiefergelenkes und der morphologischen Bedeutung des Squamosums)," 'Zeit. Morph. und Anthro.,' vol. 14, pp. 367–438.

GAUPP, E., 1900. "Das Chondrocranium von Lacerta agilis. Ein Beitrag zum Verständnis des Amniotenschädels," 'Anat. Hefte,' vol. 14, Part 3, pp. 433–595, 6 plates.

Idem, 1901. "Alte Probleme und neuere Arbeiten über den Wirbelthierschädel," 'Ergebnisse der Anat. und Entwick.,' vol. 10, pp. 847–1001.

Idem, 1902. "Über die Ala temporalis des Säugerschädels und die Regio orbitalis einiger anderer Wirbelthierschädel," 'Anat. Hefte,' vol. 19.

Idem, 1905 A. "Neue Deutungen auf dem Gebiete der Lehre vom Säugethierschädel," 'Anat. Anz.,' vol. 27, pp. 273–310.

Idem, 1905 B. "Die Nicht-Homologie des Unterkiefers in der Wirbeltierreihe," 'Verhand. der Anat. Gesell., Genf,' pp. 125–140.

Idem, 1905 C. "Die Entwickelung des Kopfskeletes," O. HERTWIG'S 'Handbuch der vergleichenden-Entwickelungslehre der Wirbeltiere,' vol. 3, Abt. 2.

Idem, 1906. "Über allgemeine und spezielle Fragen aus der Lehre vom Kopskelet der Wirbeltiere," 'Verh. der Anat. Gesell. Rostock,' pp. 21-68.

Idem, 1908. "Zur Entwickelungsgeschichte und vergleichenden Morphologie des Schädels von Echidna aculeata var. typica," 'Jenaische Denkschriften,' vol. 6, Teil 2, pp. 539–788, 8 plates.

Idem, 1910 A. "Erwiderung auf den Aufsatz von H. FUCHS: Über das Pterygoid, Palatinum und Parasphenoid der Quadrupeden, etc.," 'Anat. Anz.,' vol. 37, pp. 352–377.

Idem, 1910 B. "Säugerpterygoid und Echidnapterygoid, nebst Bemerkungen über das Säuger-Palatinum und den Processus basipterygoideus," 'Anat. Hefte,' vol. 42, pp. 311–431.

Idem, 1911 A. "Über den N. trochlearis der Urodelen und über die Austrittsstellen der Gehirnnerven aus dem Schädelraum in Allgemeinen," 'Anat. Anz.,' vol. 38, pp. 401–444.

Idem, 1911 B. "Beiträge zur Kenntnis des Unterkiefers der Wirbeltiere. I.—Der Processus anterior (Folii) des Hammers der Säuger und das Goniale der Nichtsäuger," 'Anat. Anz.,' vol. 39, pp. 97–135.

Idem, 1911 C. "Beiträge zur Kenntnis des Unterkiefers der Wirbeltiere. II.—Die Zusammensetzung des Unterkiefers der Quadrupeden," 'Anat. Anz.,' vol. 39, pp. 433–473.

Idem, 1911 D. "Beiträge zur Kenntnis des Unterkiefers der Wirbeltiere. III.—Das

Problem der Entstehung eines 'sekundären' Kiefergelenkes bei den Säugern," 'Anat. Anz.,' vol. 39, pp. 609–666.

GAUPP, E., 1913. "Die Reichertsche Theorie (Hammer-, Amboss- und Kieferfrage)", 'Arch. für Anat. u. Entwickel.,' Jahr. 1912, Supplement Bd., pp. xiii + 1–416.

GREGORY, W. K., 1910. "The Orders of Mammals," 'Bull. Amer. Mus. Nat. Hist.,' vol. 27, pp. 3–524.

Idem, 1913. "Critique of Recent Work on the Morphology of the Vertebrate Skull, Especially in Relation to the Origin of Mammals," 'Journ. of Morph.,' vol. 24, pp. 1–42.

GROSSER und BREZINA, 1895. "Ueber die Entwicklung der Venen des Kopfes und Halses der Reptilien," 'Morph. Jahrb.,' vol. 23.

v. HUENE, 1914. 'Bull. Amer. Mus. Nat. Hist.,' vol. 32, Art. 18, p. 359.

HOWES, G. B., and SWINNERTON, H. H., 1903. "On the Development of the Skeleton of the Tuatara, *Sphenodon punctatus*," 'Trans. Zool. Soc. London,' vol. 16, pp. 1–86, 6 plates.

KAMPEN, P. N. VAN, 1905. "Die Tympanalgegend des Säugetierschädels," 'Morph. Jahr.,' vol. 34, Heft 3, 4, pp. 321–722.

KUNKEL, B. W., 1912. "The Development of the Skull of *Emys lutaria*," 'Journ. of Morph.,' vol. 23, pp. 693–780, 6 plates.

LEVI, G., 1900. "Beitrag zum Studium der Entwickelung des Knorpeligen Primordialcraniums des Menschen," 'Arch. f. Mikro. Anat.,' vol. 55, p. 341.

MALL, F. P., 1904. "On the Development of the Blood Vessels of the Brain in the Human Embryo," 'Amer. Journ. Anat.,' vol. 4.

MEAD, C. S., 1909. "The Chondrocranium of an Embryo Pig, *Sus scrofa*. A Contribution to the Morphology of the Mammalian Skull," 'Amer. Journ. Anat.,' vol. 9, pp. 167–209, 4 plates.

NOORDENBOOS, W., 1905. "Über die Entwickelung des Chondrocraniums des Säugetiere," 'Petrus Camper,' Deil 3, pp. 367–430, 3 plates.

OLMSTEAD, M. P., 1911. "Das Primordialcranium eines Hunde-embryo. Ein Beitrag zur Morphologie des Säugetierschädels," 'Anat. Hefte,' vol. 43, Part 2, pp. 335–375, 9 plates.

OWEN, R. Art. "Monotremata" in TODD's 'Cyclopædia of Anatomy and Physiology,' vol. 3, 1839–1847, London.

PALMER, R. W., 1913. "Note on the Lower Jaw and Ear Ossicles of an Embryo Perameles," 'Anat. Anz.,' vol. 43, pp. 510–515.

PARKER, W. K., 1886. "On the Structure and Development of the Skull in the Mammalia. Part II.—Edentata. Part III.—Insectivora," 'Phil. Trans.,' vol. 176, pp. 1–275, 39 plates.

PARKER, W. N., 1894. "On some Points in the Structure of the Young of *Echidna aculeata*," 'Proc. Zool. Soc. London,' 1894.

SEELEY, H. G., 1894. "Researches on the Structure, Organisation, and Classification of the Fossil Reptilia.—Part IX, Sec. 3, On Diademodon," 'Phil. Trans.,' B, vol. 185 (1894), pp. 1029–1041, Plate 89.

Idem, 1895. "Researches, etc.—Part IX, Sec. 4, On the Gomphodontia," 'Phil. Trans.,' B, vol. 186 (1895), pp. 1–57, Plates 1, 2.

Idem, 1895. "Researches, etc.—Part IX, Sec. 5, On the Skeleton in New Cynodontia from the Karroo Rocks," 'Phil. Trans.,' B, vol. 186 (1895), pp. 59–148.

Idem, 1900. "On an Anomodont Reptile, *Aristodesmus Rütimeyeri* (Wiedersheim), from the Bunter Sandstone near Basel," 'Q.J.G.S.,' vol. 56, pp. 620–648.

SEYDEL, O., 1899. "Uber Entwickelungsvorgänge an der Nasenhöhle und am Mundhöhlendache von Echidna, nebst Beiträgen zur Morphologie des peripheren Geruchsorgans und des Gaumens der Wirbeltiere," 'Jenaische Denkschr.,' vol. 6, pp. 445–532.

SHIINO, K., 1912. "Beitrag zur Kenntnis der Gehirnnerven der Schildkröten," 'Anat. Hefte,' vol. 47, Hft. 1, pp. 1–34.

Idem, 1914. "Stüdien zur Kenntnis der Wirbeltierkopfes. 1. Das Chondrocranium von Crocodilus, mit Berücksichtigung der Gehirnnerven und der Kopfgefässe," 'Anat. Hefte,' vol. 50, pp. 253–383, 7 plates.

SOLLAS, I. B. J., and SOLLAS, W. J., 1914. "A Study of the Skull of a Dicynodon by means of Serial Sections," 'Phil. Trans.,' B., vol. 204, pp. 201–226, 2 plates.

SYMINGTON, J., 1891. "On the Nose, the Organ of Jacobson, and the Dumb-bell-shaped Bone in the Ornithorhynchus. 'Proc. Zool. Soc.,' pp. 575–584, 2 plates.

VERSLUYS, JAN, 1898. "Die mittlere und äussere Ohrsphäre der Lacertilia und Rhynchocephalia," 'Zool. Jahr., Abt. fur Anat. u. Ont.,' vol. 12, H. 2, pp. 161–406, 8 plates.

VOIT, MAX, 1909. "Das Primodialcranium des Kaninchens unter Berücksichtigung der Deckknochen. Ein Beitrag zur Morphologie der Säugetierschädels," 'Anat. Hefte,' vol. 38, pp. 425–616, 16 plates.

WATKINSON, G. B. "The Cranial Nerves of *Varanus bivittatus*," 'Morph. Jahr.,' vol. 35, pp. 450–472, 2 plates.

WATSON, D. M. S., 1911. "The Skull of Diademodon, with Notes on those of some other Cynodonts," 'Ann. and Mag. Nat. Hist.,' Ser. 8, vol. 8, pp. 293–330.

Idem, 1912. "The Larger Coal-Measure Amphibia," 'Manch. Mem.,' vol. 57, Part I, pp. 1–13, plate and figures.

Idem, 1913. "On some Features of the Structure of the Therocephalian Skull," 'Ann. and Mag. Nat. Hist.,' Ser. 8, vol. 11, pp. 65–79.

Idem, 1913. "Further Notes on the Skull, Brain, and Organs of Special Sense of Diademodon," 'Ann. and Mag. Nat. Hist.,' Ser. 8, vol. 12, pp. 217–228.

WATSON, D. M. S., 1914. "Notes on *Varanosaurus acutirostris*, Broili," 'Ann. and Mag. Nat. Hist.,' Ser. 8, vol. 13, pp. 297–310.

Idem, 1914. "On the Skull of a Pariasaurian Reptile, and on the Relationship of that Type," 'Proc. Zool. Soc.,' vol. 1, pp. 155–180 (1914).

Idem, 1914. "Notes on some Carnivorous Therapsids," 'Proc. Zool. Soc.,' 1914, pp. 1021–1038.

Idem, 1914. "The Deinocephalia, an Order of Mammal-like Reptiles," 'Proc. Zool. Soc.,' 1914, pp. 749–786, 2 plates.

WILLISTON, S. W. "North American Plesiosaurs," 'Pub. Field Columbia Museum,' Geol. Ser., vol. 2, pp. 1–77, 29 plates.

Idem, 1911. 'American Permian Vertebrates,' Chicago.

WILSON, J. T., and MARTIN, C. J., 1893. "Observations upon the Anatomy of the Muzzle of the Ornithorhynchus," 'Macleay Memorial Volume' (Linn. Soc. N.S.W., 1893).

WILSON, J. T., 1894. "Observations upon the Anatomy and Relations of the Dumb-bell-shaped Bone in Ornithorhynchus," 'Proc. Linn. Soc. N.S.W.' (1894).

Idem, 1901. "On the Skeleton of the Snout of the Mammary Fœtus of Monotremes." 'Proc. Linn. Soc. N.S.W.,' pp. 717–737, Plates 37–42.

Idem., 1906. "On the Fate of the 'Tænia clino-orbitalis' (GAUPP) in Echidna and in Ornithorhynchus respectively: with Demonstration of Specimens and Stereo-photographs," 'Journ. Anat. and Phys.,' vol. 40, pp. 85–90.

Idem, 1906. "Demonstration of Stereo-photographs of Wax-plate Models of the Skull of a Young Mammary Fœtus of Ornithorhynchus," 'Proc. Anat. Soc. Great Britain and Ireland,' p. 5 (1906).

WINCZA, H., 1896. "Über einige Entwickelungsveränderungen in der Gegend des Schädelgrundes bei den Säugetieren," 'Anz. der Akad. der Wissen. in Krakow,' pp. 326–357.

EXPLANATION OF PLATES.

All the figures in these plates are untouched photographs of preparations in which no artificial means have been adopted to make the sutures more visible.

Plate 23.

A series of four skulls of *Echidna aculeata*, to show the gradual growth forward of two processes (*Proc.Ant.Per.*) from the periotic in the membrana spheno-obturatoria which finally (in fig. 4) meet the ala temporalis and the temporal wing of the palatine to close the sphenoparietal fissure.

Fig. 1.—S. 1154, Australian Museum. *A.T.*, ala temporalis; *B.Oc.*, basioccipital; *Mx.*, maxilla; *Proc.Ant.Per.*, the processes of the periotic which ossify in the membrana spheno-obturatoria; *Pt.*, pterygoid.

In this specimen the palatine and vomer have been removed.

Fig. 2.—S. 1196, Australian Museum. Reference letters as in fig. 1, with *Ech.Pt.*, "Echidna pterygoid"; *Pl.*, palatine; *Pl.T.*, temporal wing of the palatine; *Sq.*, squamosal.

Fig. 3.—S. 1240, Australian Museum.

Fig. 4.—Australian Museum. *Mall.*, malleus; *Ty.*, tympanic.

Plate 24.

Fig. 1.—Base of the skull of a young Echidna (S. 1154 of the Australian Museum) with the palatine removed. To show the clear suture between the pterygoid and the basisphenoid anteriorly and the foramen for the Vidian (parabasale) nerve, *F.N.P.*

Fig. 2.—The same specimen; to show the ala temporalis and the suture between the basisphenoid and the pterygoid posteriorly.

Fig. 3.—The orbitotemporal region of a skull of Echidna (S. 1240, Australian Museum) with the squamosal removed. *F.A.T.S.*, two foramina, presumably for the superficial temporal artery; *R.P.VII.*, groove and foramen for the great superficial petrosal nerve; "*Mast.Pter.*," pterotic process of the mastoid (van Bemmelen); *Or.Sp.*, orbitosphenoid (so-called postfrontal).

Fig. 4.—*Ornithorhynchus anatinus.* Embryo β, section 169, slide B 39, row 2, sec. 3. *Gang.Ot.*, otic ganglion with the great superficial petrosal nerve running through it; *Cart.Meck.*, Meckel's cartilage; *Pr.Art.*, prearticular (Goniale, Gaupp); *Pr.O.*, prootic ossification in the otic capsule (notice its complete continuity with the processus anterior periotica, the membrane ossification in the membrana spheno-obturatoria); *V.C.L.*, vena capitis lateralis.

PLATE 25.

A series of photographs of a skull of Ornithorhynchus in the Zoological Department of Sydney University.

Fig. 1.—Dorsal aspect. × $1\frac{1}{2}$ approx. *Fr.*, frontal; *Mx.*, maxilla; "*Mast.Pter*," pterotic wing of mastoid (VAN BEMMELEN): *Na.*, nasal; *Or.Sp.*, orbitosphenoid; *Par.*, parietal; *S.Mx.*, septomaxillary; *S.Oc.*, supraoccipital; *Sq.*, squamosal.

Fig. 2.—Ventral aspect. *A.T.*, ala temporalis (notice especially that it appears on the ventral surface and has a clear suture with the palatine); *Cr.Pr.*, crista parotica (paroccipital process); *P.V.*, prevomer, dumb-bell-shaped bone, os paradoxum; *Pl.*, palatine; *Proc.Ant.Per.*, processus anterior periotici, the portion of the periotic ossified in the membrana spheno-obturatoria.

Fig. 3.—Lateral aspect. *Ju.*, jugal; *Pet.*, the "mastoid" portion of the petrosal.

Fig. 4.—The orbitotemporal region viewed laterally with the zygomatic arch removed. *F.A.T.S.*, foramen for the superficial temporal artery (VAN BEMMELEN, foramen vascularem medium); *Pt.*, pterygoid (the fine dotted line indicates the apparent position of the posterior part of the suture between it and the basisphenoid, but on the specimen this suture is too faint for certainty).

Fig. 5.—Posterior aspect. × 2 approx.

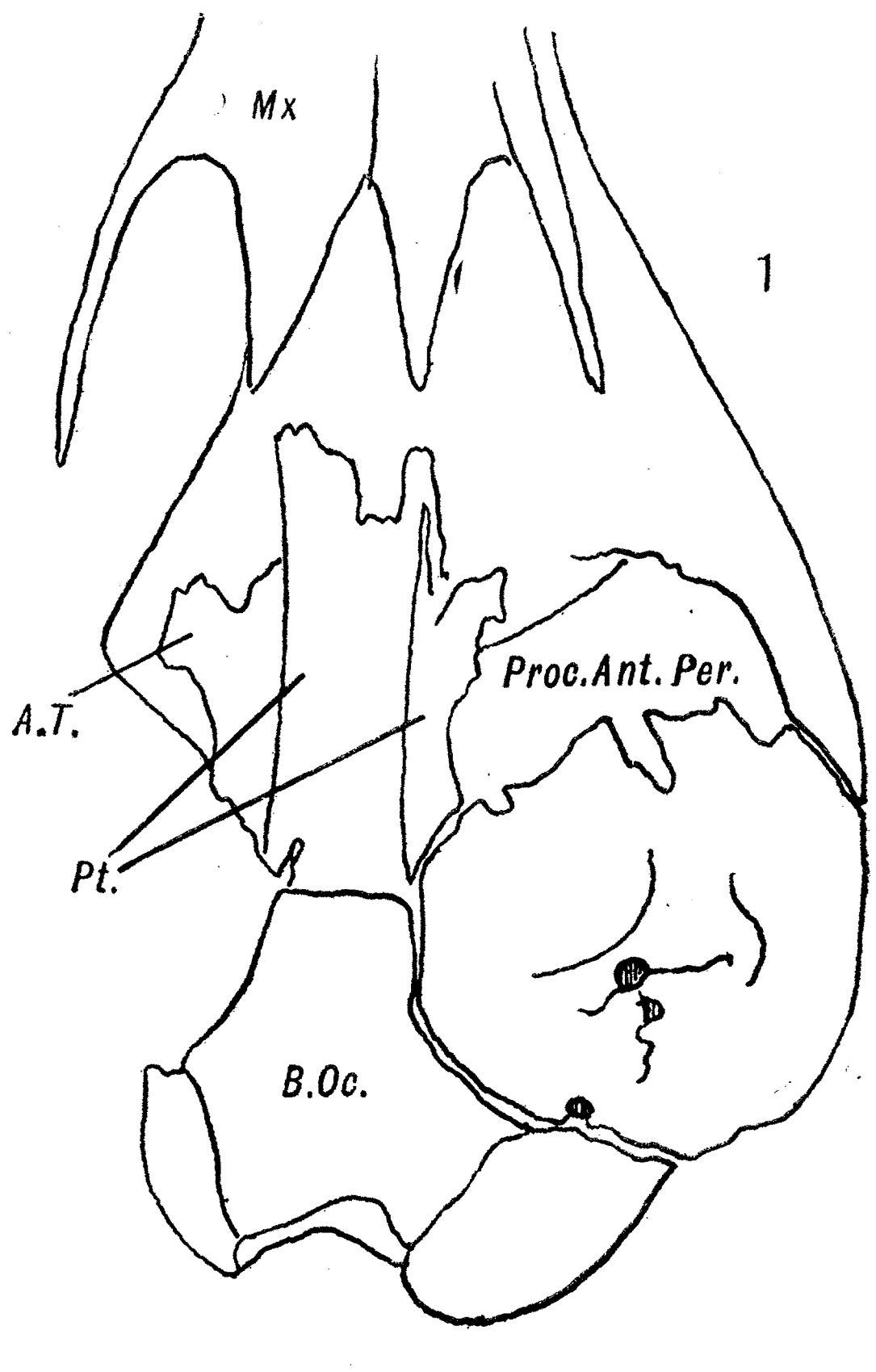
1
Mx
A.T.
Pt.
Proc.Ant.Per.
B.Oc.

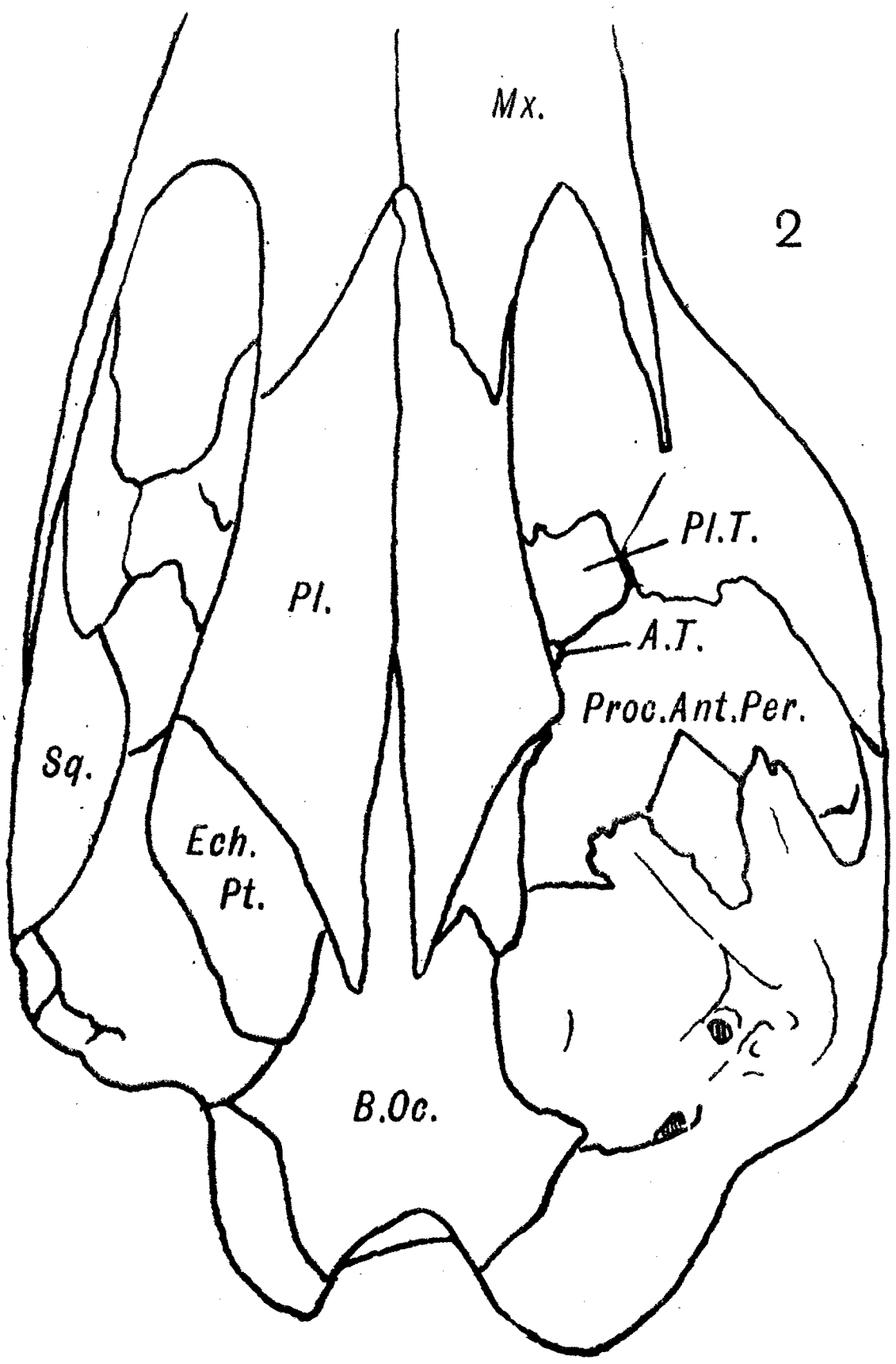
2
Mx.
Pl.T.
Pl.
A.T.
Proc.Ant.Per.
Sq.
Ech.
Pt.
B.Oc.

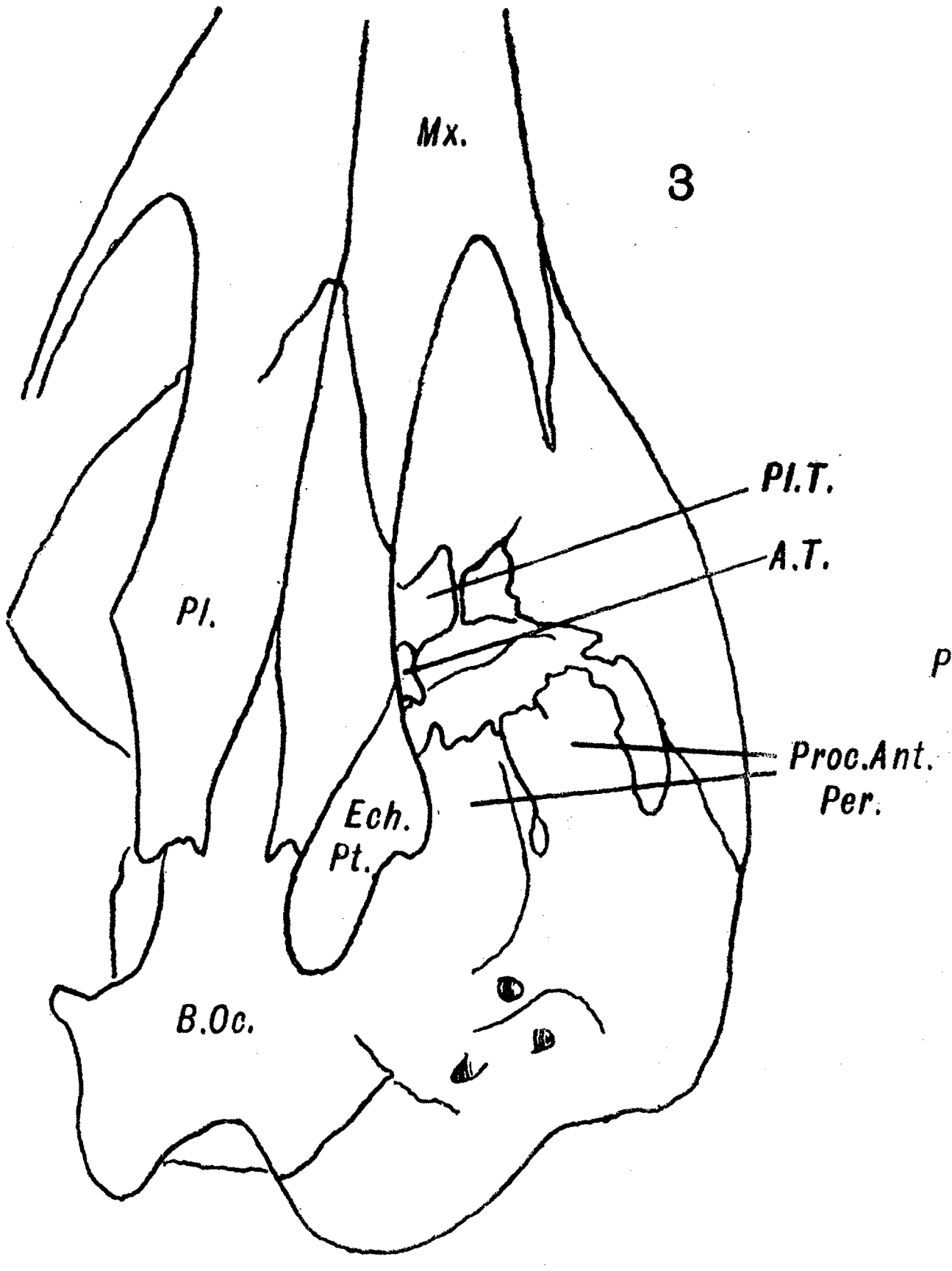
3
Mx.
Pl.T.
A.T.
Pl.
Proc.Ant.
Per.
Ech.
Pt.
B.Oc.

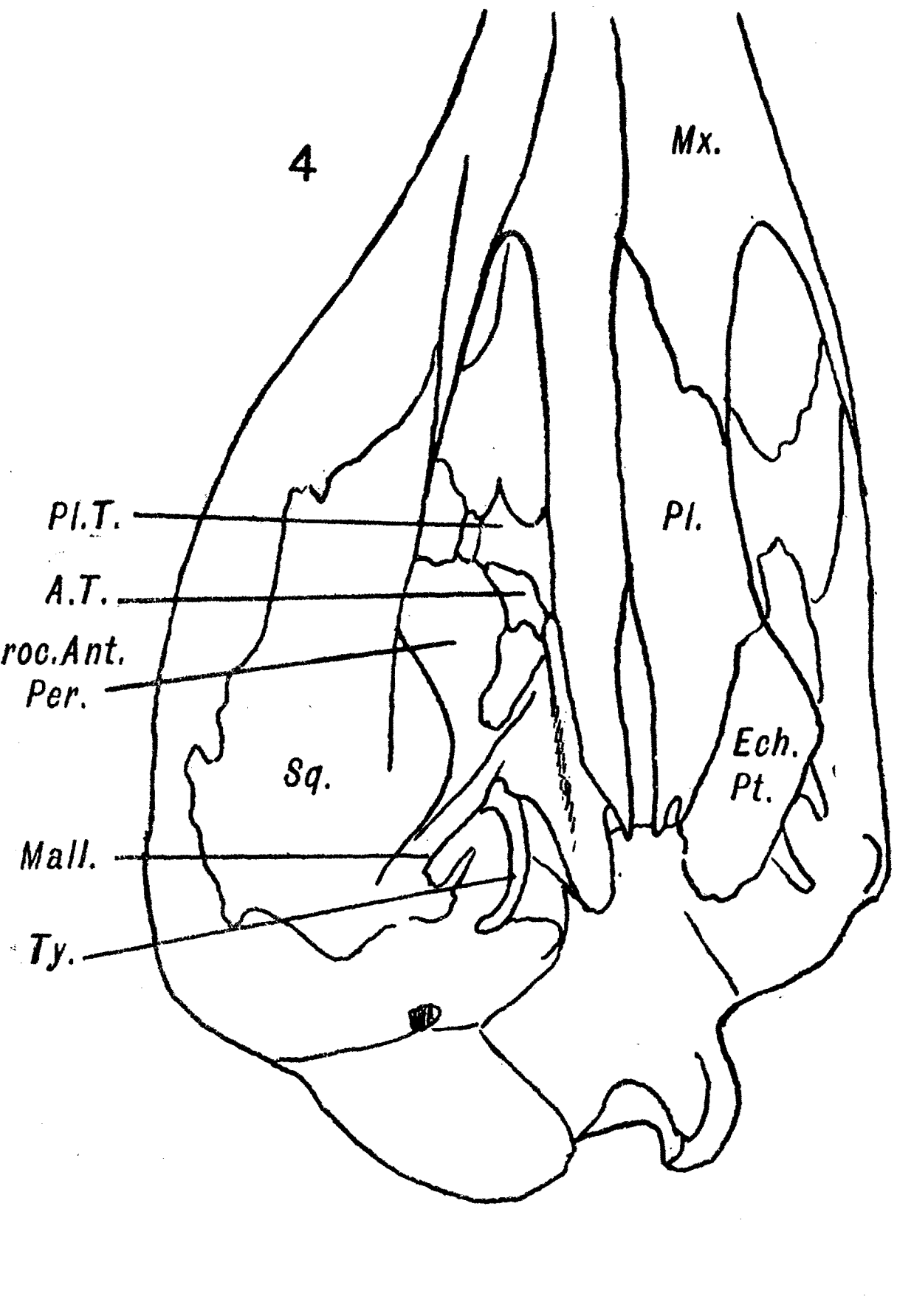
4
Mx.
Pl.T.
Pl.
A.T.
Proc.Ant.
Per.
Ech.
Pt.
Sq.
Mall.
Ty.

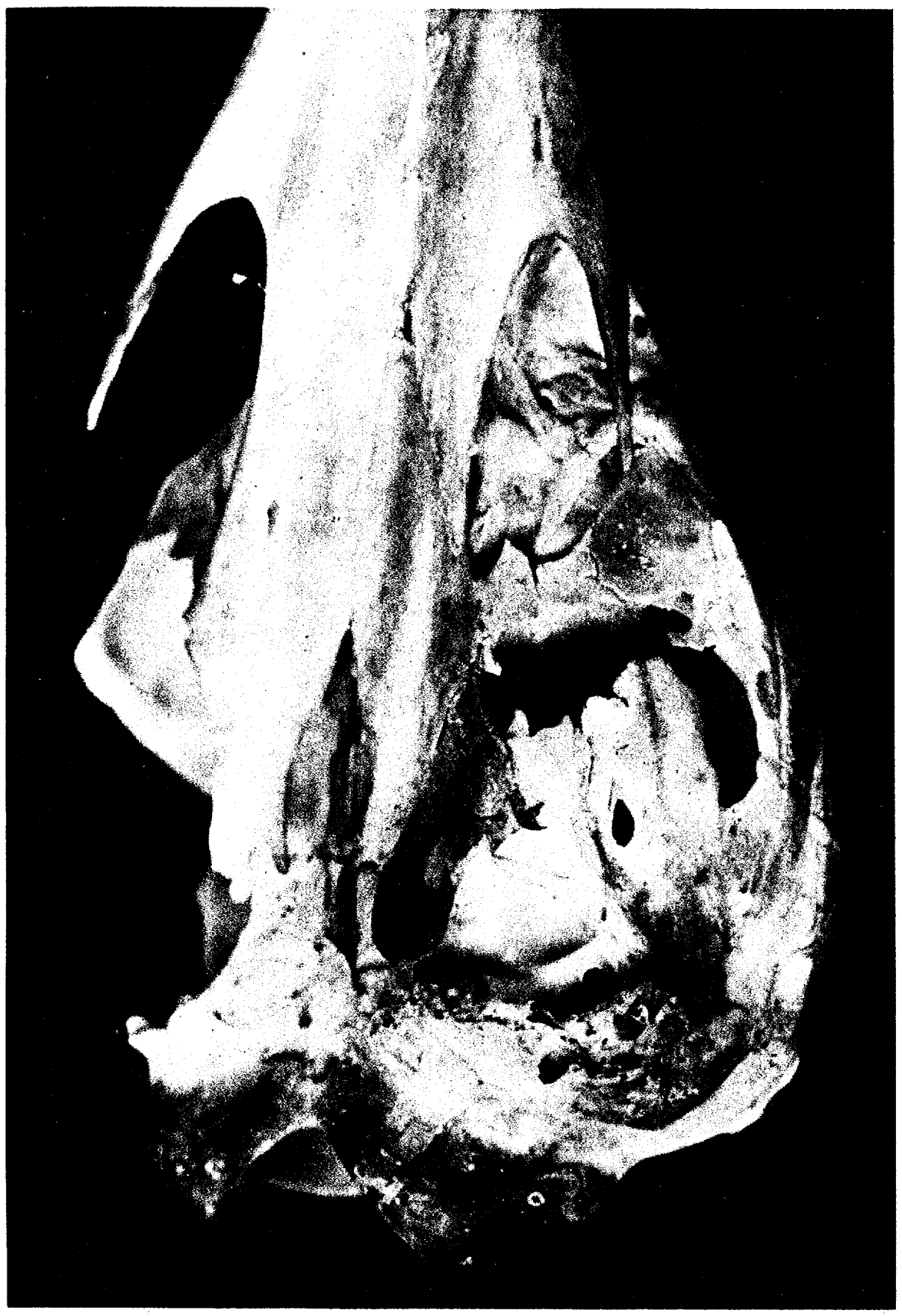

Cambridge University Press.

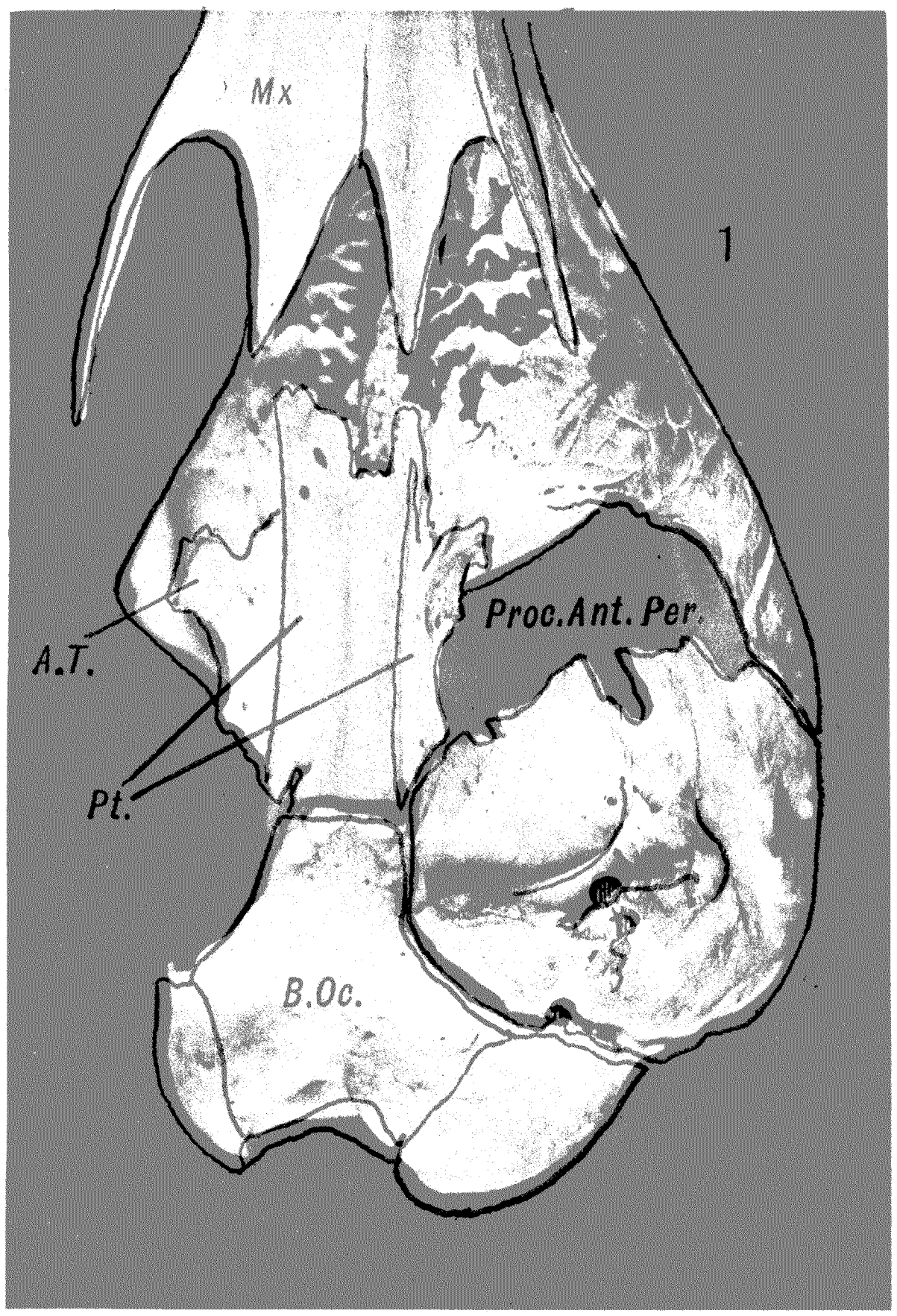

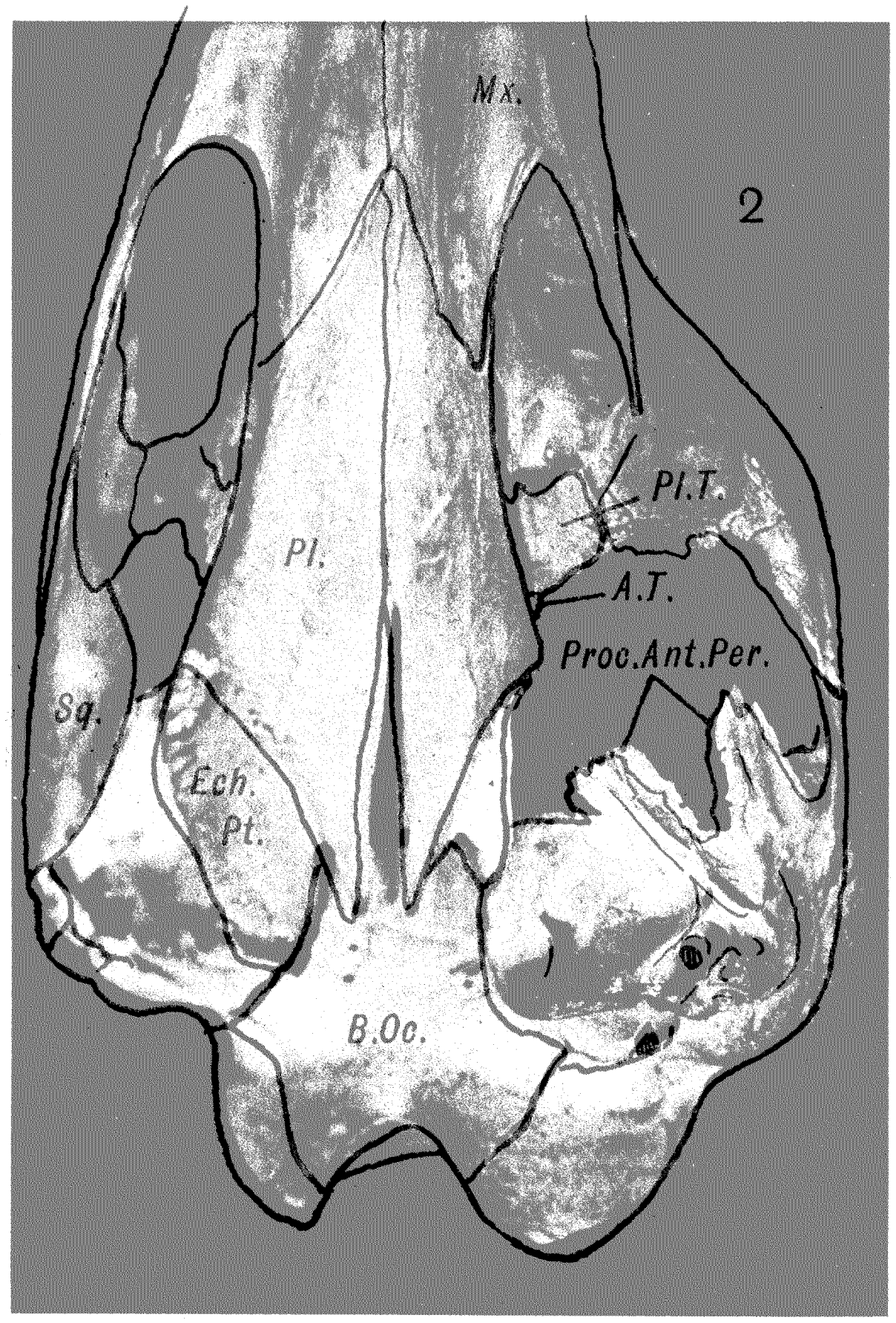

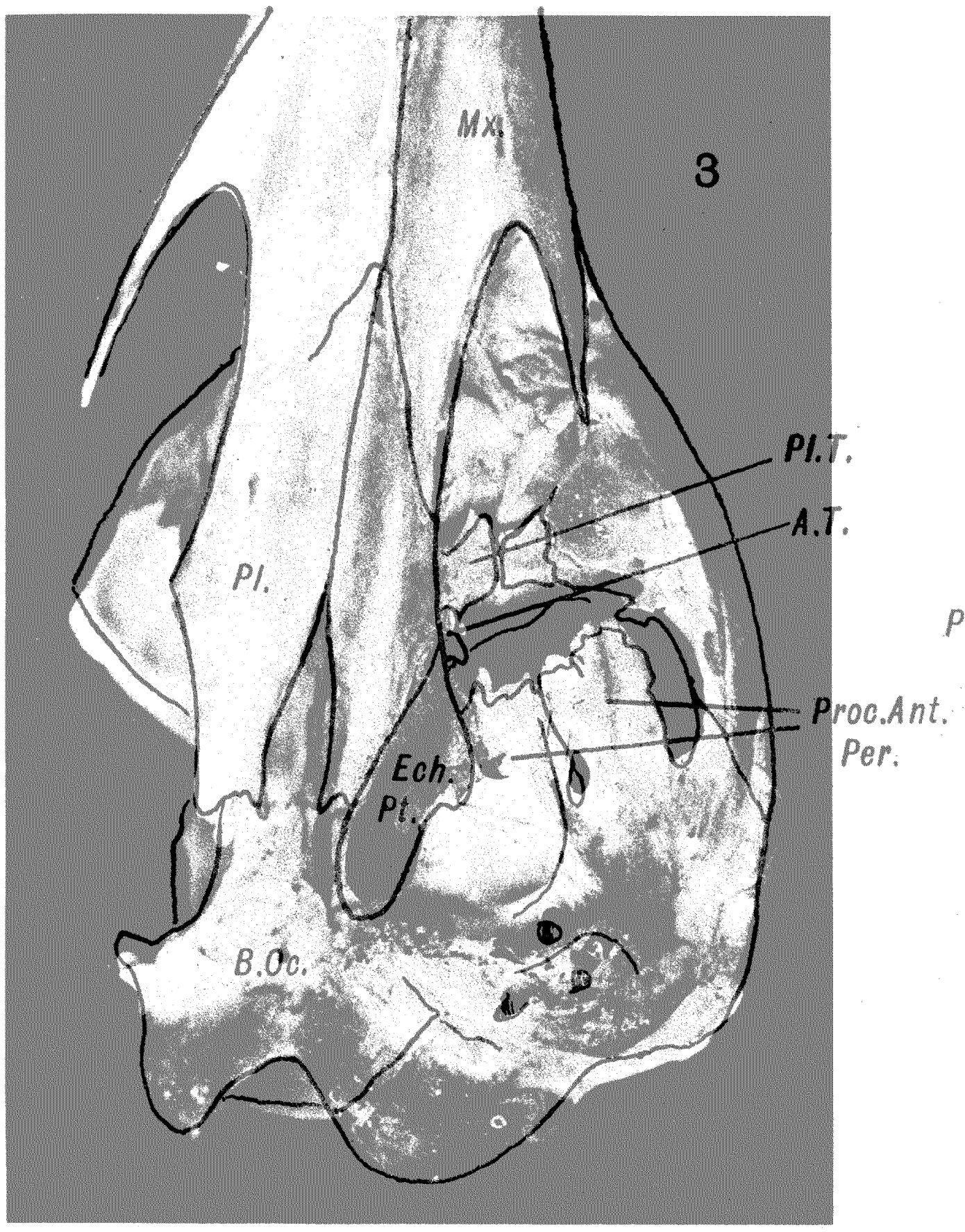

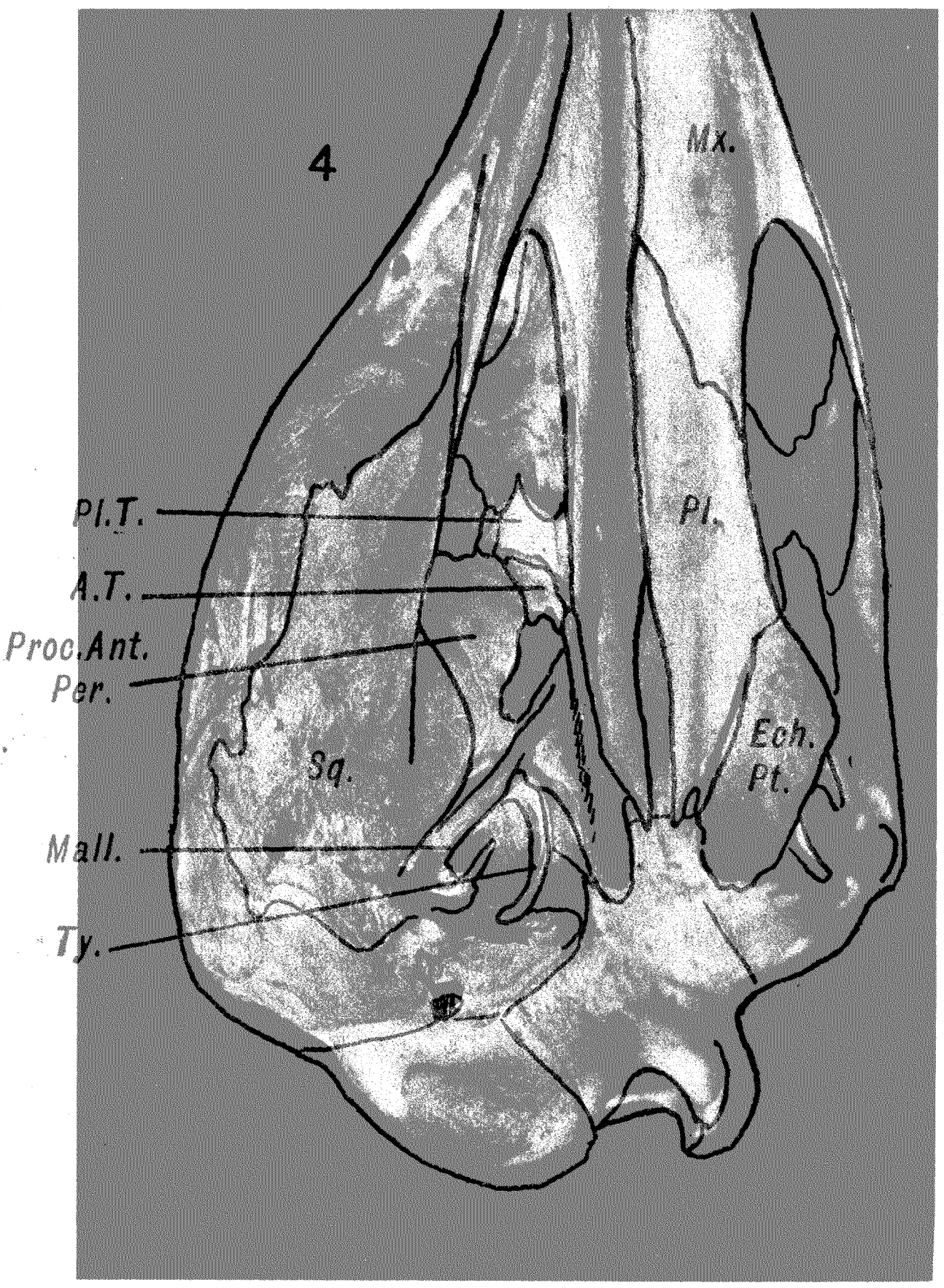

Cambridge University Press.

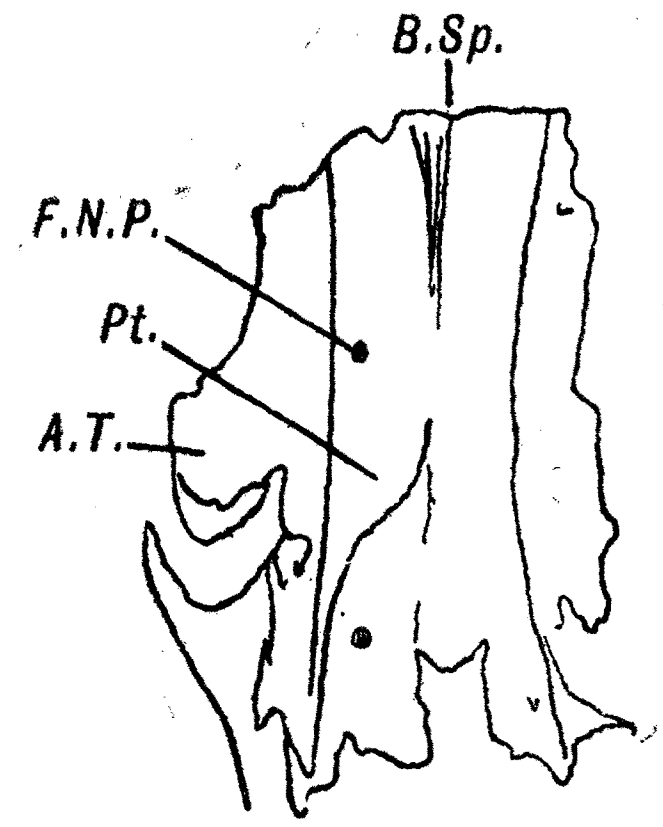

1

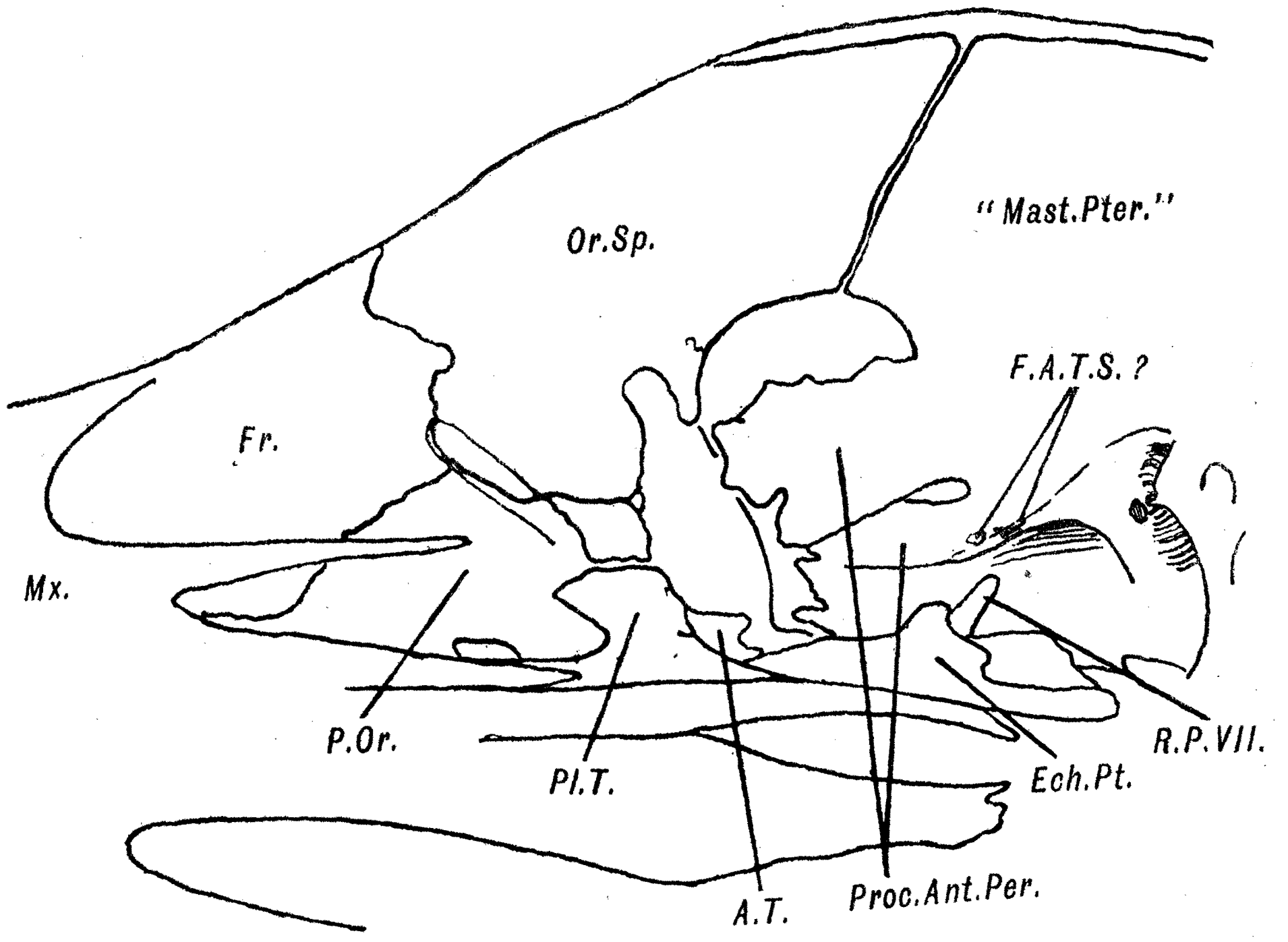

3

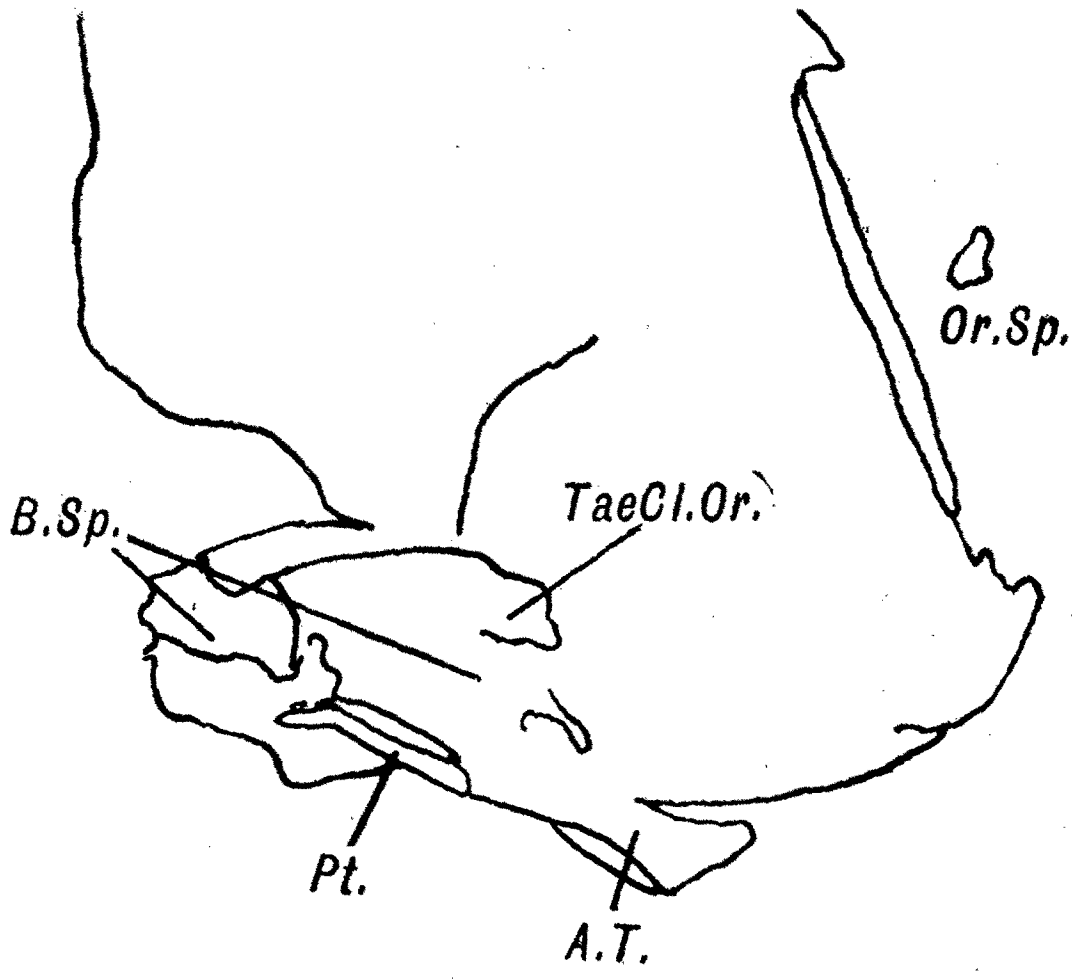

2

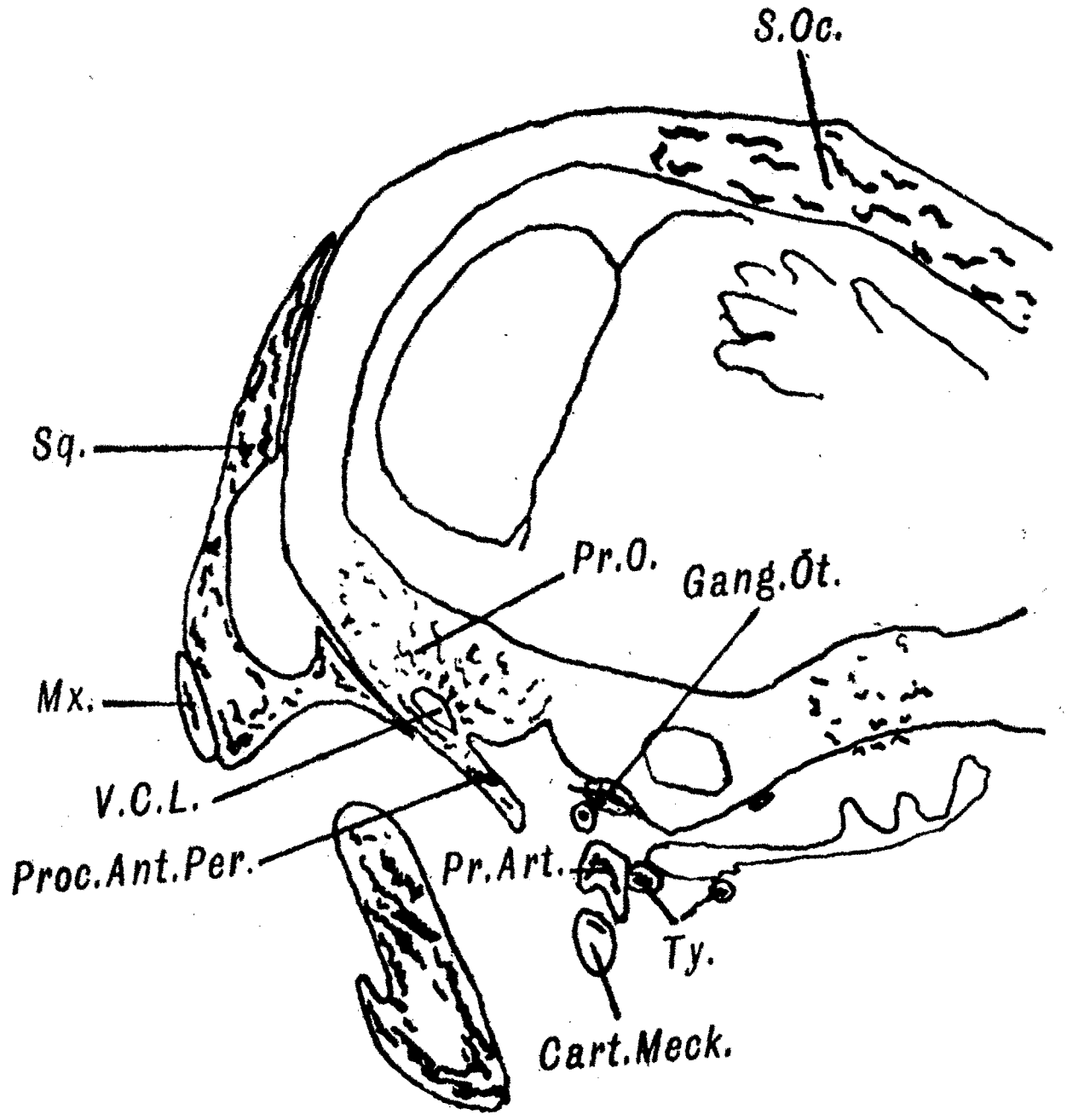

4

Cambridge University Press.

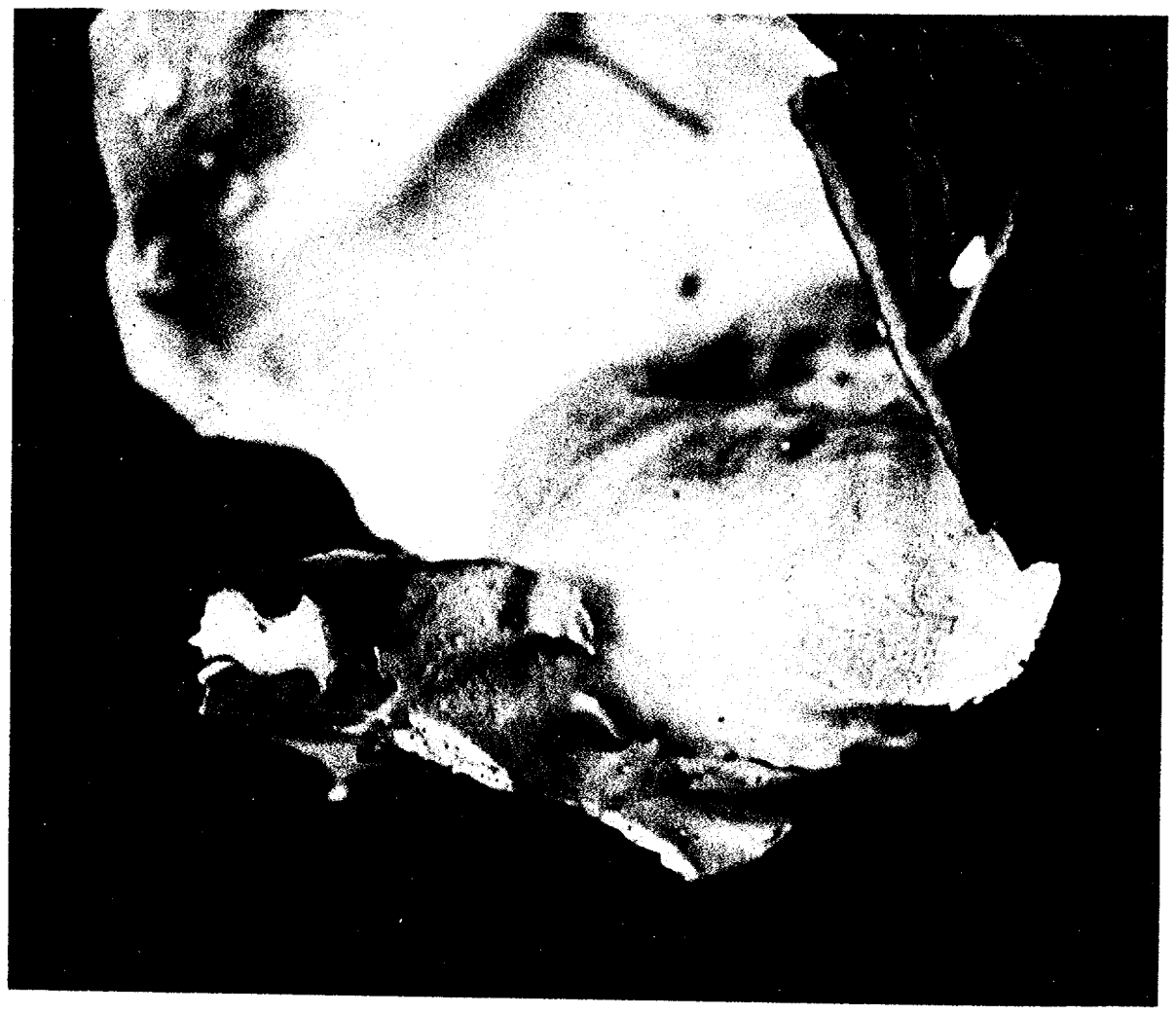

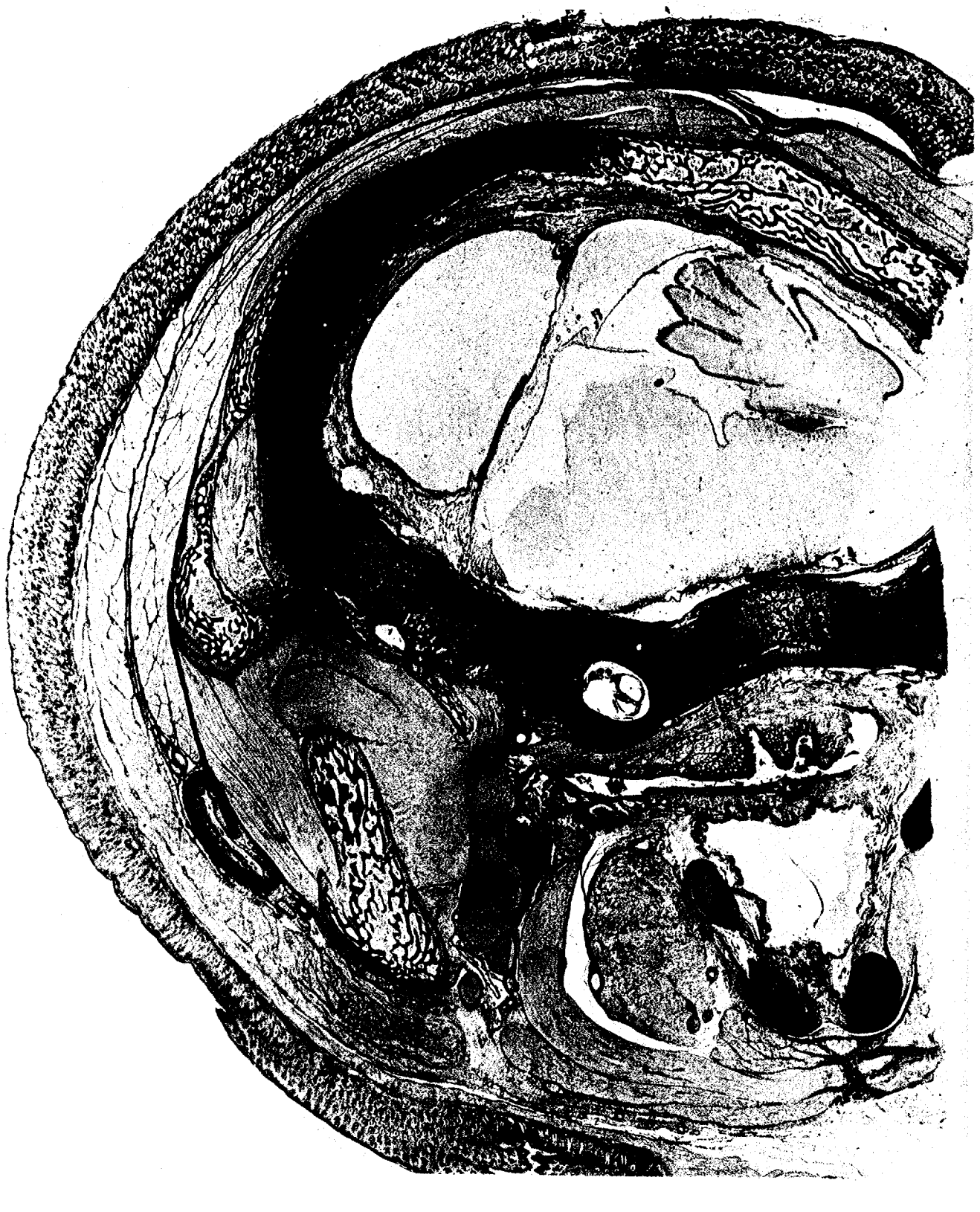

Cambridge University Press.

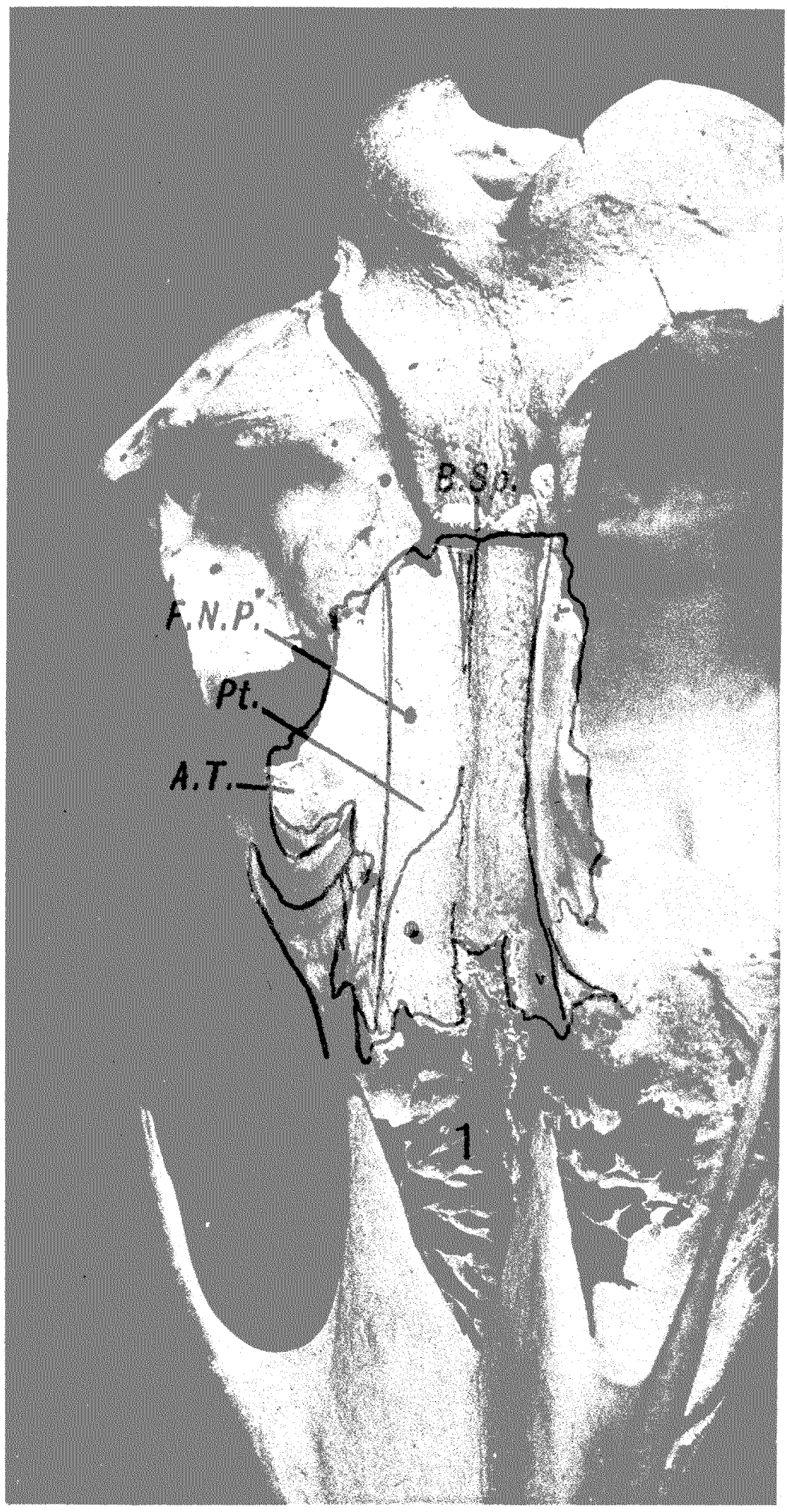

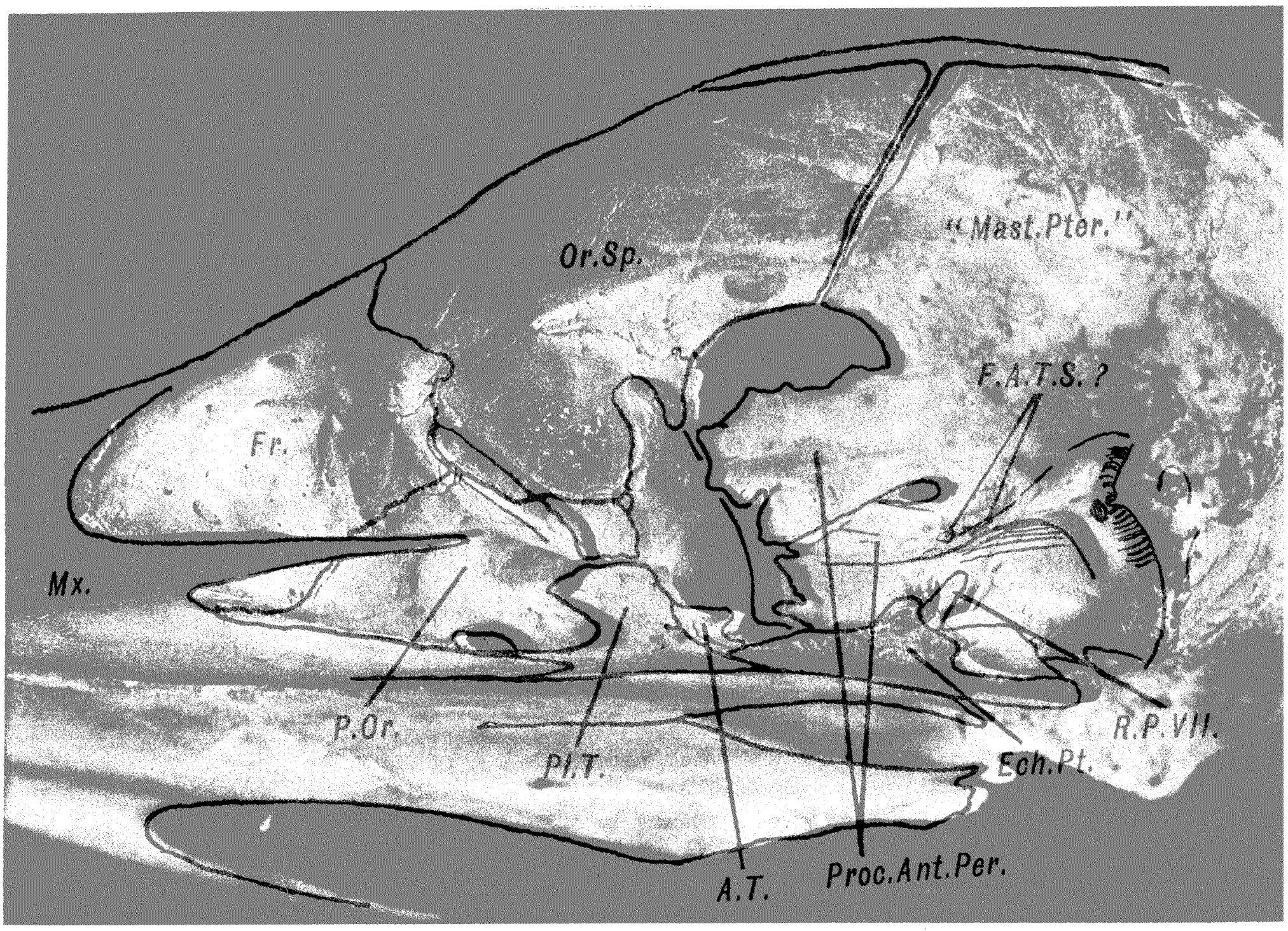

3

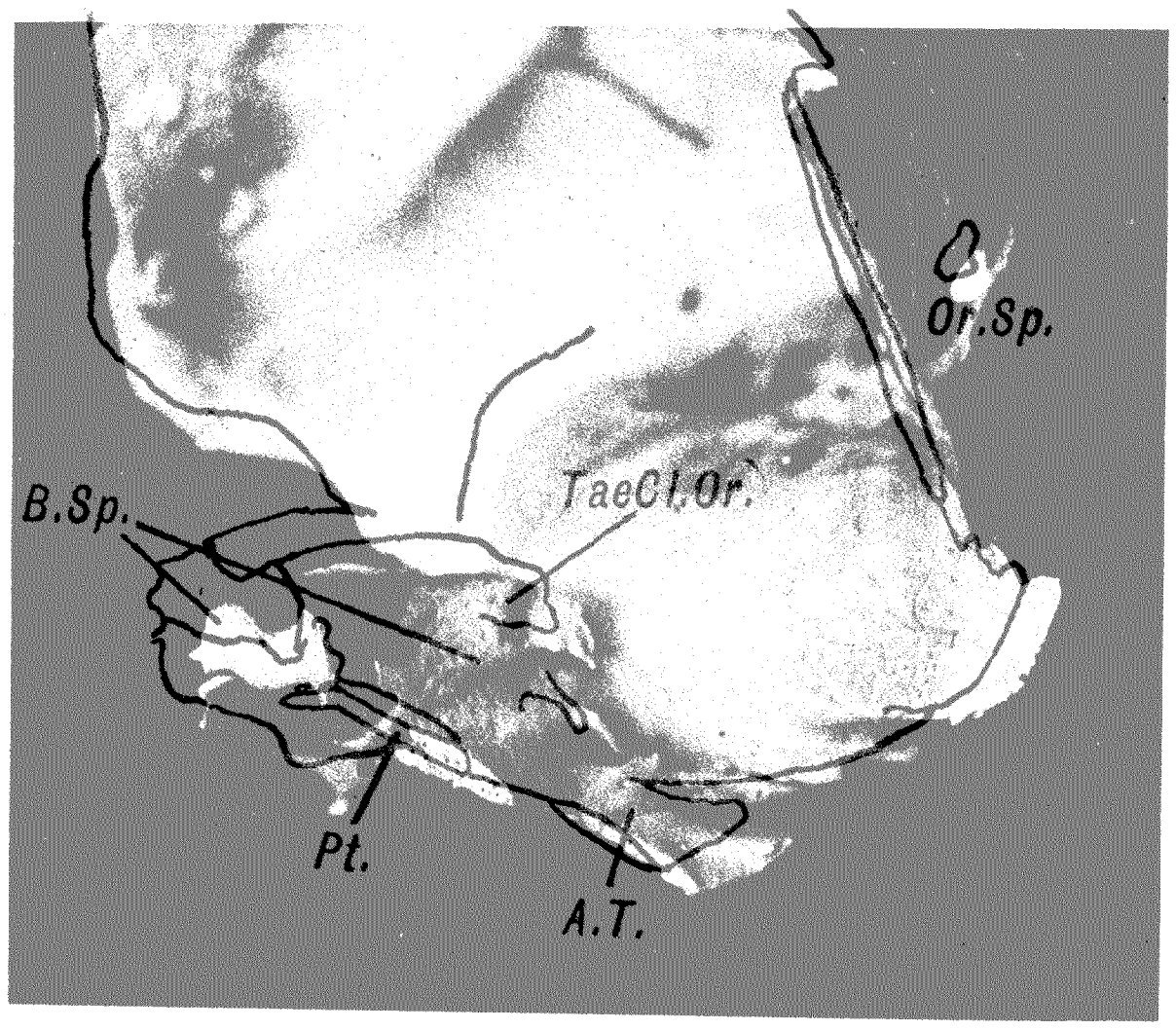

2

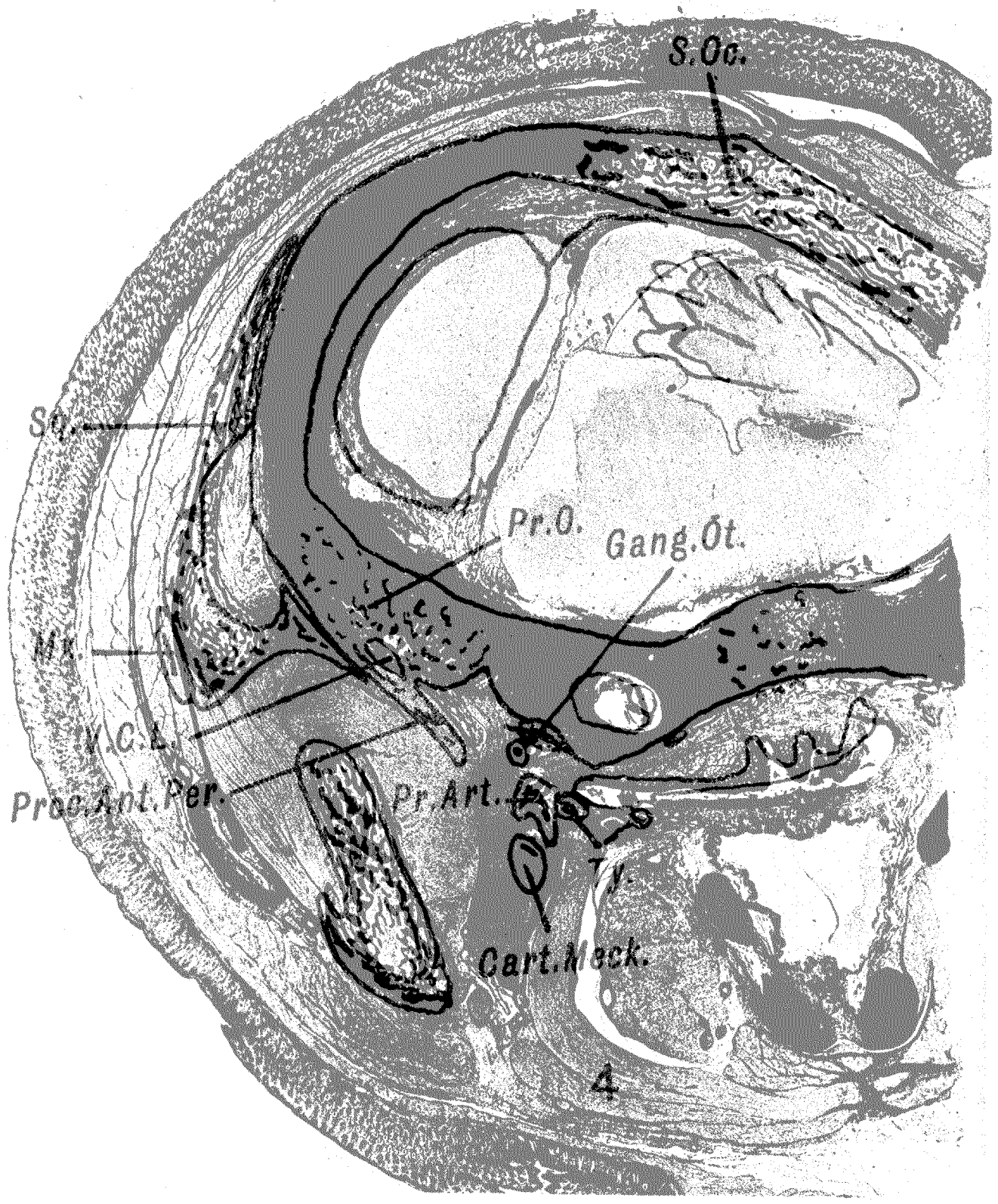

Cambridge University Press.

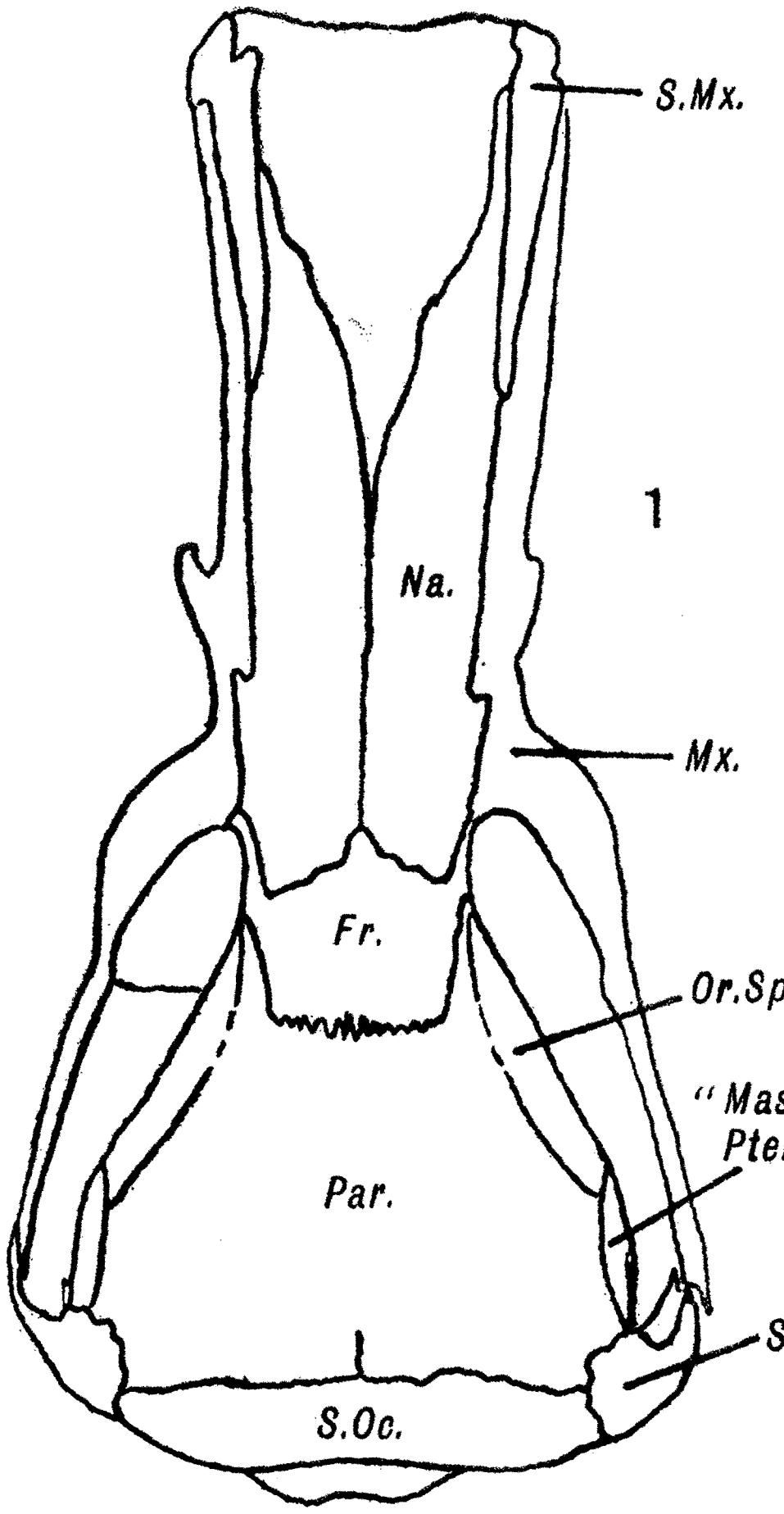

1

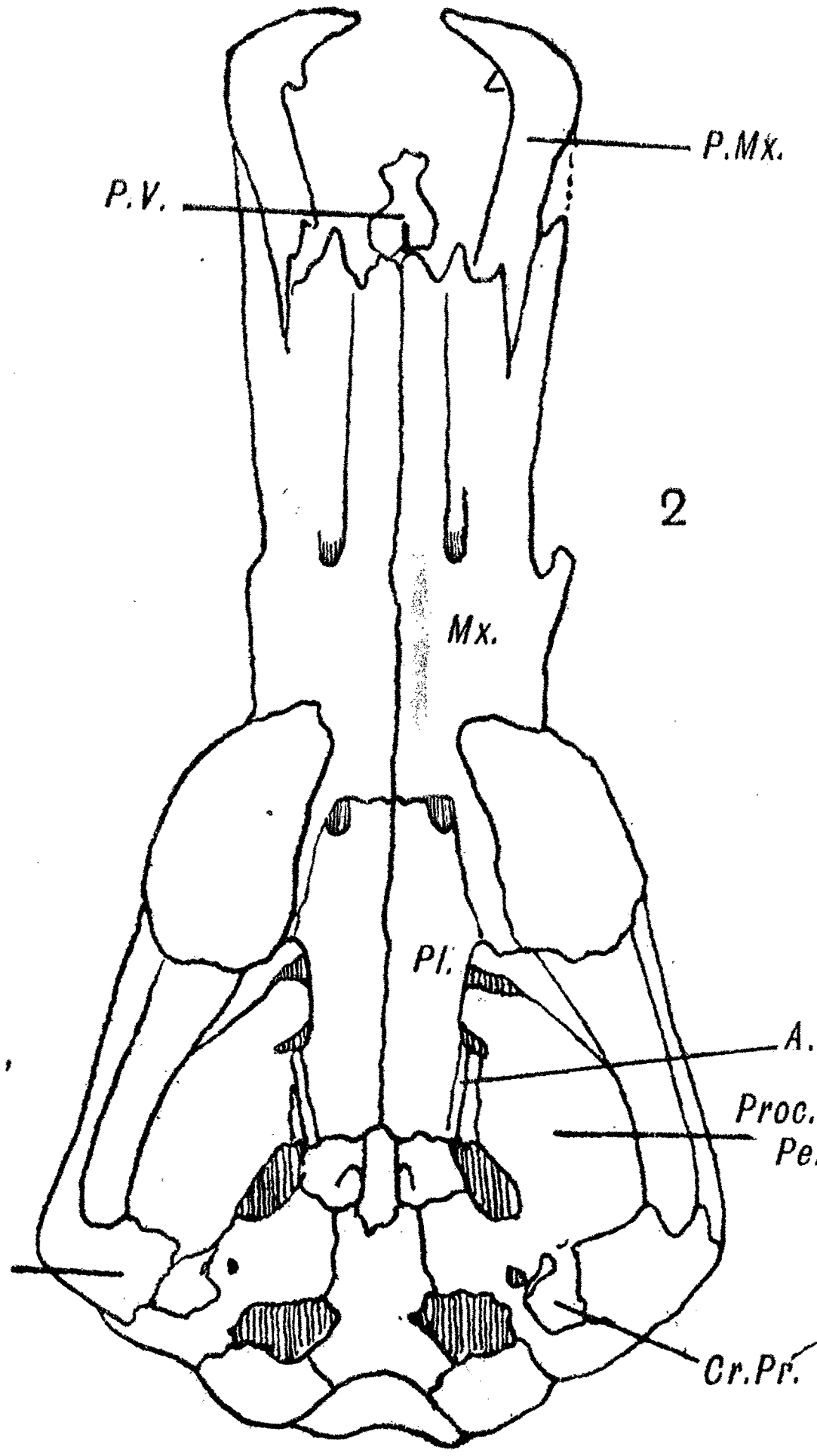

2

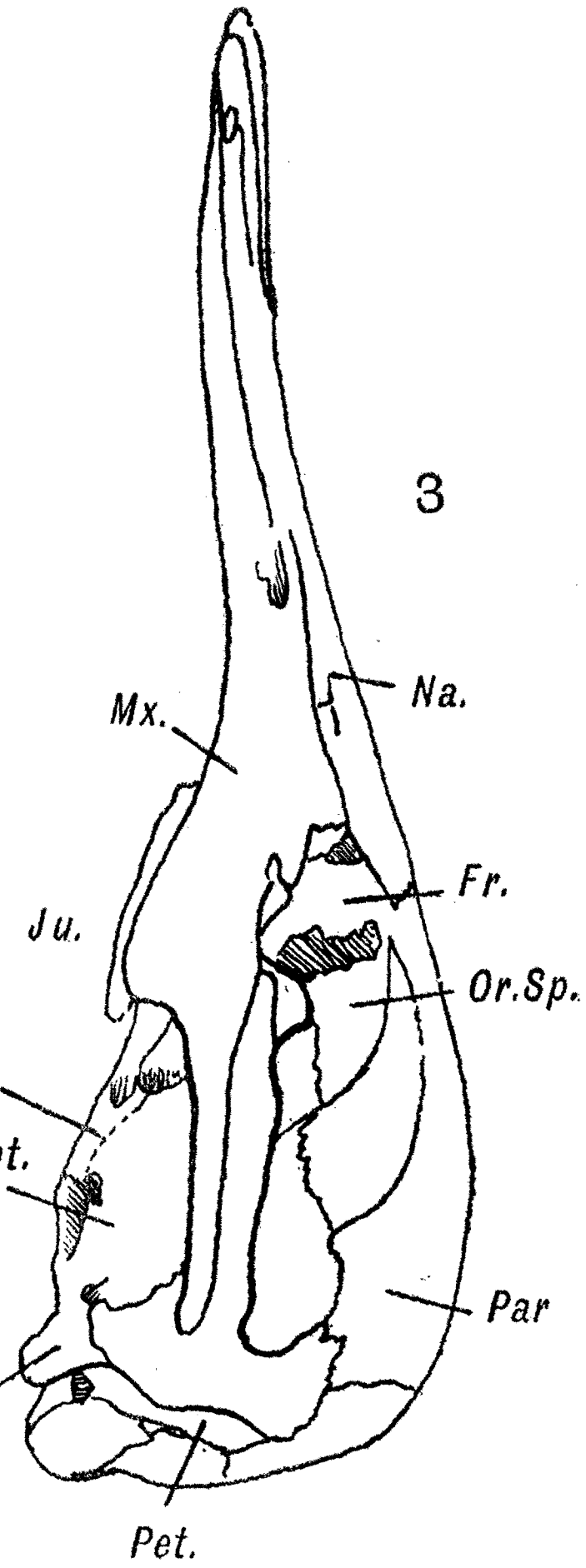

3

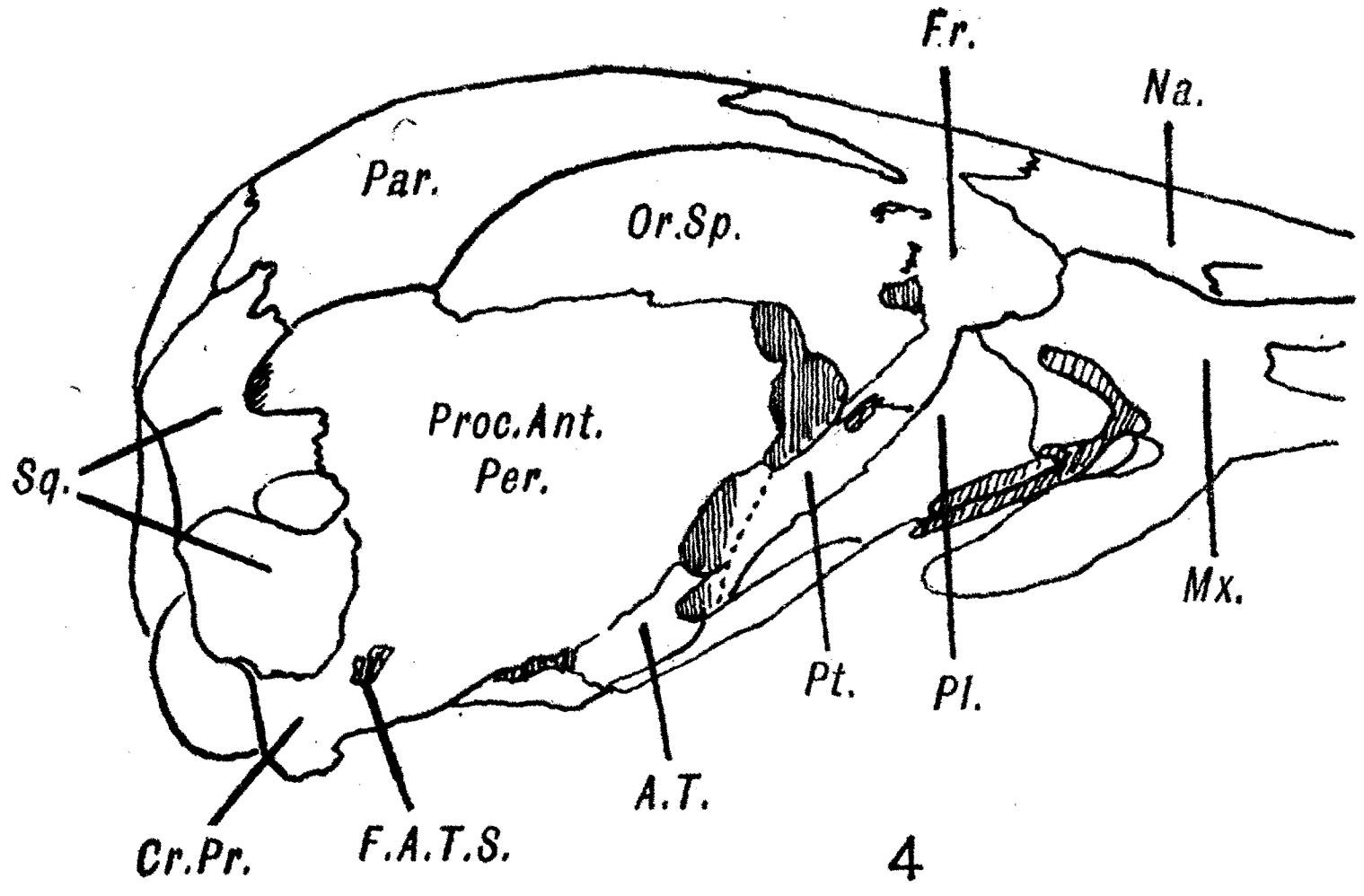

4

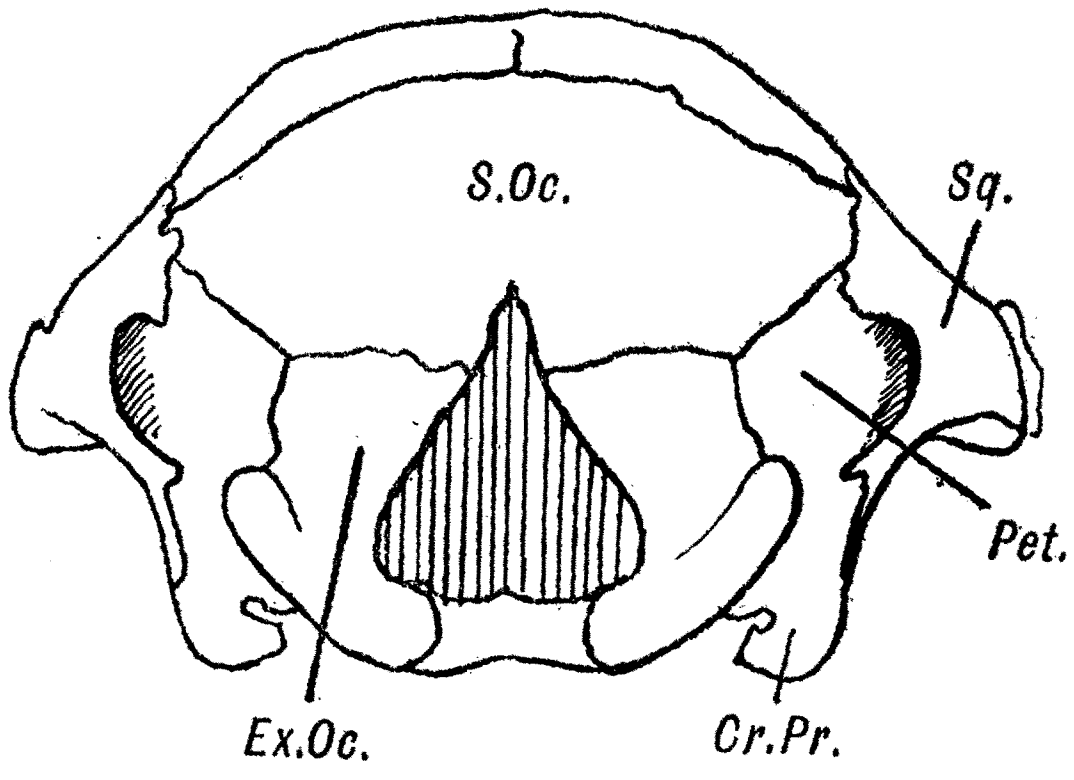

5

Cambridge University Press.

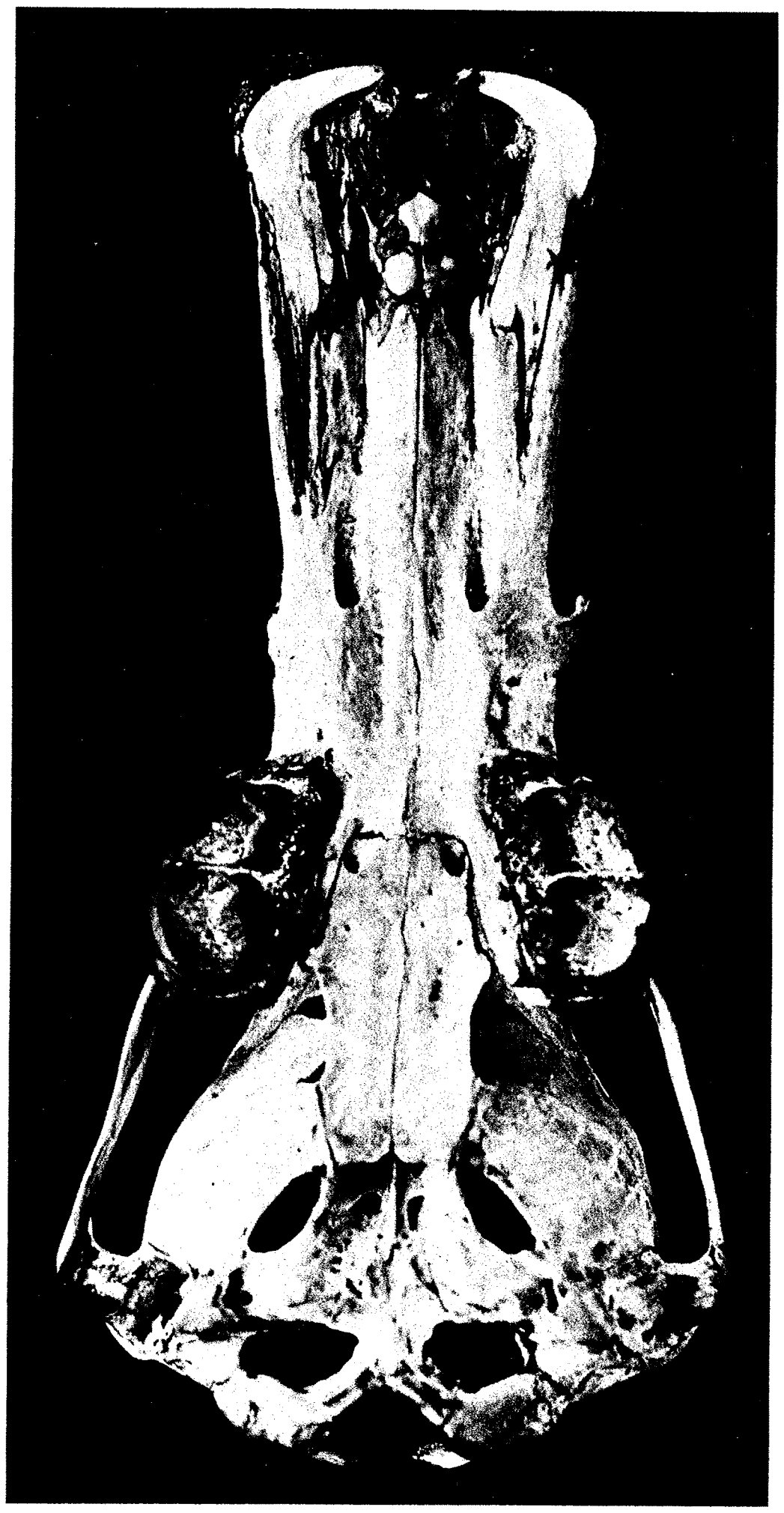

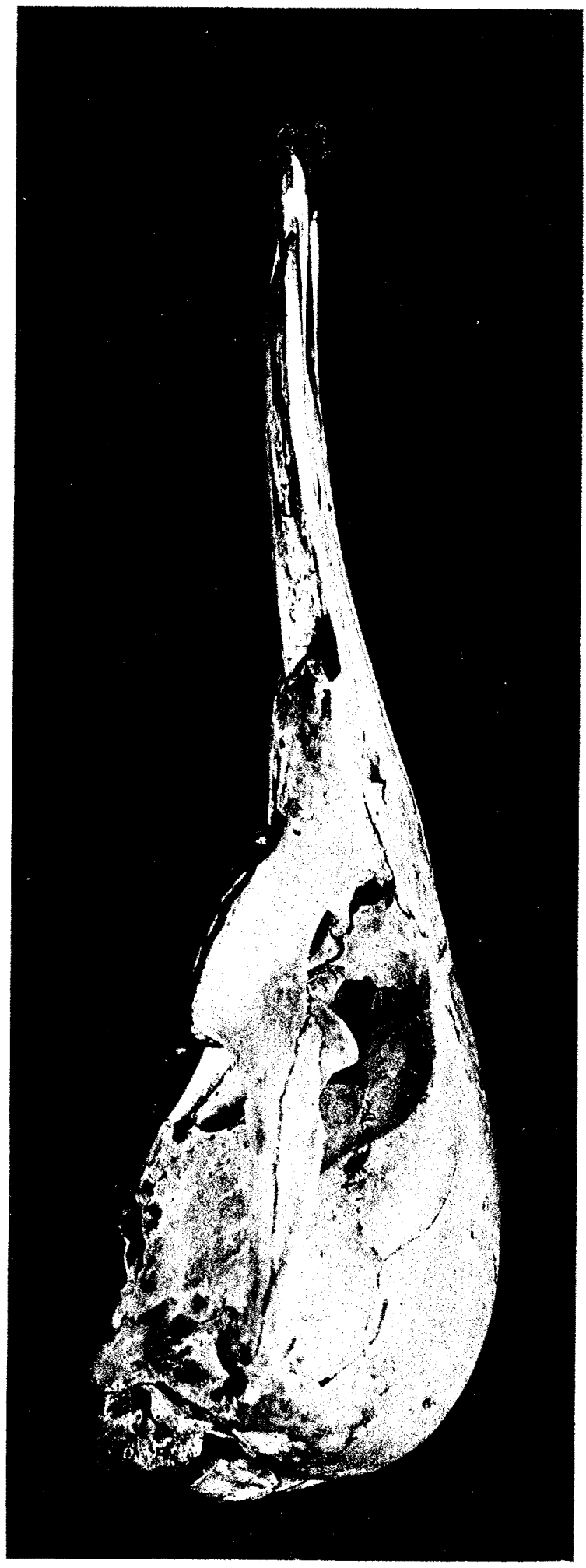

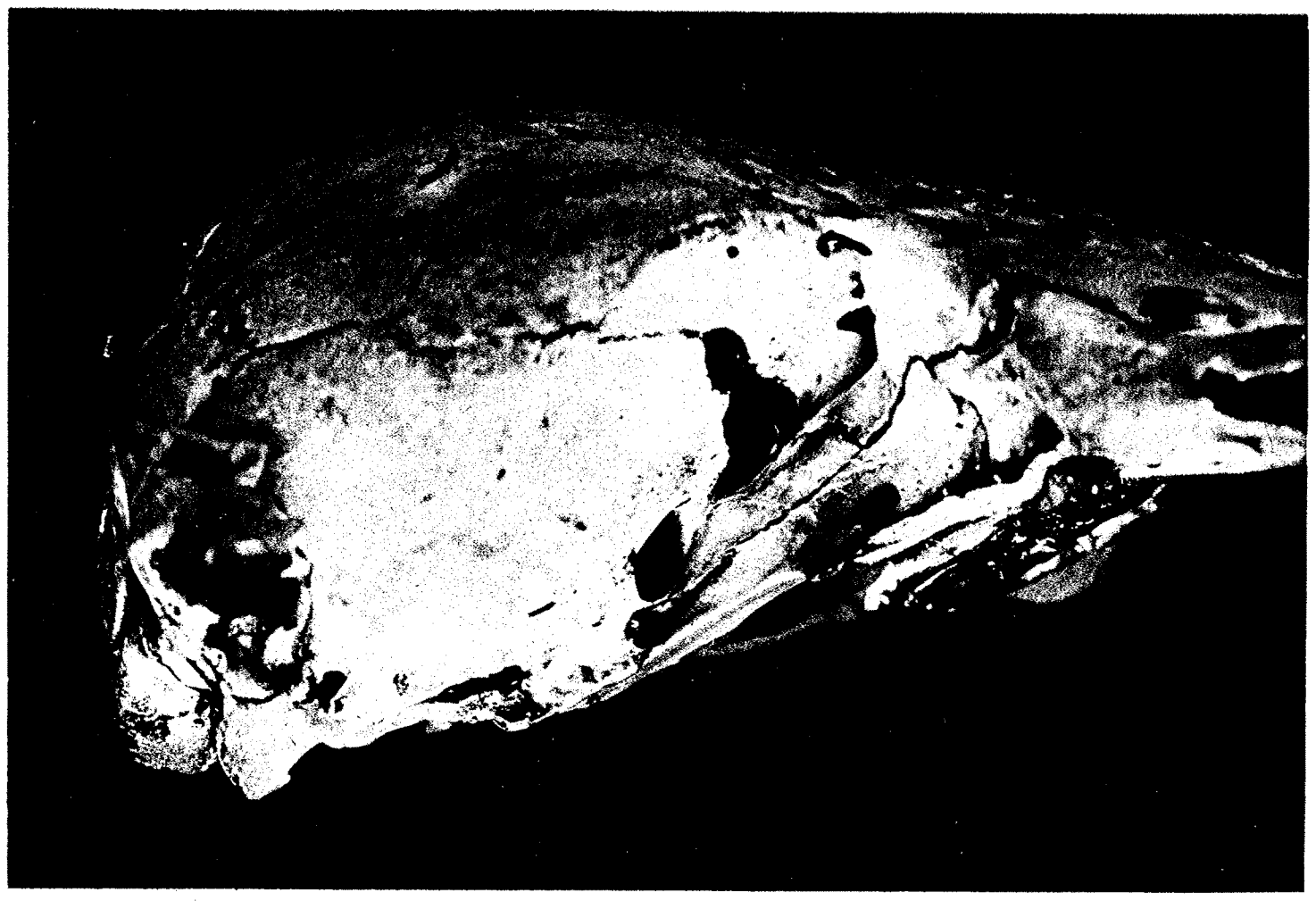

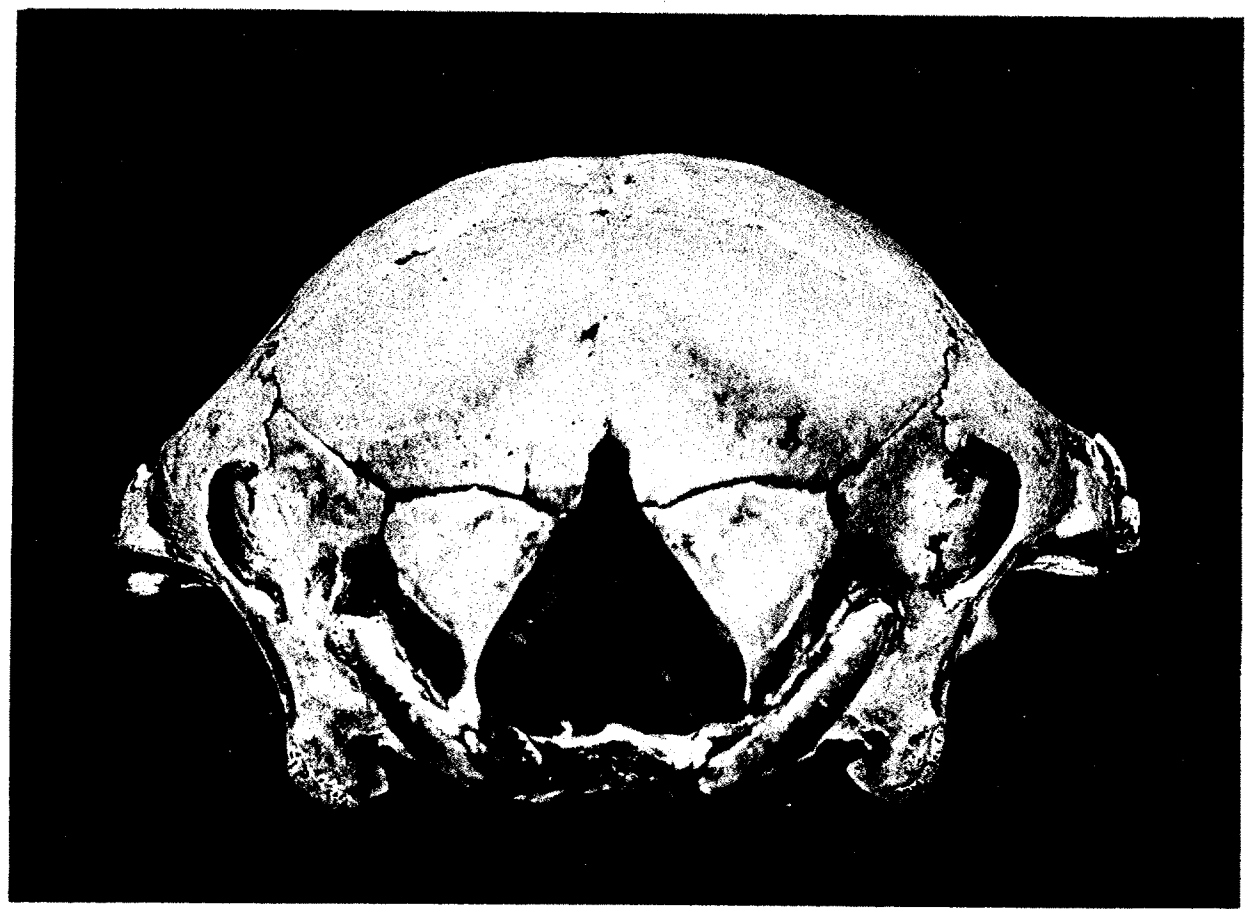

Cambridge University Press.

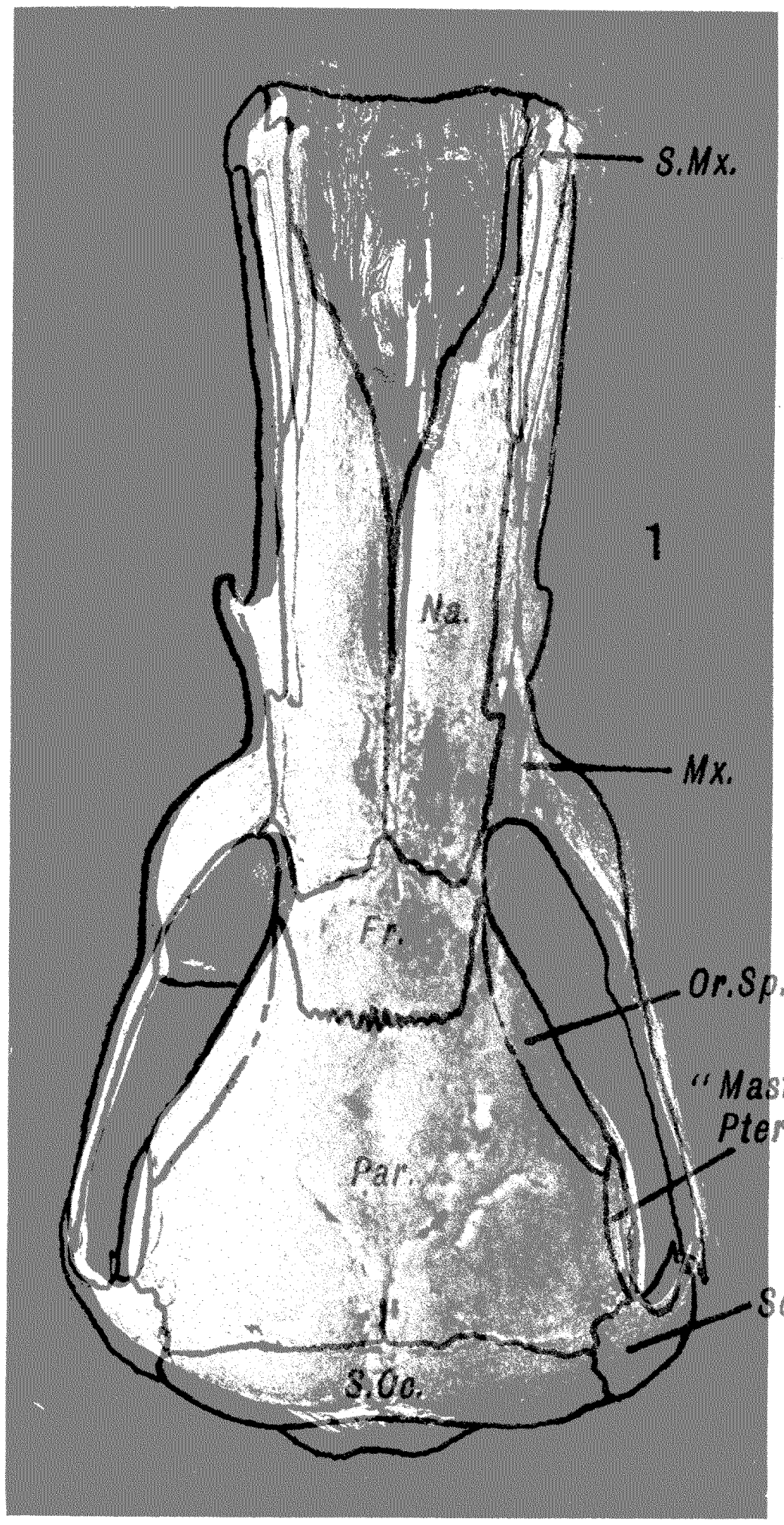

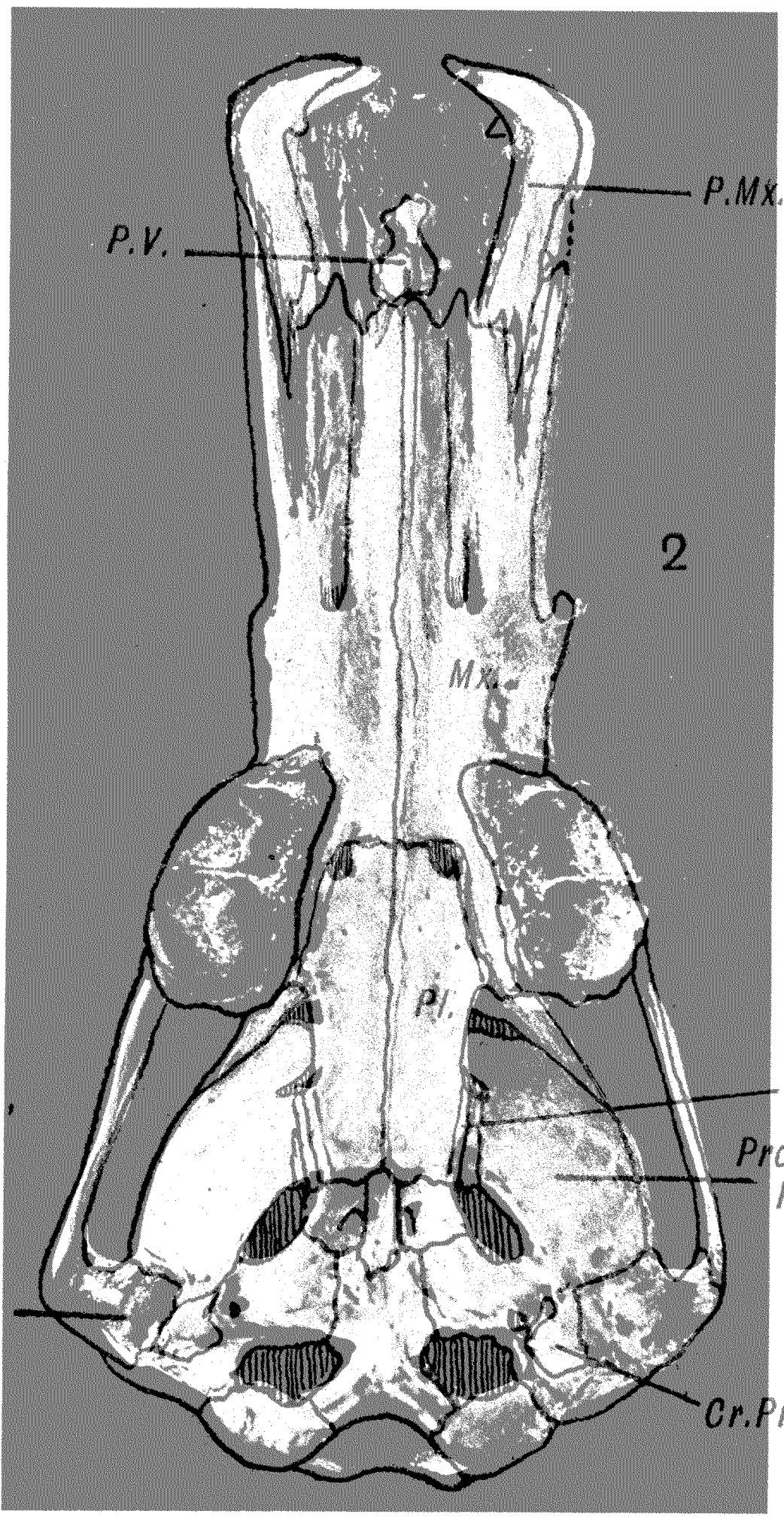

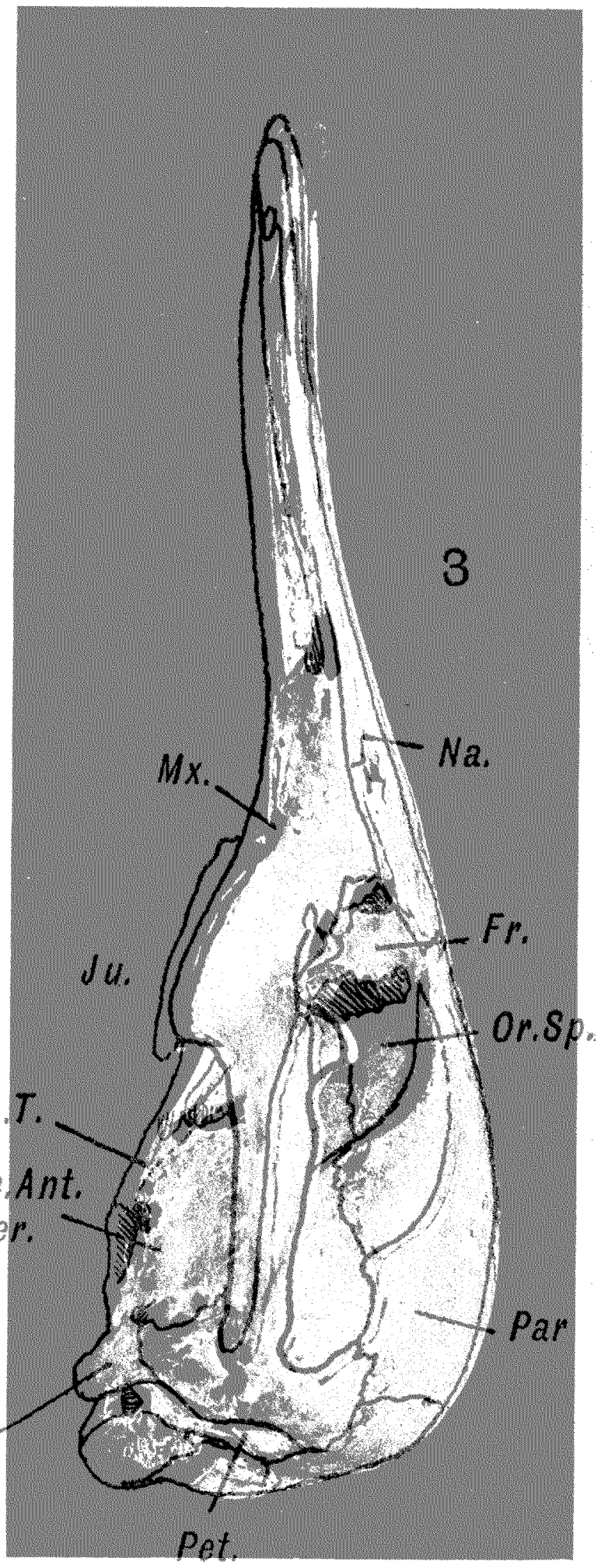

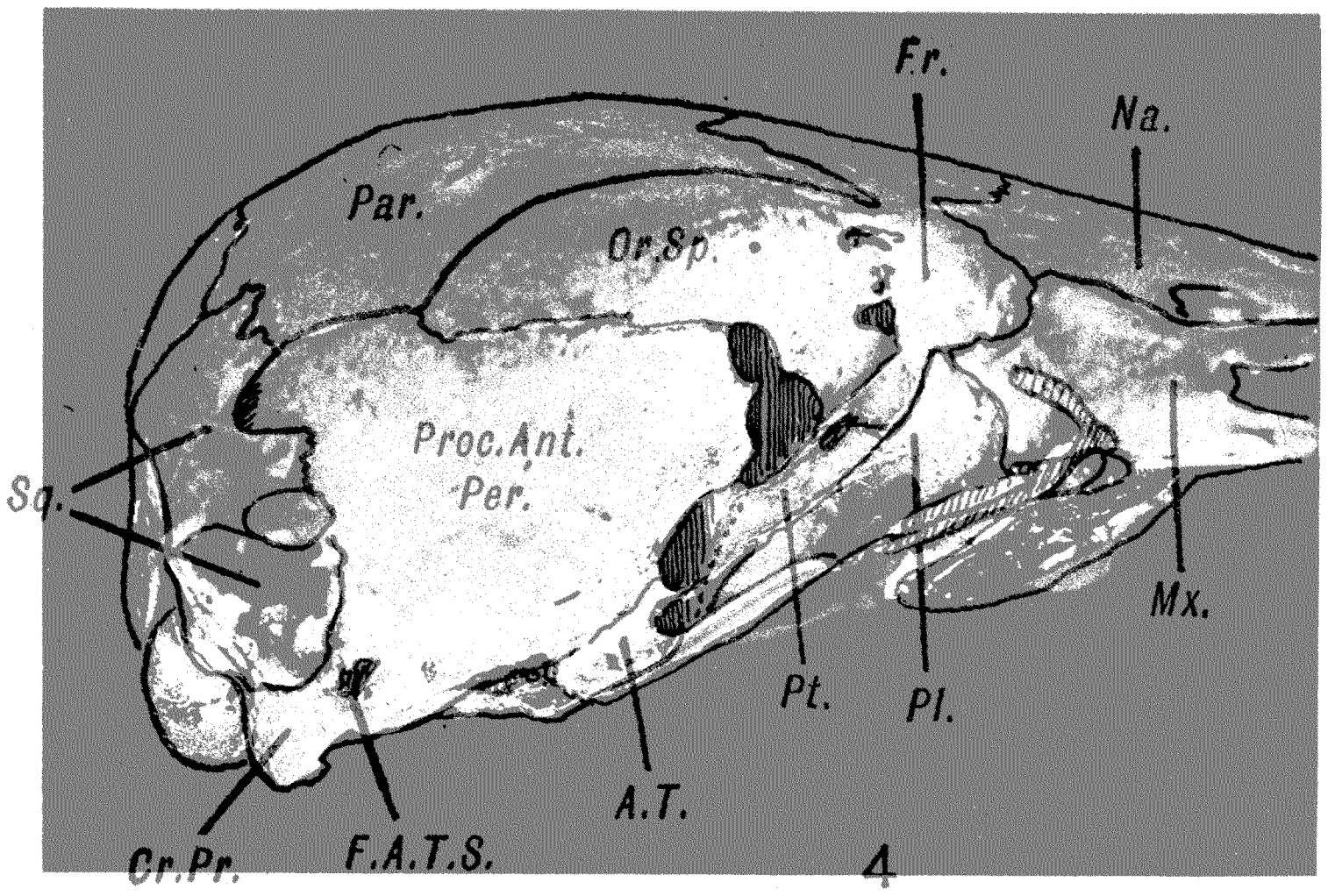

4

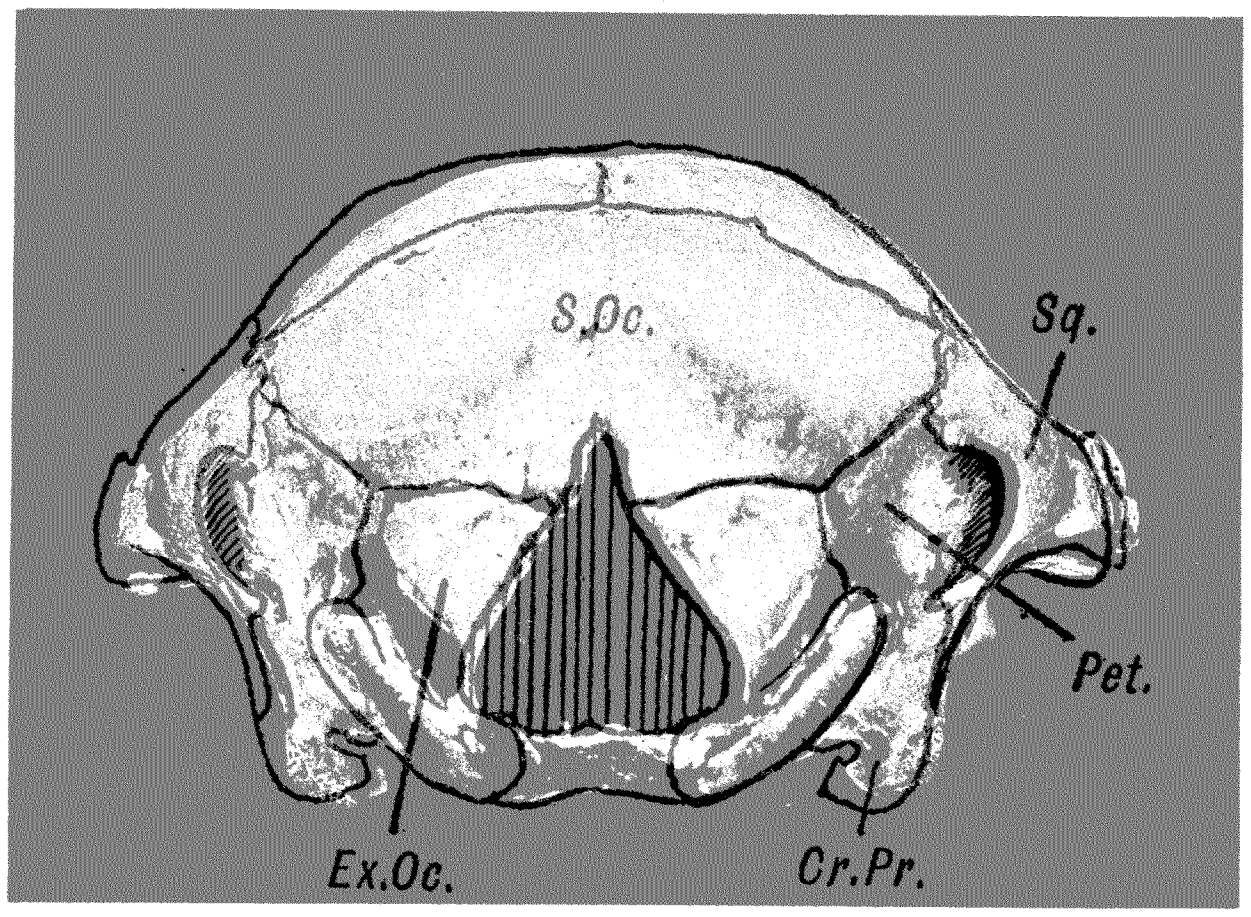

5

Cambridge University Press.

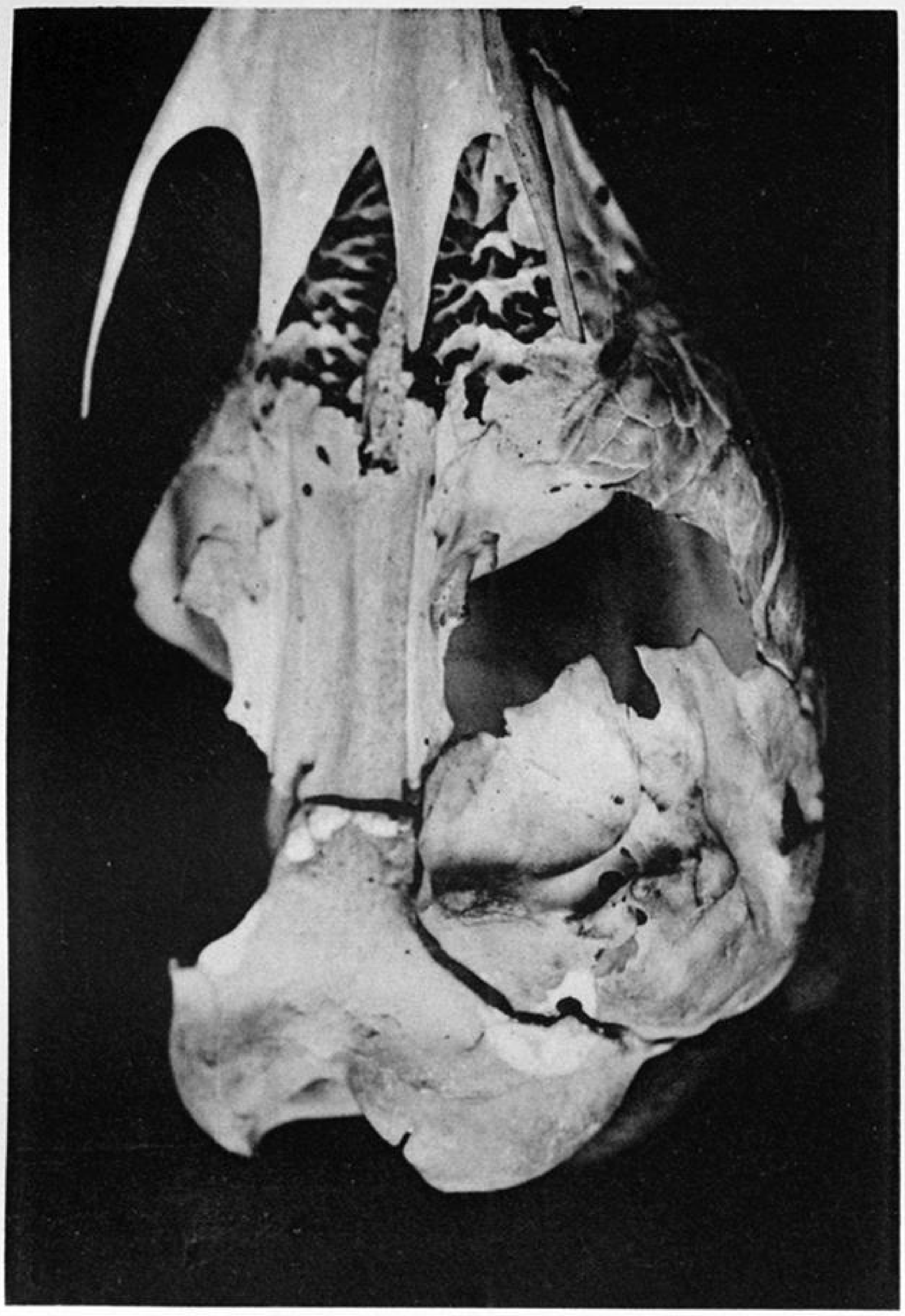

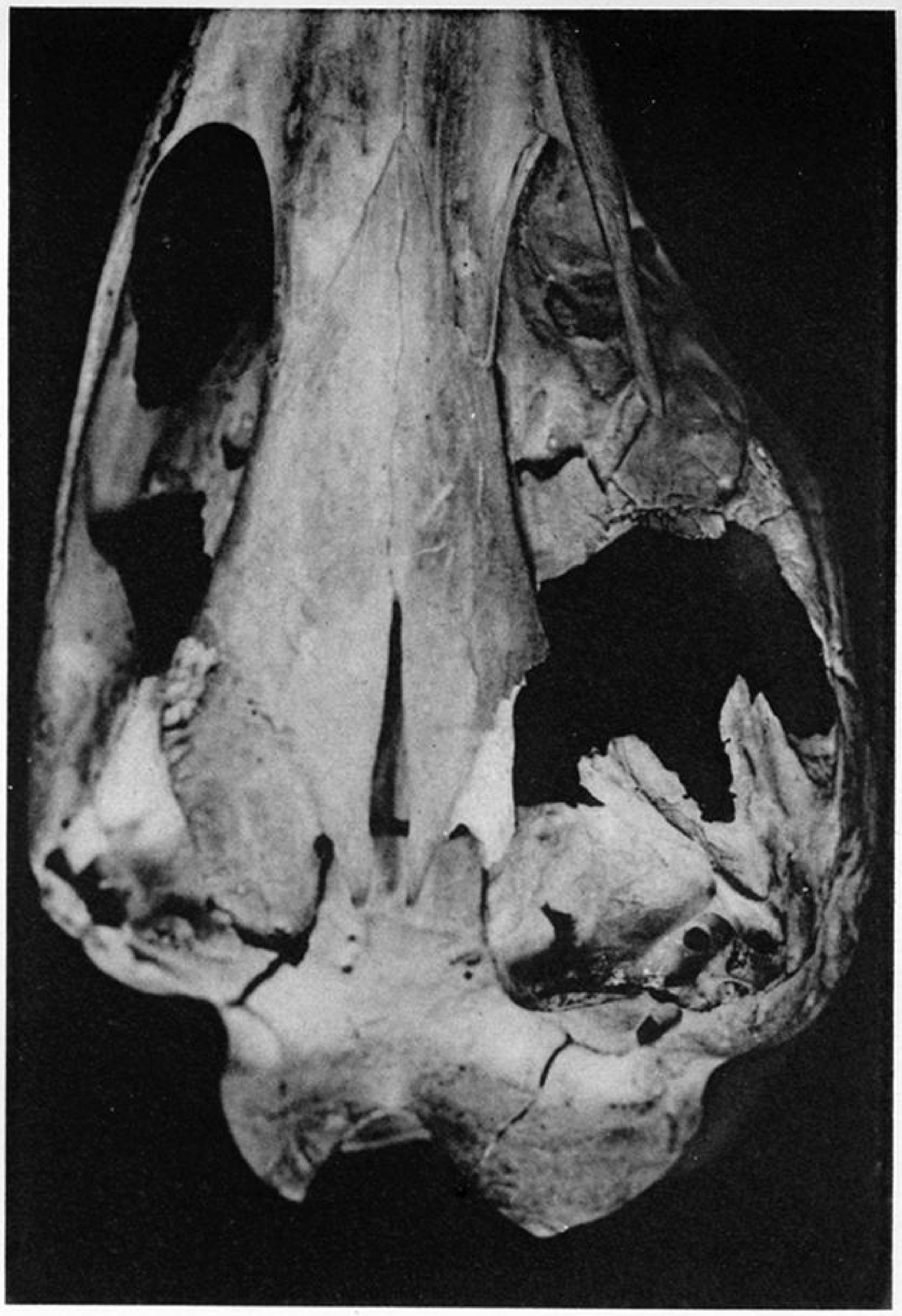

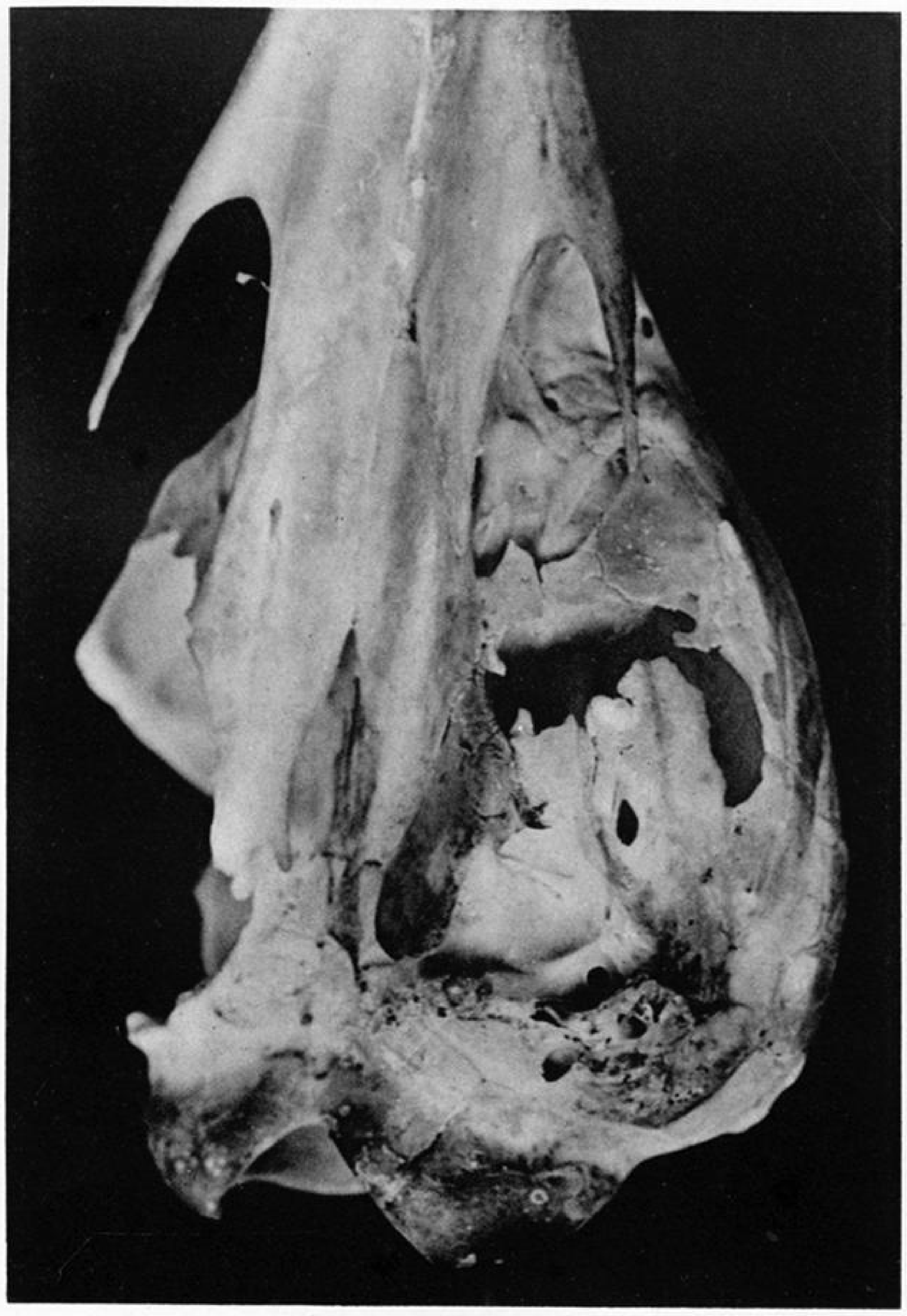

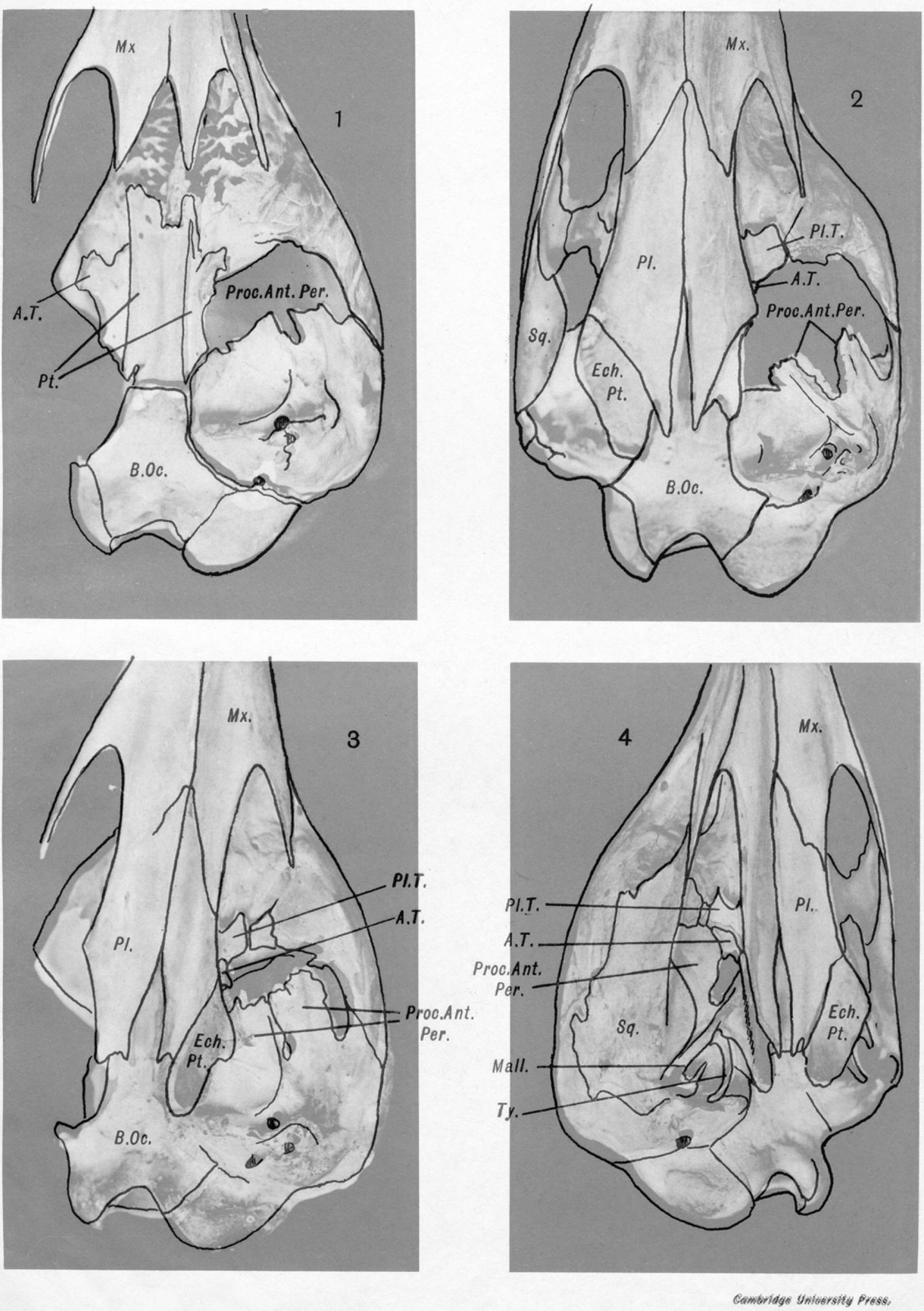

Cambridge University Press.

PLATE 23.

A series of four skulls of *Echidna aculeata*, to show the gradual growth forward of two processes (*Proc.Ant.Per.*) from the periotic in the membrana spheno-obturatoria which finally (in fig. 4) meet the ala temporalis and the temporal wing of the palatine to close the sphenoparietal fissure.

Fig. 1.—S. 1154, Australian Museum. *A.T.*, ala temporalis; *B.Oc.*, basioccipital; *Mx.*, maxilla; *Proc.Ant.Per.*, the processes of the periotic which ossify in the membrana spheno-obturatoria; *Pt.*, pterygoid.

In this specimen the palatine and vomer have been removed.

Fig. 2.—S. 1196, Australian Museum. Reference letters as in fig. 1, with *Ech.Pt.*, "Echidna pterygoid"; *Pl.*, palatine; *Pl.T.*, temporal wing of the palatine; *Sq.*, squamosal.

Fig. 3.—S. 1240, Australian Museum.

Fig. 4.—Australian Museum. *Mall.*, malleus; *Ty.*, tympanic.

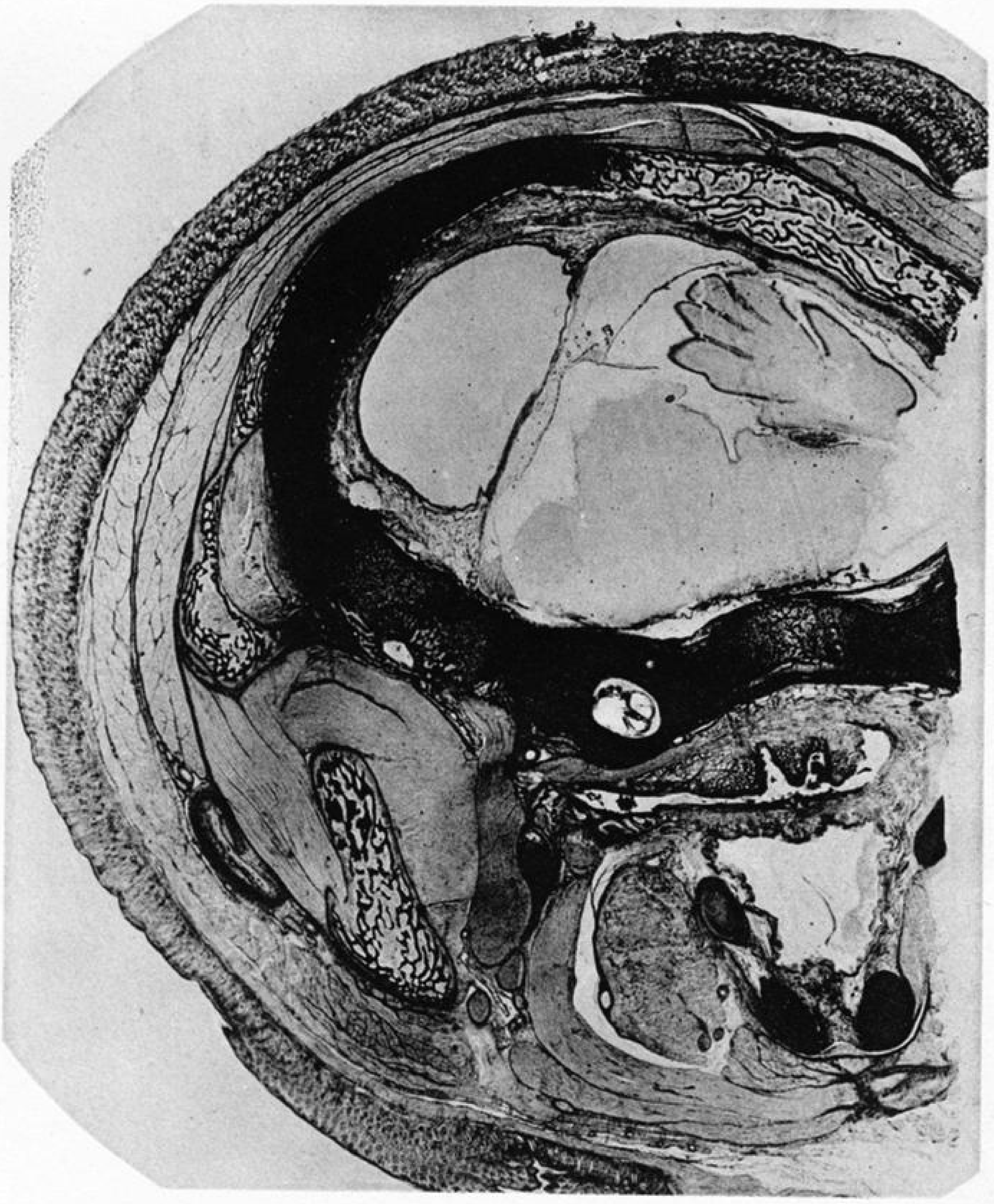

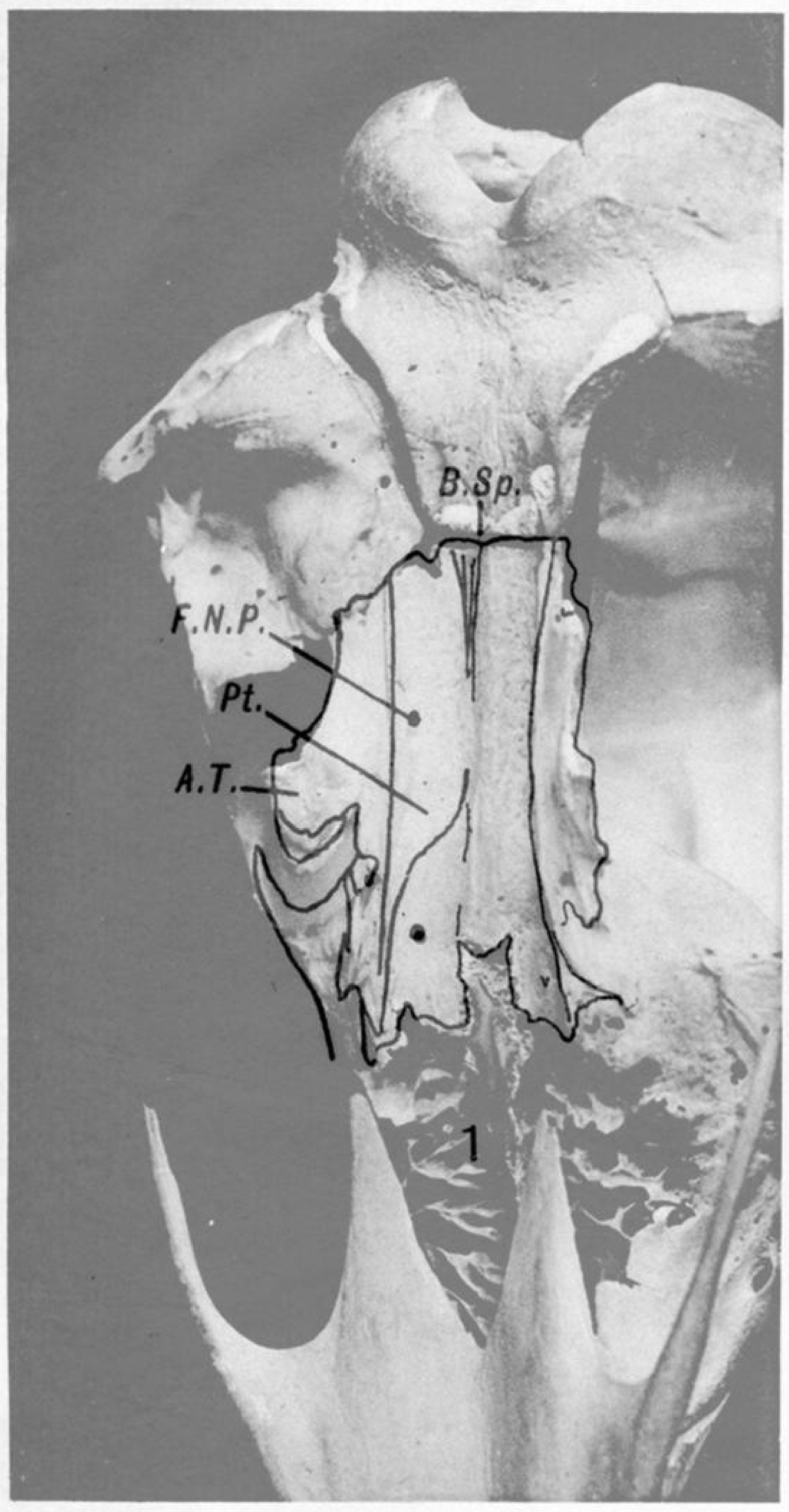

1

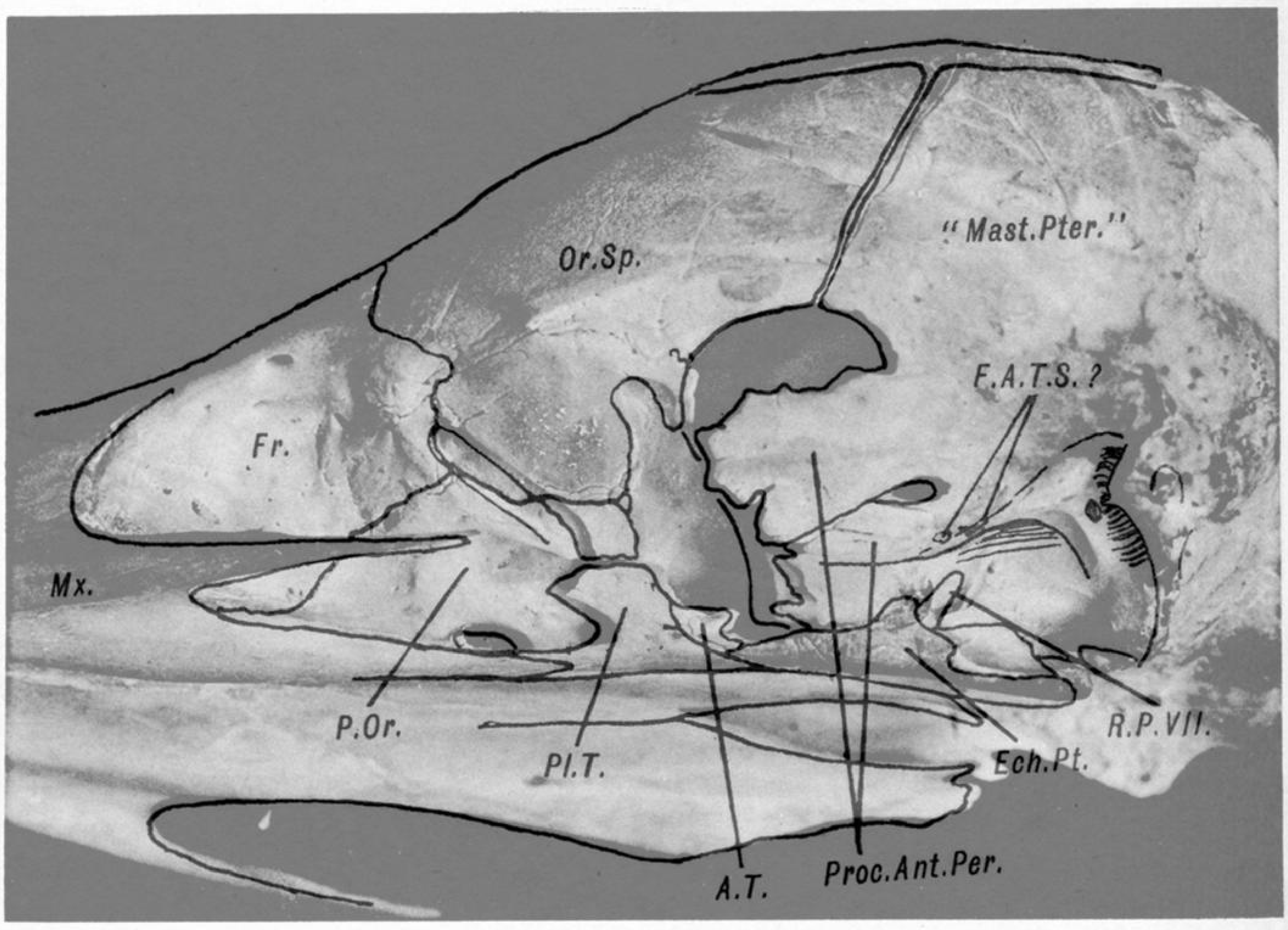

3

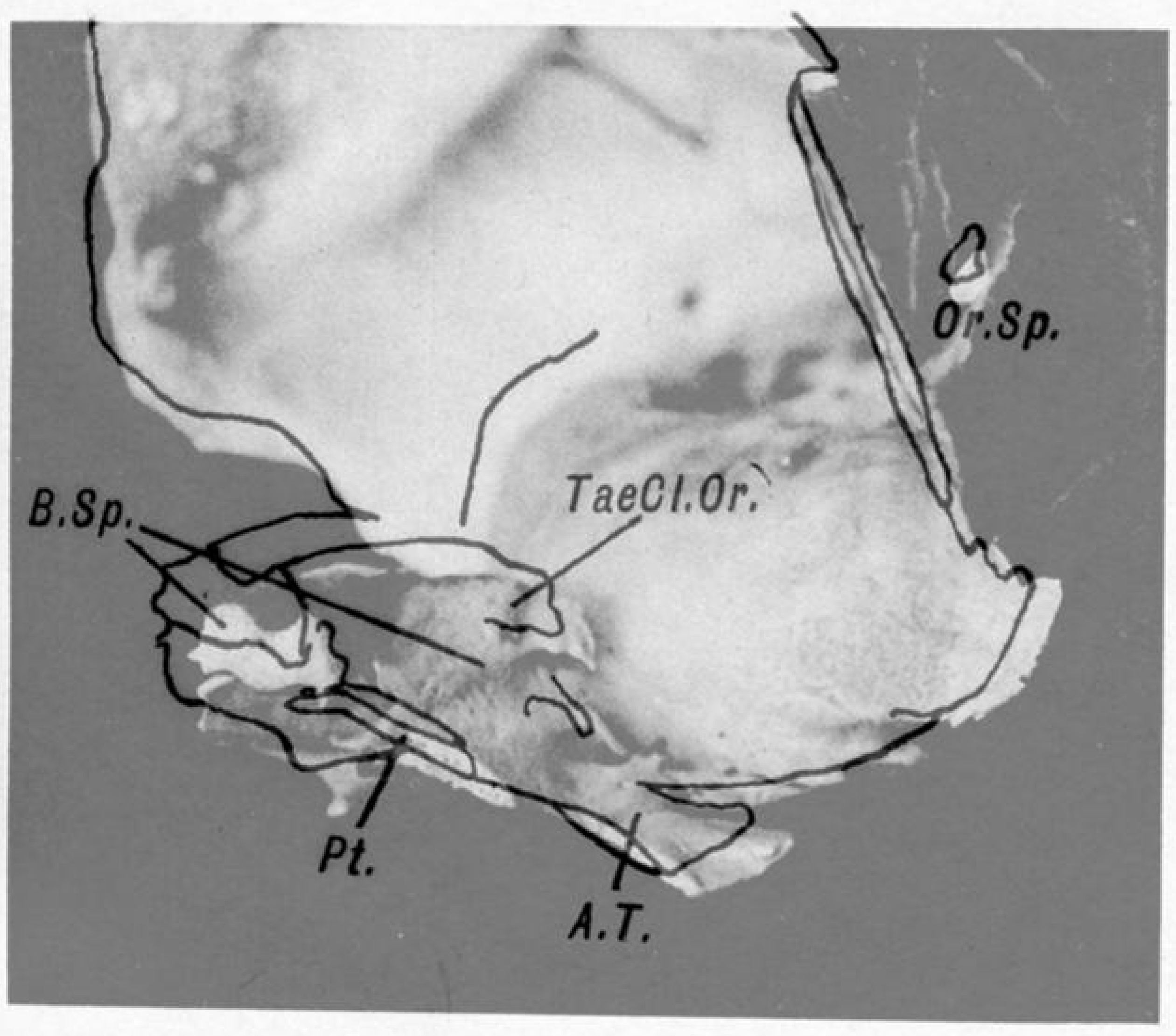

2

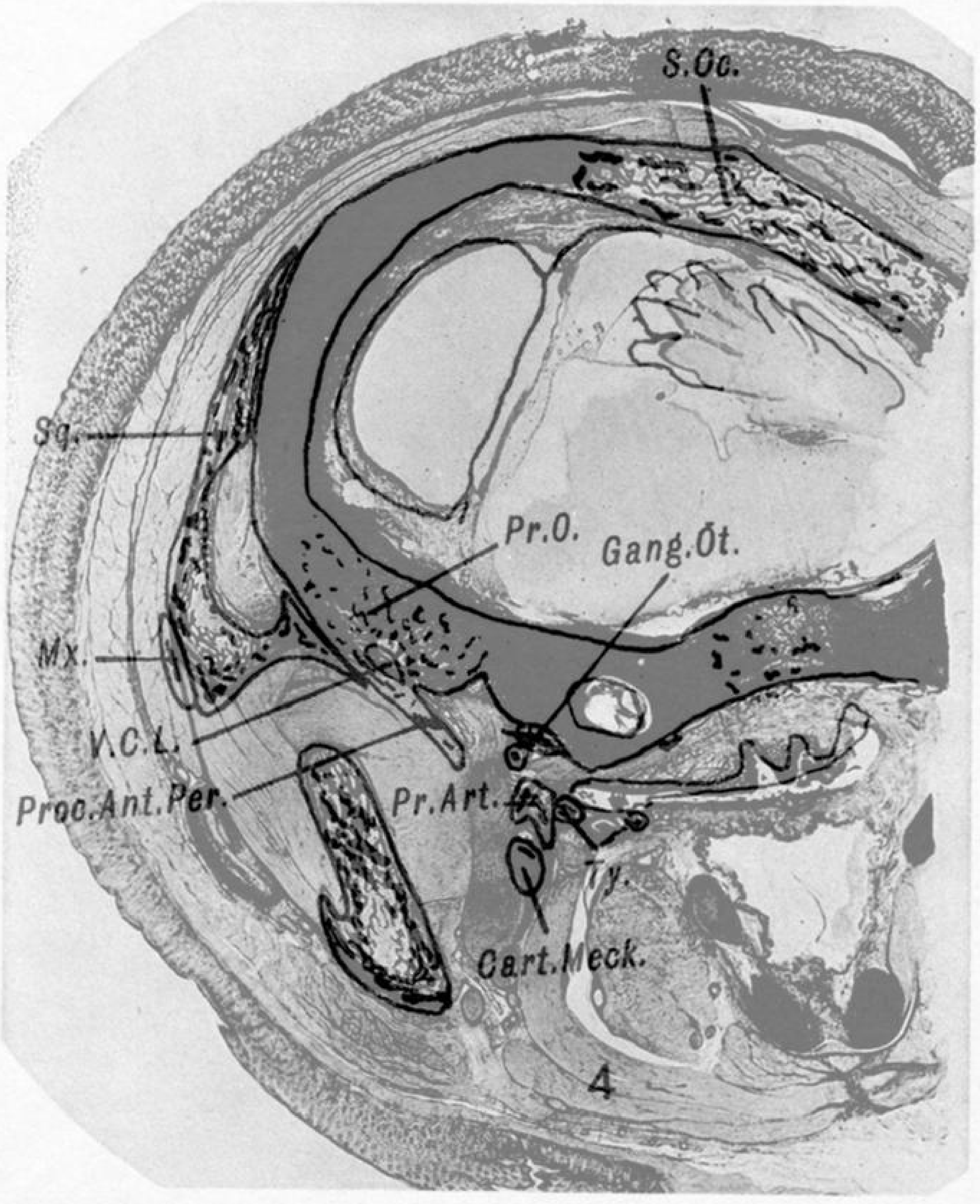

4

Cambridge University Press.

Plate 24.

Fig. 1.—Base of the skull of a young Echidna (S. 1154 of the Australian Museum) with the palatine removed. To show the clear suture between the pterygoid and the basisphenoid anteriorly and the foramen for the Vidian (parabasale) nerve, *F.N.P.*

Fig. 2.—The same specimen; to show the ala temporalis and the suture between the basisphenoid and the pterygoid posteriorly.

Fig. 3.—The orbitotemporal region of a skull of Echidna (S. 1240, Australian Museum) with the squamosal removed. *F.A.T.S.*, two foramina, presumably for the superficial temporal artery; *R.P.VII.*, groove and foramen for the great superficial petrosal nerve; "*Mast.Pter.*," pterotic process of the mastoid (van Bemmelen); *Or.Sp.*, orbitosphenoid (so-called postfrontal).

Fig. 4.—*Ornithorhynchus anatinus.* Embryo β, section 169, slide B 39, row 2, sec. 3. *Gang.Ot.*, otic ganglion with the great superficial petrosal nerve running through it; *Cart.Meck.*, Meckel's cartilage; *Pr.Art.*, prearticular (Goniale, Gaupp); *Pr.O.*, prootic ossification in the otic capsule (notice its complete continuity with the processus anterior periotica, the membrane ossification in the membrana spheno-obturatoria); *V.C.L.*, vena capitis lateralis.

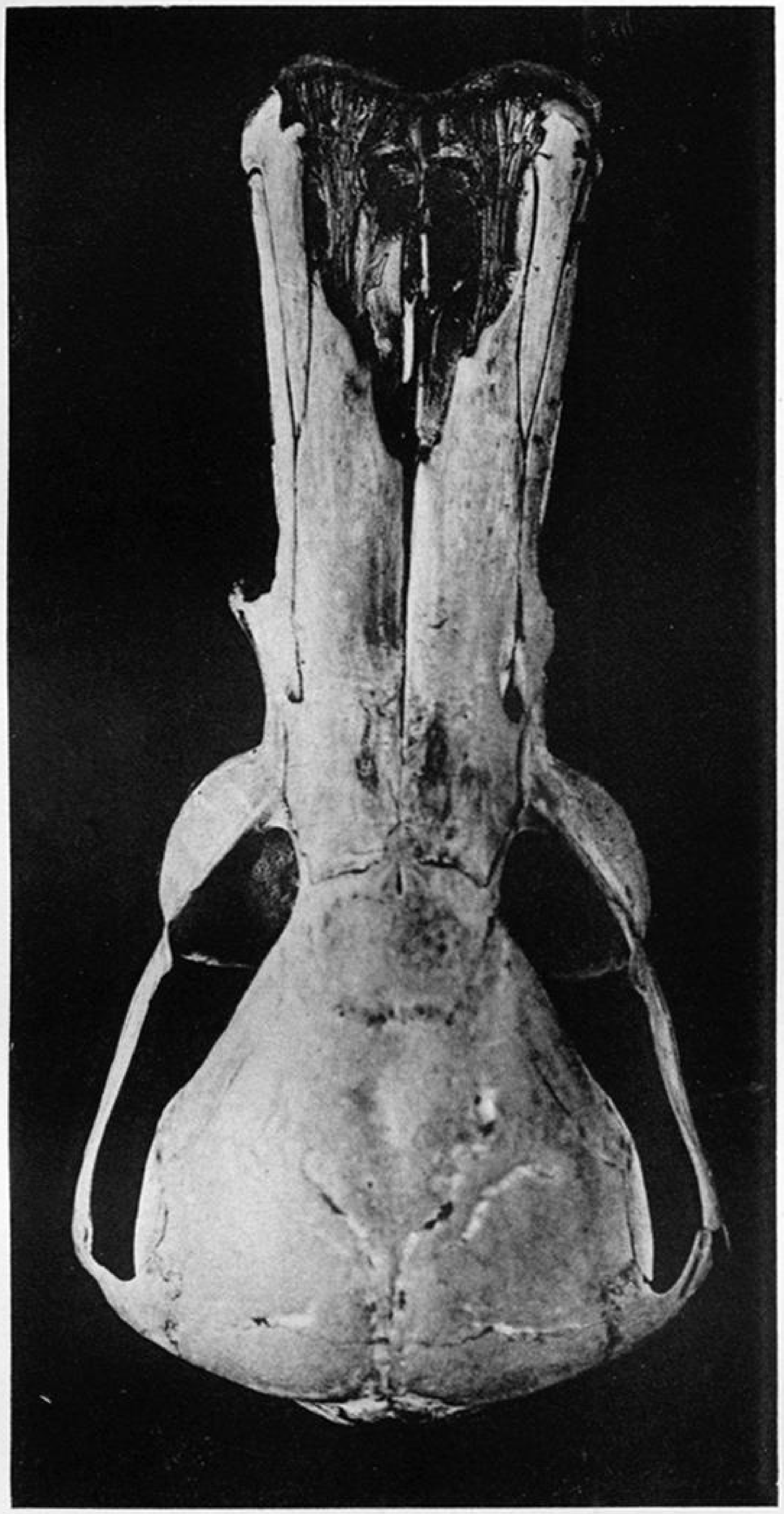

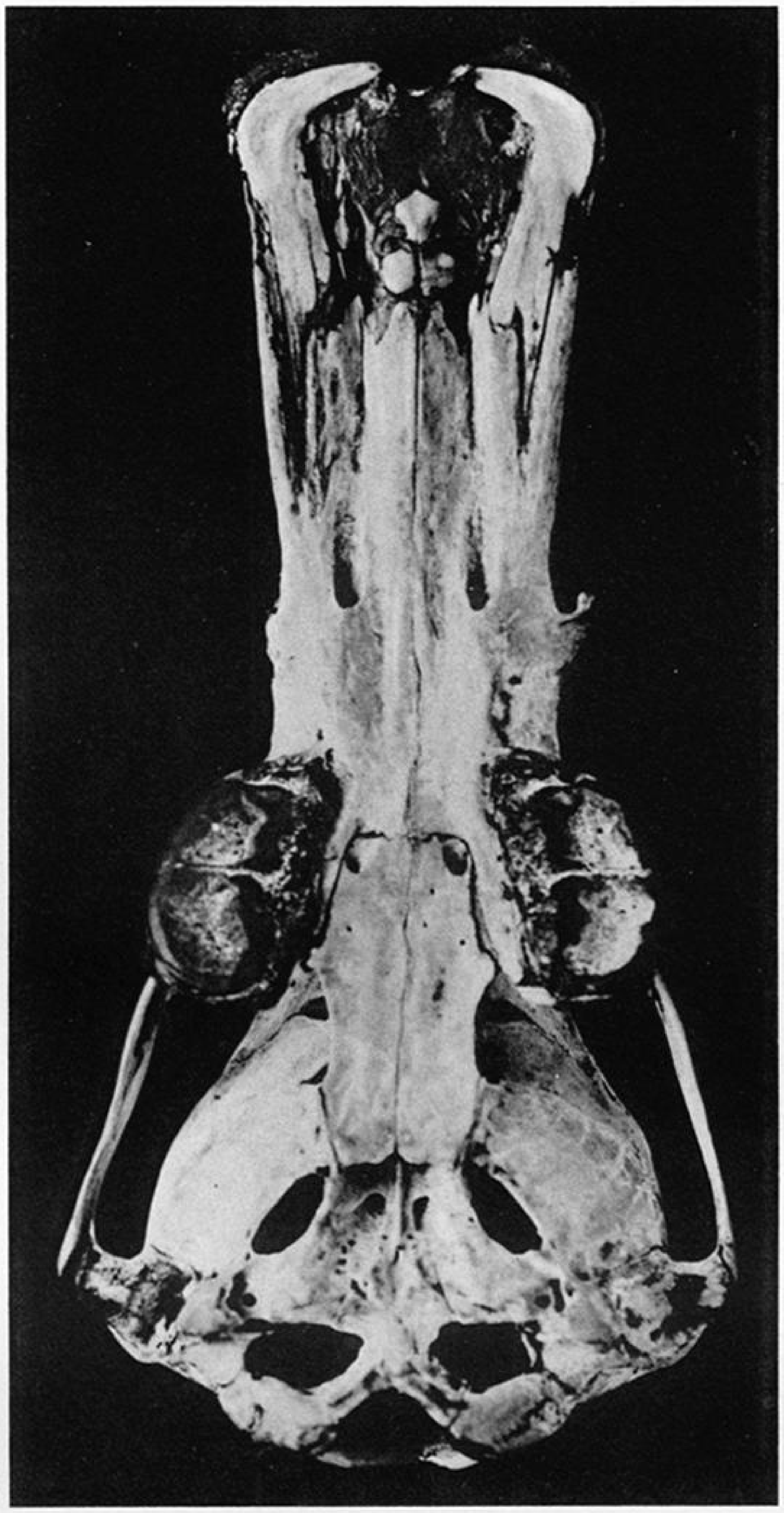

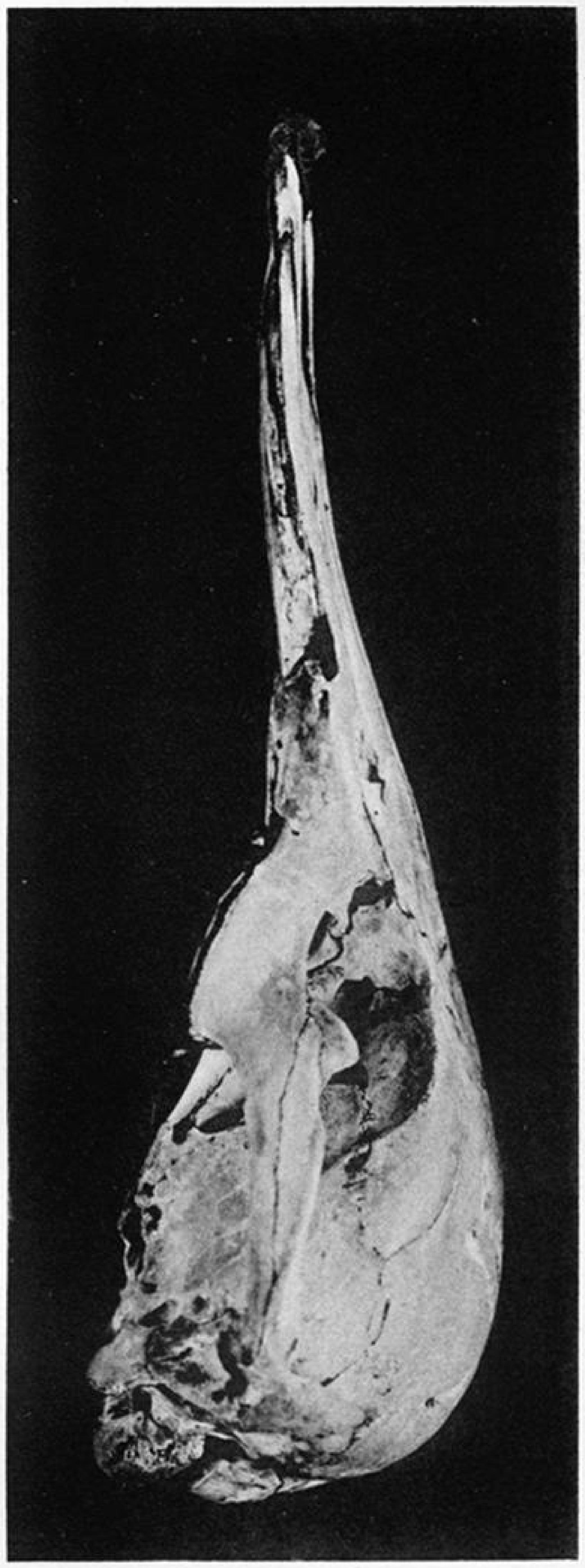

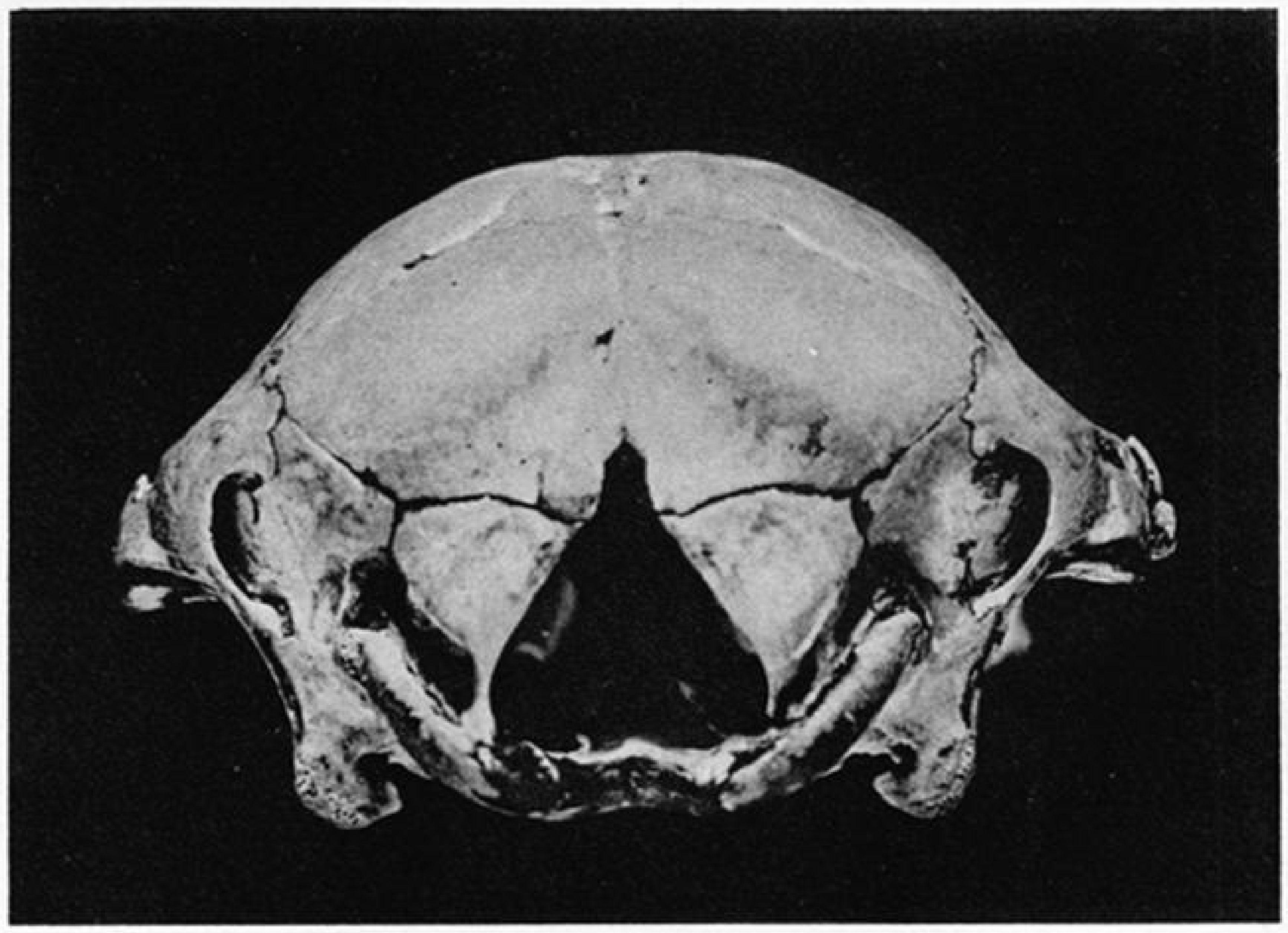

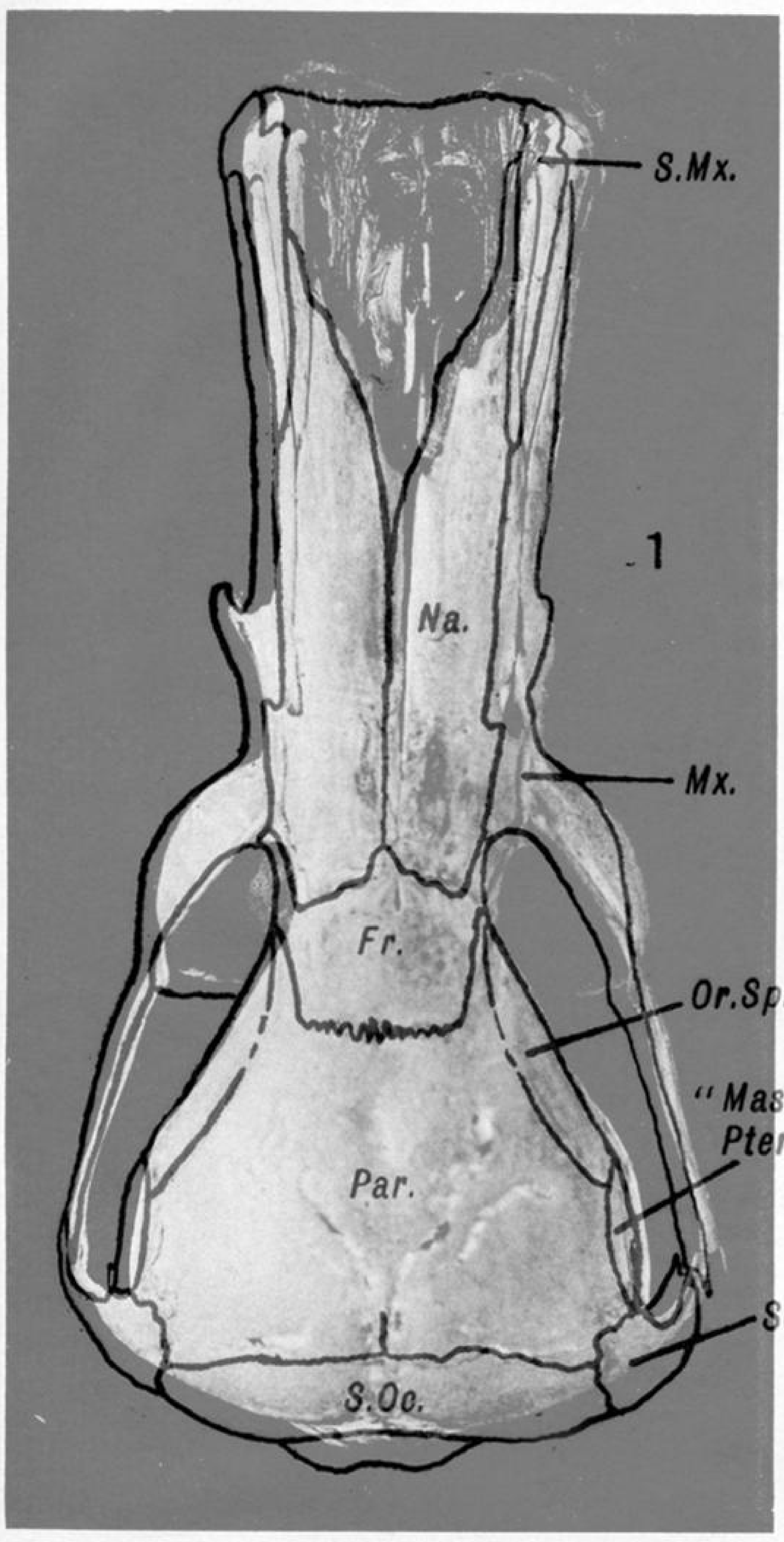

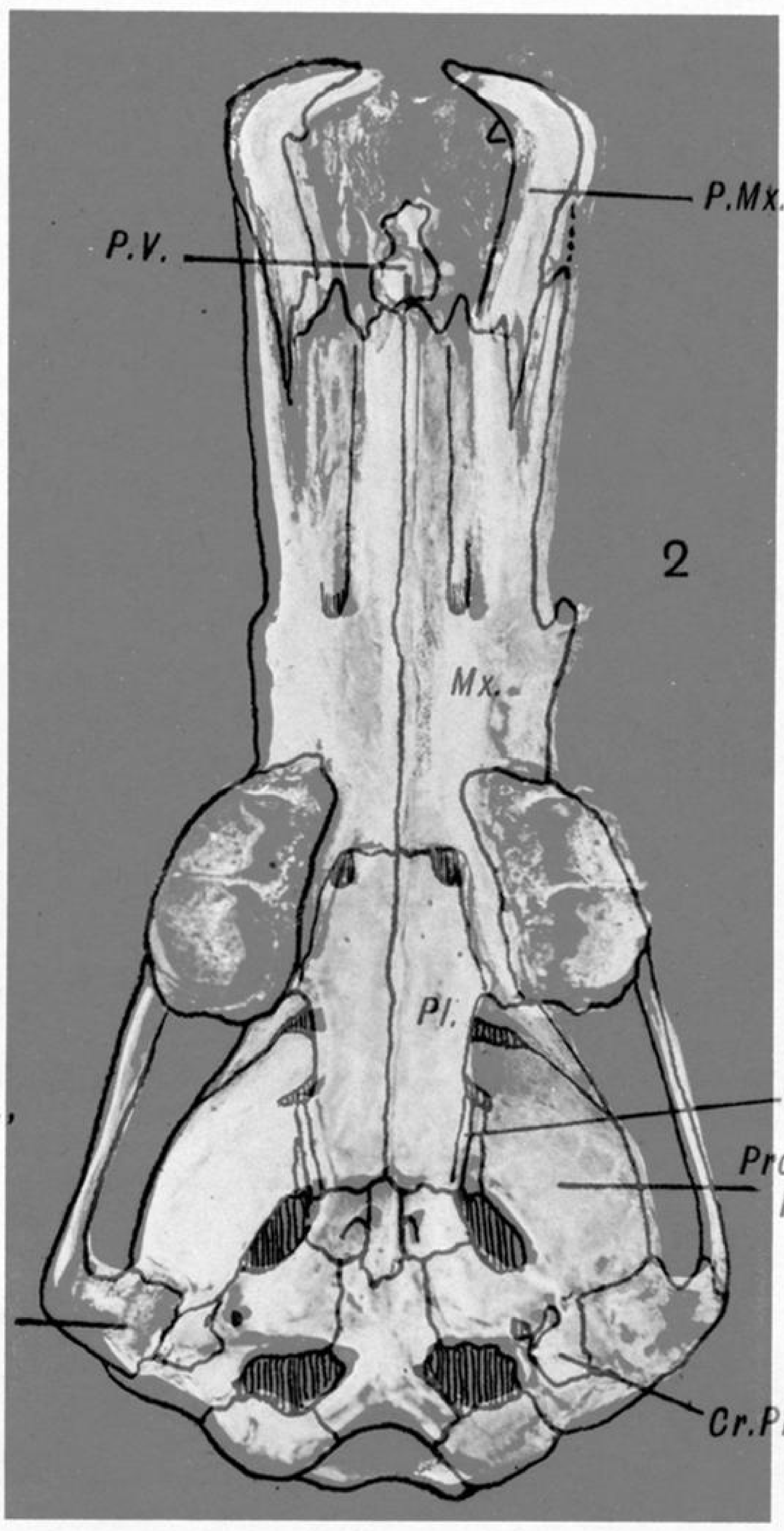

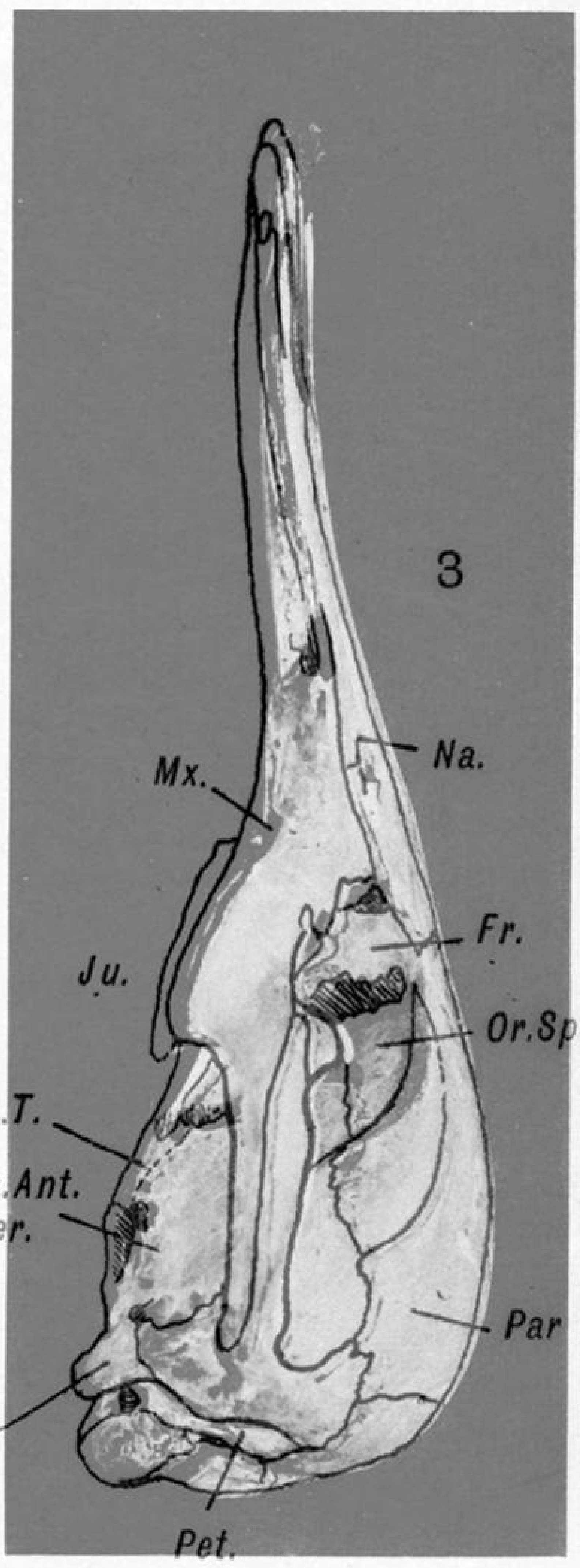

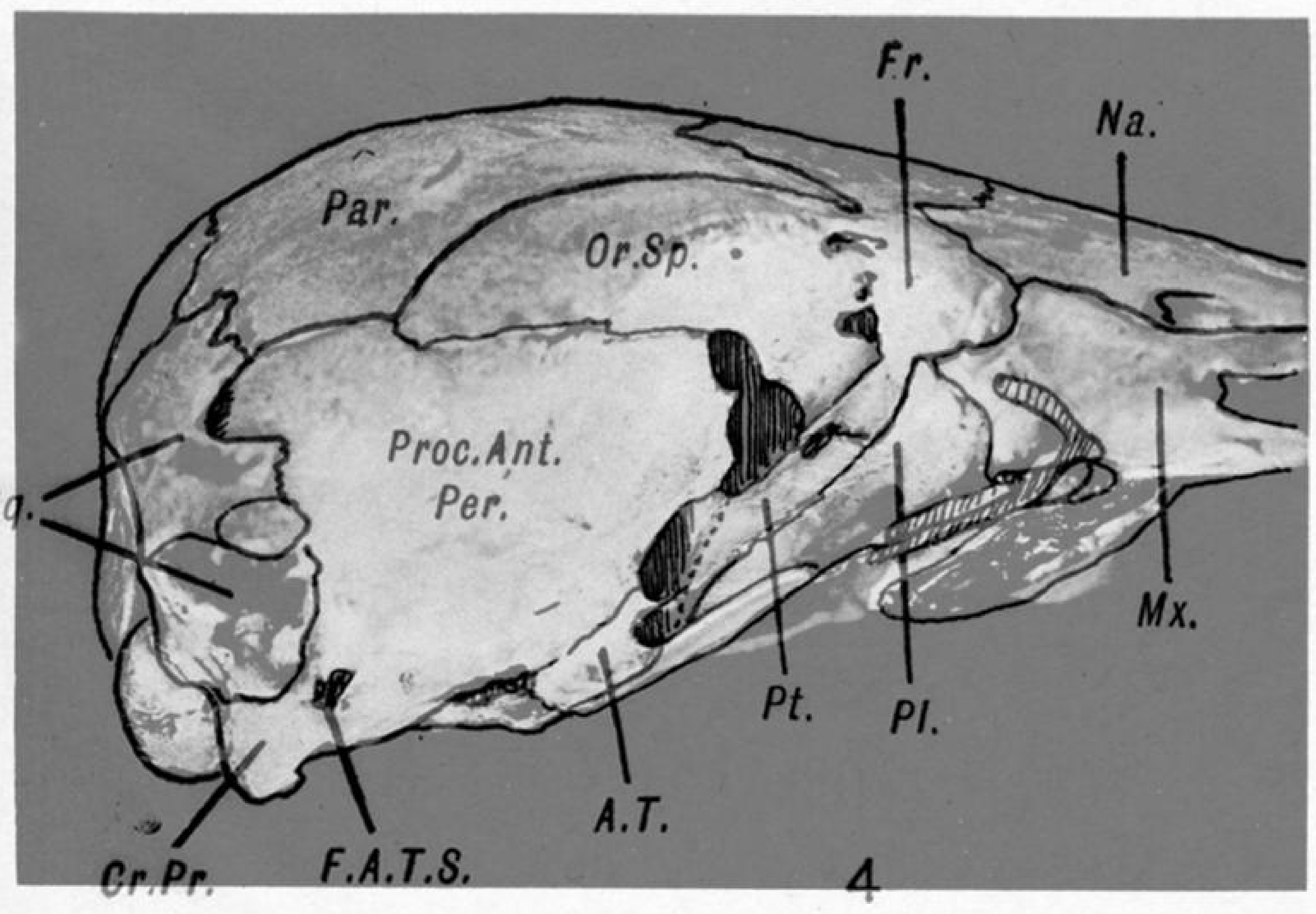

4

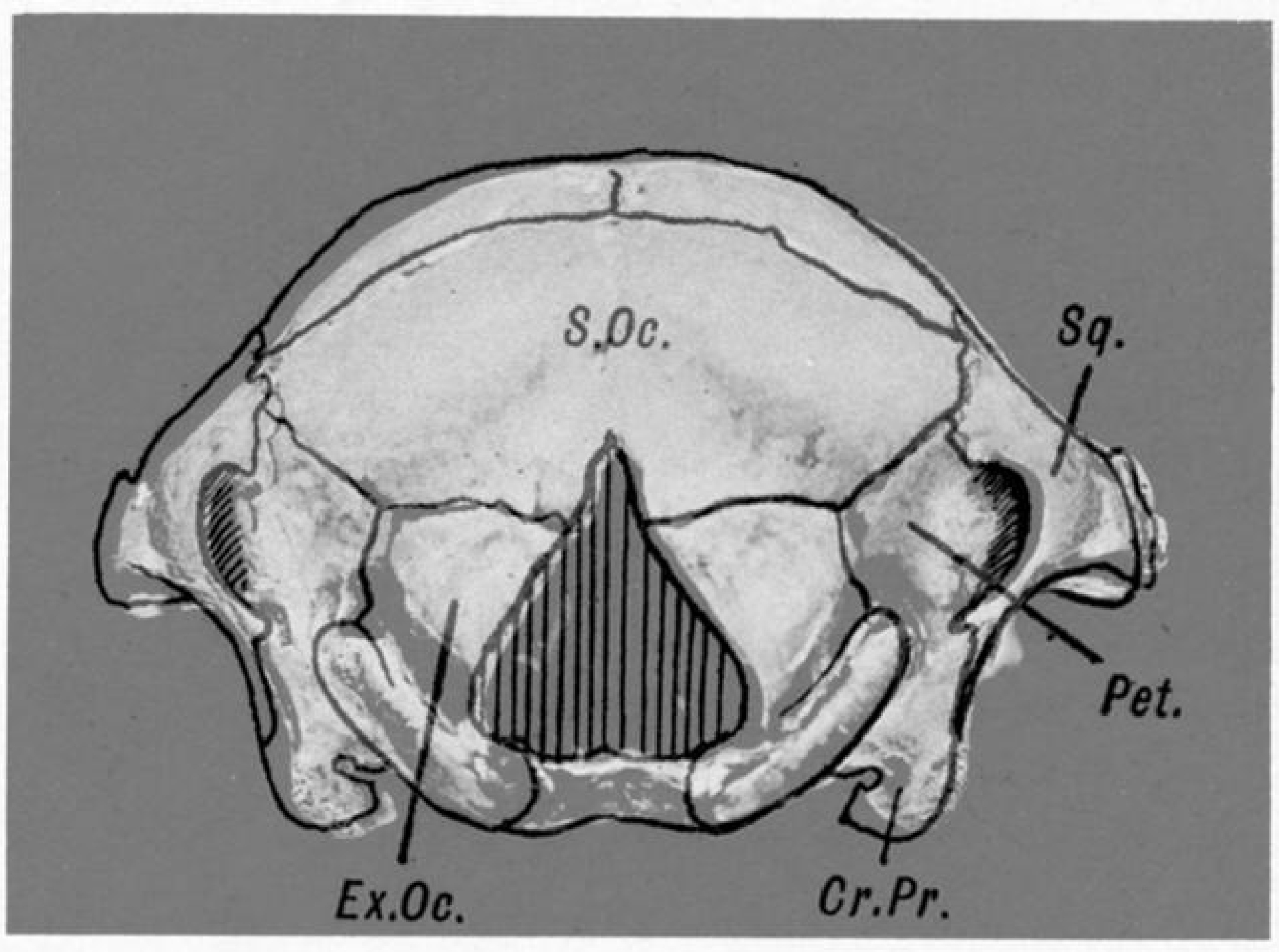

5

Cambridge University Press.

PLATE 25.

A series of photographs of a skull of Ornithorhynchus in the Zoological Department of Sydney University.

Fig. 1.—Dorsal aspect. × 1½ approx. *Fr.*, frontal; *Mx.*, maxilla; "*Mast.Pter,*" pterotic wing of mastoid (VAN BEMMELEN): *Na.*, nasal; *Or.Sp.*, orbitosphenoid; *Par.*, parietal; *S.Mx.*, septomaxillary; *S.Oc.*, supraoccipital; *Sq.*, squamosal.

Fig. 2.—Ventral aspect. *A.T.*, ala temporalis (notice especially that it appears on the ventral surface and has a clear suture with the palatine); *Cr.Pr.*, crista parotica (paroccipital process); *P.V.*, prevomer, dumb-bell-shaped bone, os paradoxum; *Pl.*, palatine; *Proc.Ant.Per.*, processus anterior periotici, the portion of the periotic ossified in the membrana sphenoobturatoria.

Fig. 3.—Lateral aspect. *Ju.*, jugal; *Pet.*, the "mastoid" portion of the petrosal.

Fig. 4.—The orbitotemporal region viewed laterally with the zygomatic arch removed. *F.A.T.S.*, foramen for the superficial temporal artery (VAN BEMMELEN, foramen vascularem medium); *Pt.*, pterygoid (the fine dotted line indicates the apparent position of the posterior part of the suture between it and the basisphenoid, but on the specimen this suture is too faint for certainty).

Fig. 5.—Posterior aspect. × 2 approx.